

# Diagnóstico intraoperatorio de los tumores del SN

Emilio Salinero

HGU Gregorio Marañón

Madrid

# Visión ideal del patólogo

- Diagnóstico intraoperatorio fino muy similar al definitivo tras estudio histológico.
- Tipificación del tumor con sus matices.
- Conocimiento detallado del cuadro histo/citológico de cada tipo y subtipo.
- Patrón y rasgos citológicos de cada tumor y aplicación a cada caso.

# Visión del cirujano

- Estoy en tumor o no estoy en tumor, porque macroscópicamente no está claro.
- Grupo tumoral para dirigir la cirugía.
- Cirugía a seguir: 1.- Cerrar y no hacer nada. 2.- Quitar todo el tumor. 3.- Quitar lo que pueda y el resto se trata con RTP y QT.

# Aplicación de la citología intraoperatoria

- Indicarle que está en tumor. En especial en tomas por estereotaxia.
- Definir si el tumor es primario o no.
- Definir las características del tumor que permitan su manejo quirúrgico.
- NO es imprescindible decir el tipo exacto de tumor pero SI en que grupo tumoral se halla.
- Dirigir la actividad del neurocirujano.

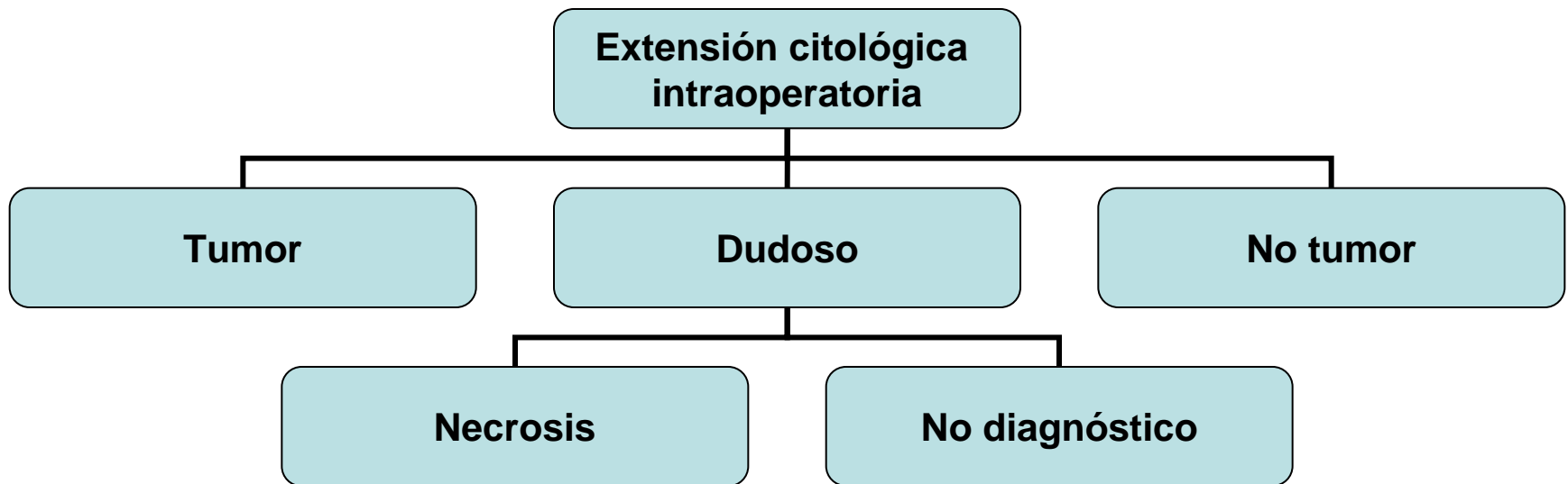
# Visión del patólogo orientada al diagnóstico intraoperatorio.

- Corte en congelación o citología??.
- Artefacto congelación, mielina. Una zona.
- Citología de varias zonas (representatividad más alta).
- Gran fiabilidad y fácil reproducción.
- Fácil realización (Diff-Quick).
- Permite valoración reglada de fondo y elementos aislados (células, vasos, etc).

<b><u>LOCALIZACIÓN SUPERFICIAL</u></b>	<b><u>ADULTO</u></b>	<b><u>NIÑO/JOVEN</u></b>
<b>CONVEXIDAD</b>	LINFOMA, XAP MENINGIOMA TUMOR MELÁNICO METÁSTASIS	LINFOMA XAP GLIOMA ANGIOCÉNTRICO
<b>BASE</b>	MENINGIOMA TUMOR HIPÓFISIS TUMOR PINEAL	CRANEOFARINGIOMA GLIOMA ÓPTICO PINEALOBLASTOMA
<b>FOSA POSTERIOR</b>	HEMANGIOBLASTOMA METÁSTASIS MENINGIOMA NEURINOMA	HEMANGIOBLASTOMA TUMOR RABDOIDE
<b><u>LOCALIZACIÓN INTRA/PERI VENTRICULAR</u></b>	TUMOR PLEXOS NEUROCIOMA QUISTE COLOIDEO SUBPENDIMOMA MENINGIOMA GLIOMA CORDOIDE GLIONEURONAL IV VENTRICULO	PAPILOMA PLEXOS NEUROCIOMA QUISTE COLOIDEO EPENDIMOMA AGS TUMOR GERMINAL

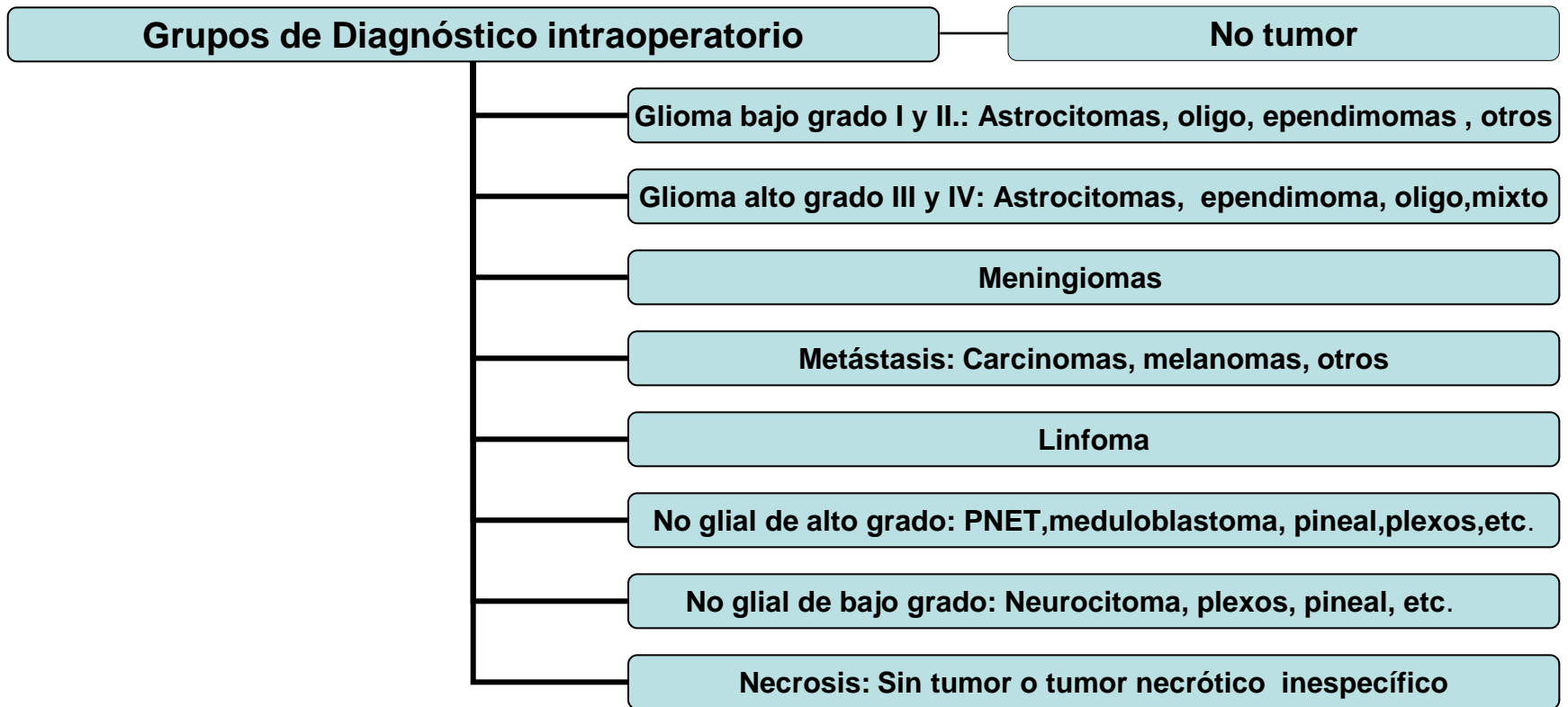
<b><u>LOCALIZACIÓN</u></b> <b><u>INTRAPARENQUIMAL</u></b>	<b><u>ADULTO</u></b>	<b><u>NIÑO/JOVEN</u></b>
<b>HEMISFERIO BORDE DIFUSO</b> <b>RADIOLÓGICO</b>	ASTROCITOMA II ASTROCITOMA III GLIOBLASTOMA OLIGODENDROGLIOMA (CORTEX) GLIOMATOSIS LINFOMAS MTX	EPENDIMOMA GLIOBLASTOMA LINFOMA/LEUCEMIA PNET/ NEUROBLASTOMA
<b>HEMISFERIO BORDE DELIMITADO</b> <b>RADIOLÓGICO</b>	ASTROCITOMA I GLIOSARCOMA GB NODULAR XAP GANGLIOGLIOMA MTX	NEUROCIOMA EPENDIMOMA TNED GGD XAP GANGLIOGLIOMA GLIOMA PILOMIXOIDE
<b>FOSA POSTERIOR</b>	EPENDIMOMA HEMANGIOBLASTOMA MTX TUMOR PLEXOS SUBEPENDIMOMA	EPENDIMOMA HEMANGIOBLASTOMA ASTROCITOMA PILOCITICO (CBELO) MEDULOBLASTOMA

# Diagnóstico citológico intraoperatorio genérico.





# Grupos diagnósticos intraoperatorios.



# Rasgos morfológicos a valorar

## Histológicos

- Celularidad elevada
- Pleomorfia nuclear
- Atipia nuclear
- Necrosis
- Vasos proliferados y atipia e hiperplasia endotelial

## Citológicos

- Celularidad elevada
- Pleomorfia nuclear
- Atipia nuclear
- Necrosis
- Vasos proliferados y anómalos en su forma y endotelio

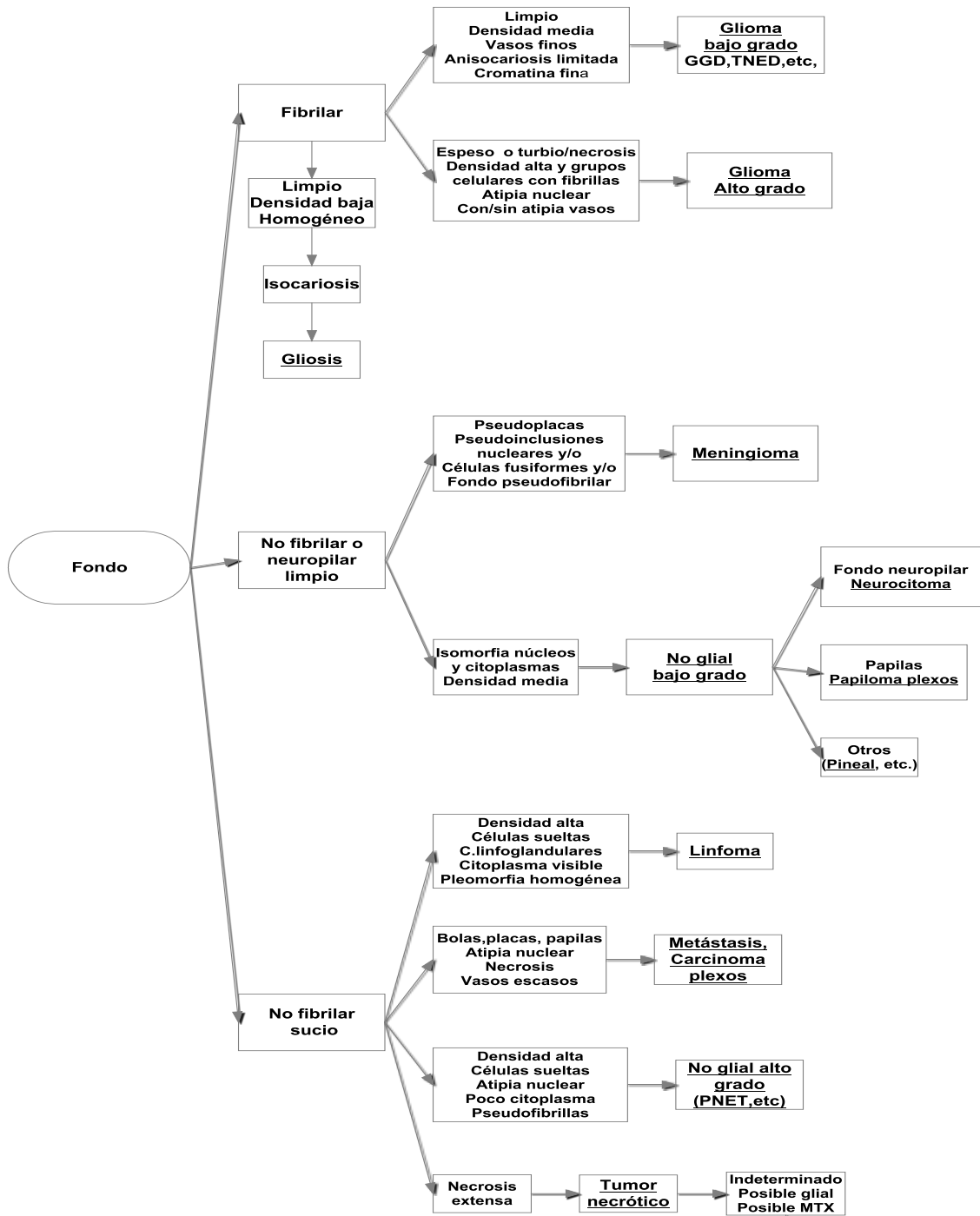
# Tabla VII. Rasgos morfológicos a valorar

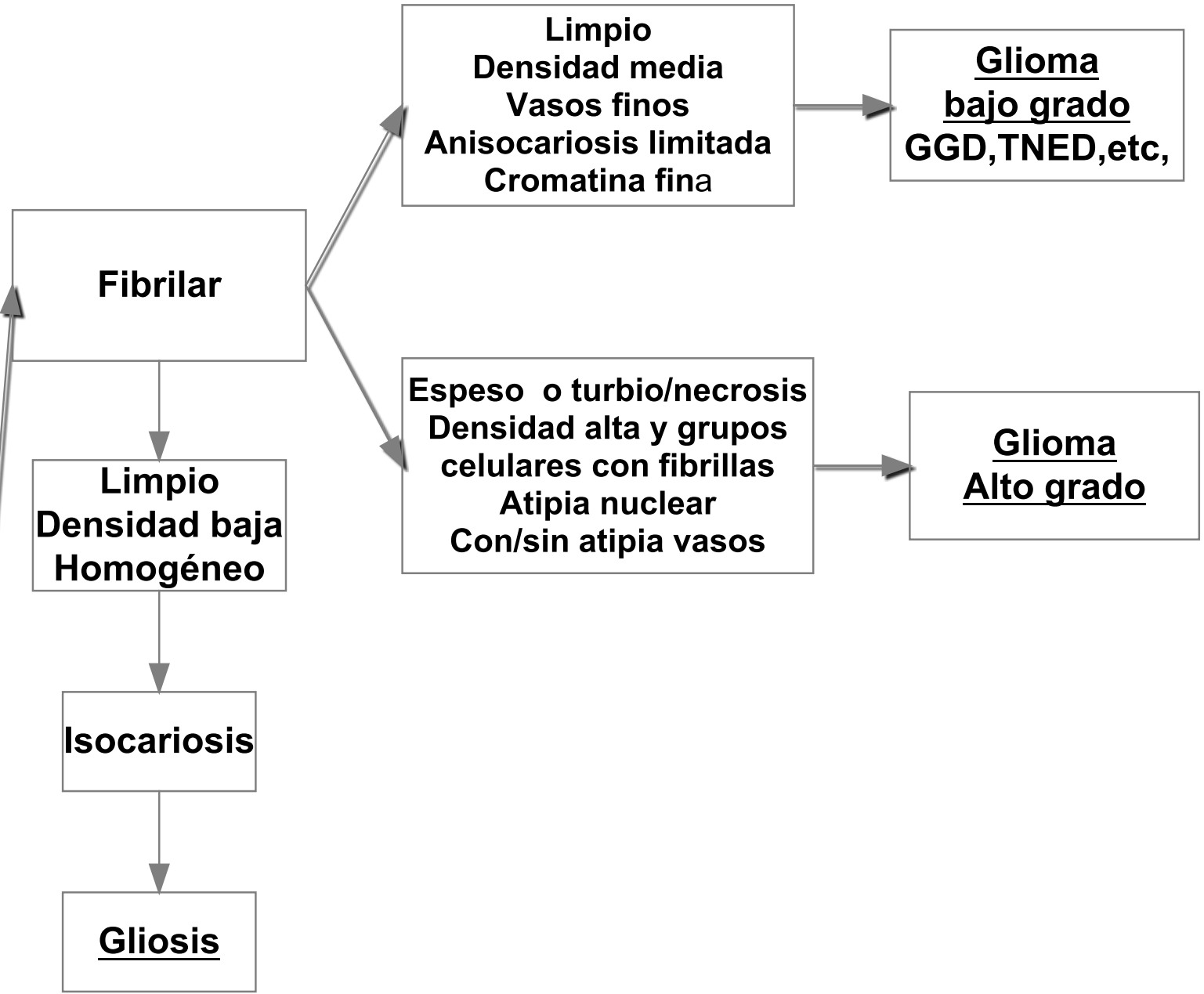
## Histológicos

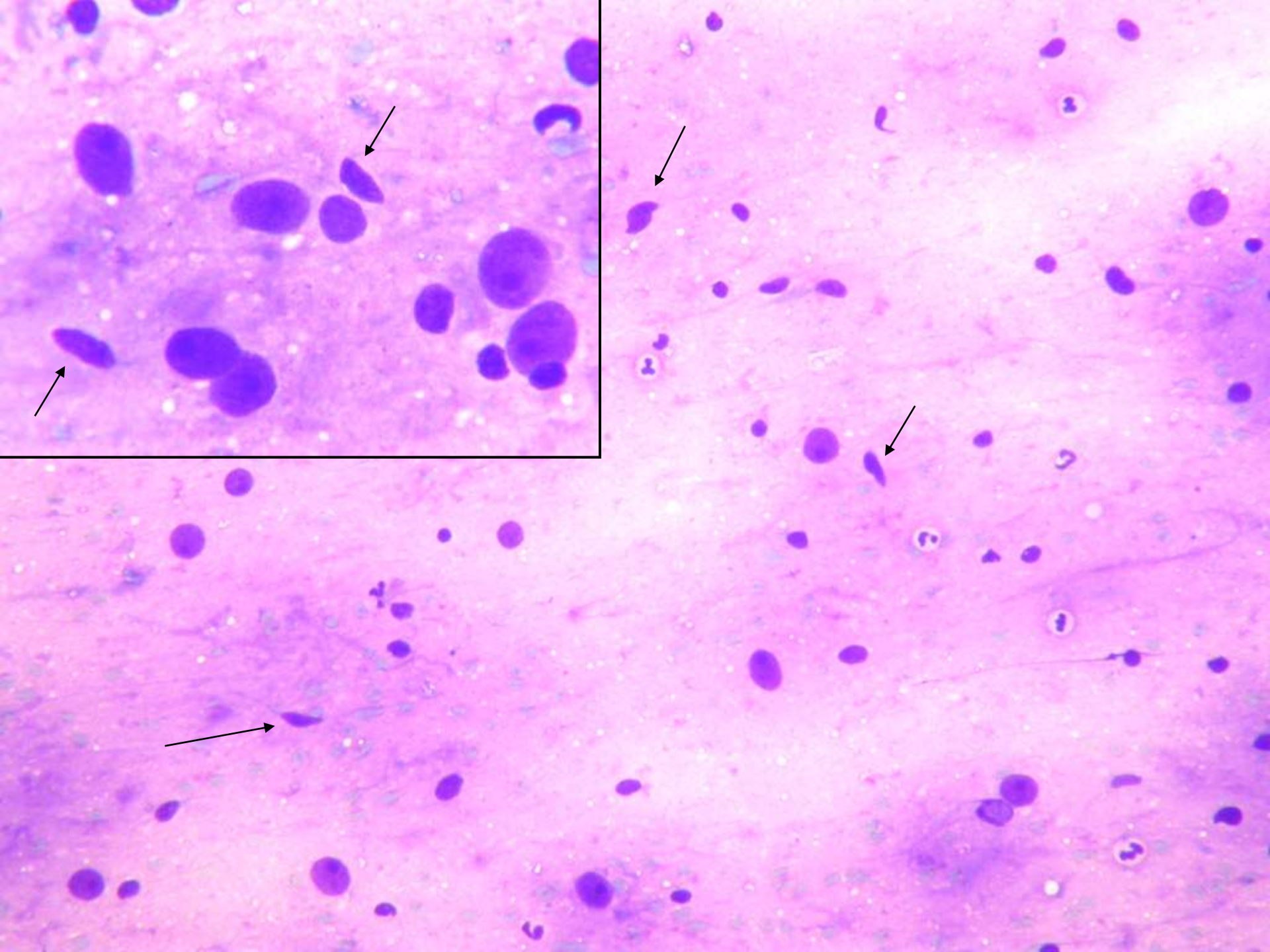
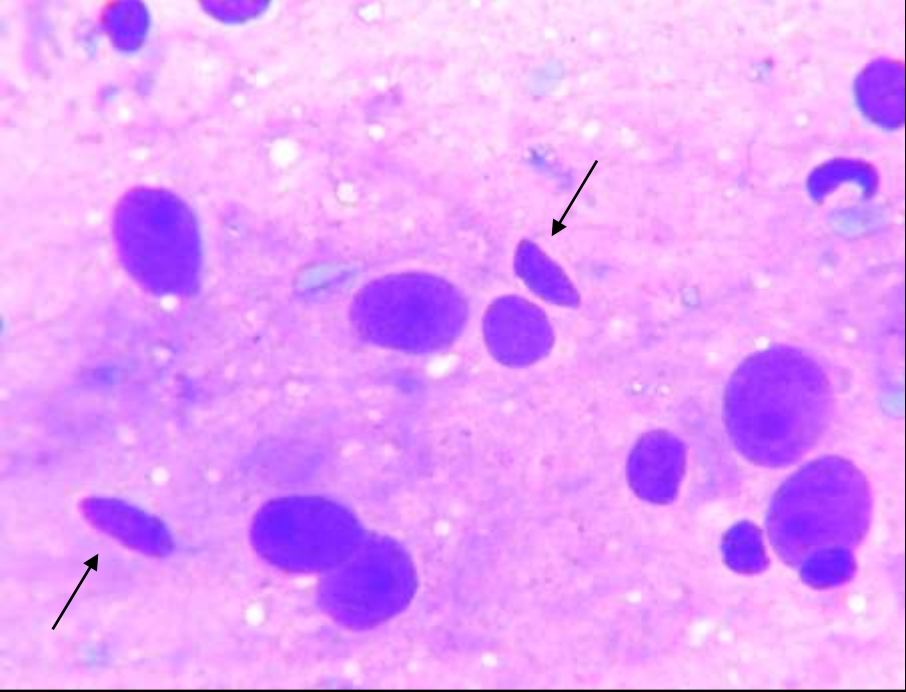
- Estructuras secundarias (ausencia de las mismas, sistemas gliovasculares, túbulos, papilas, crecimiento difuso amorfo)

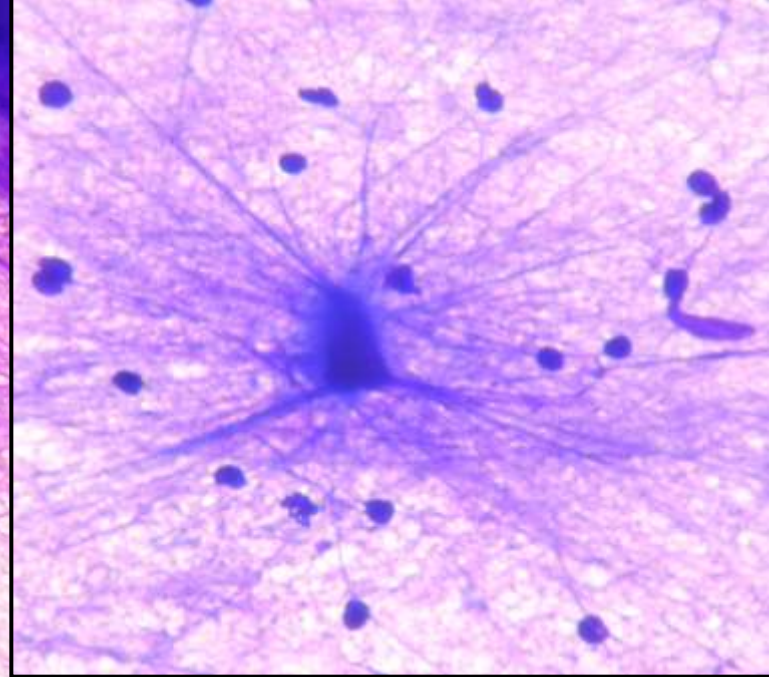
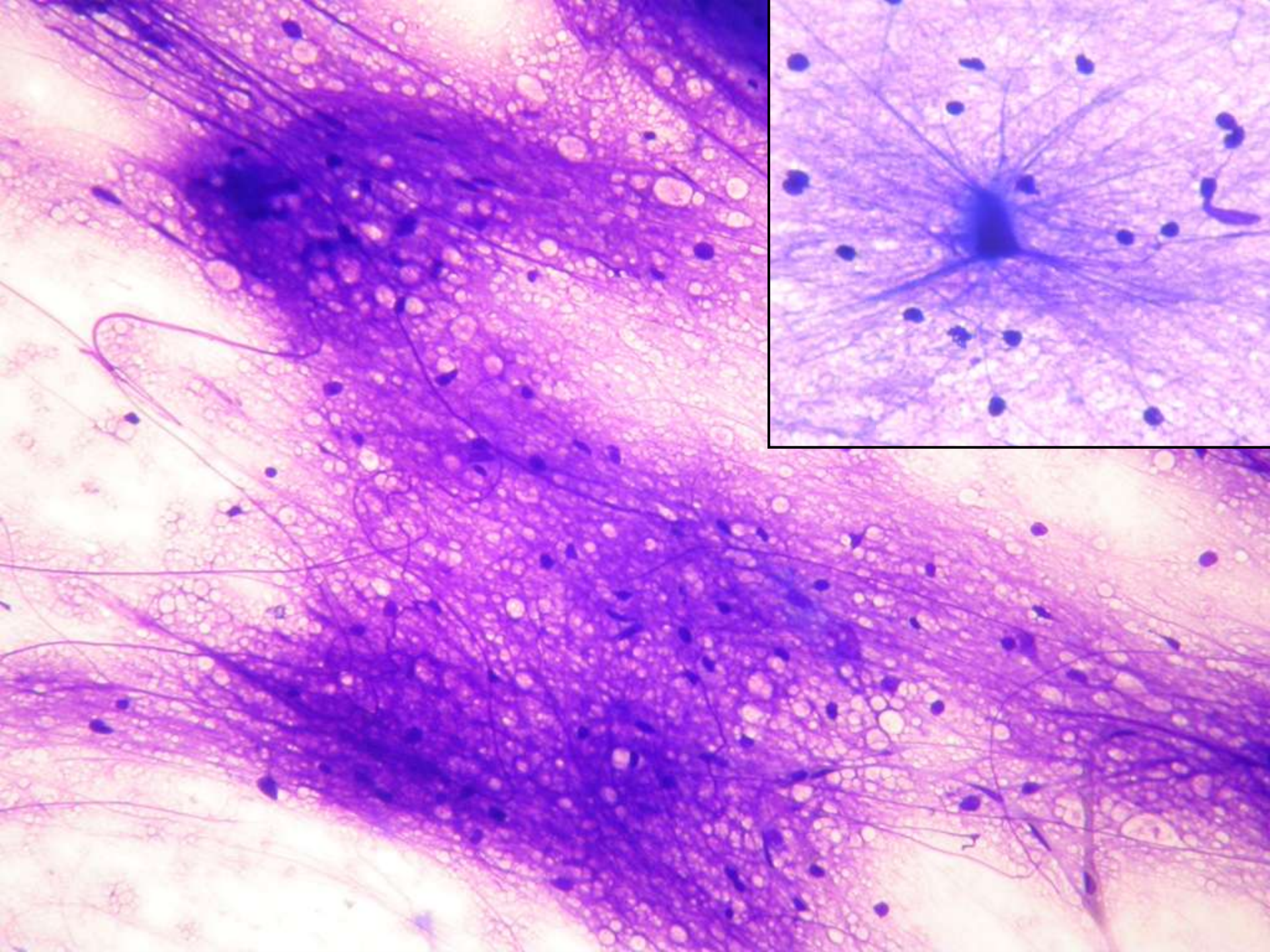
## Citológicos

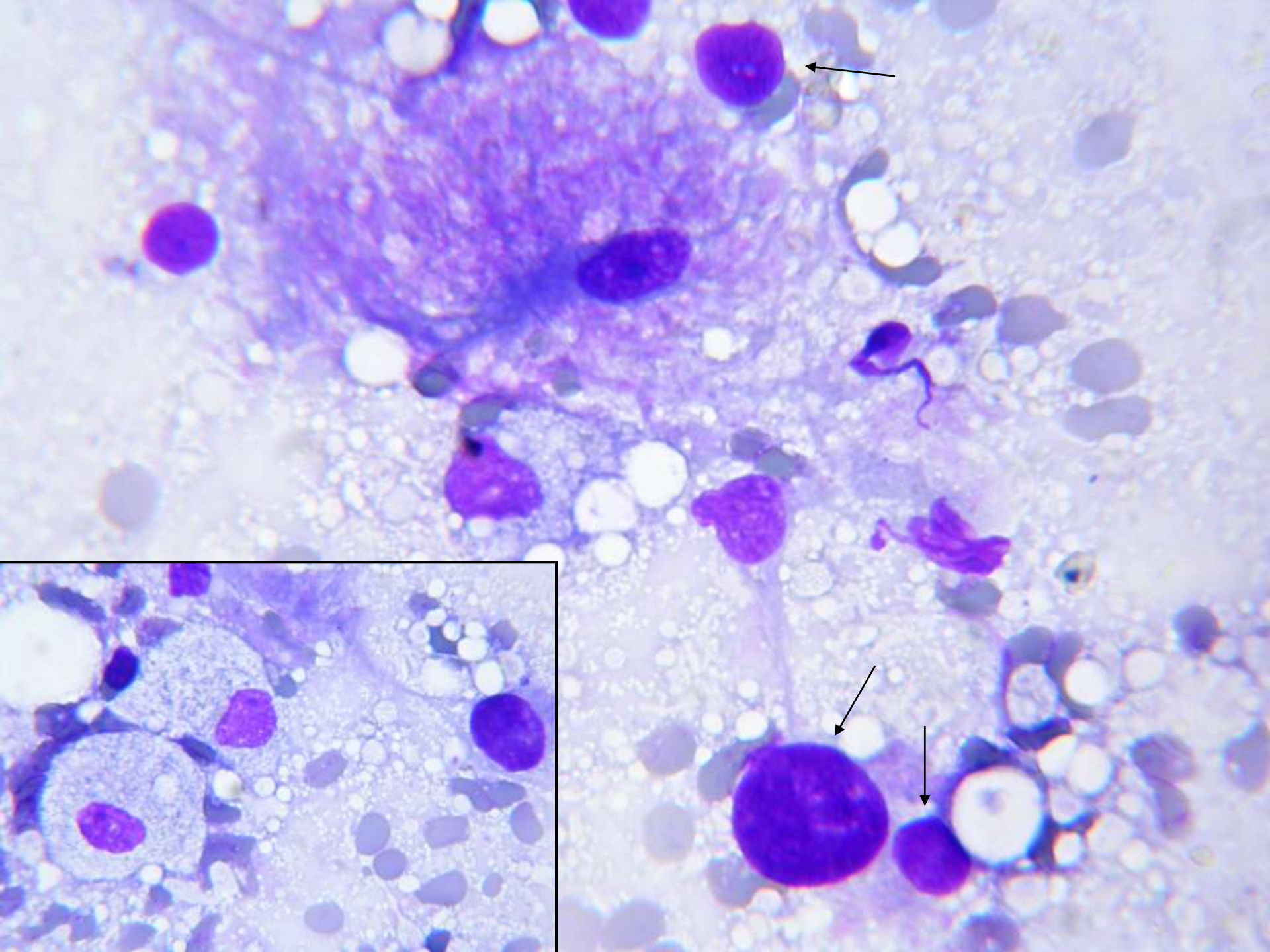
- Estructuras secundarias
- **Agrupamientos celulares** (bolas, placas, grupos celulares con puentes entre ellos, etc.)
- **Extendido uniforme o no**
- **Fondo**



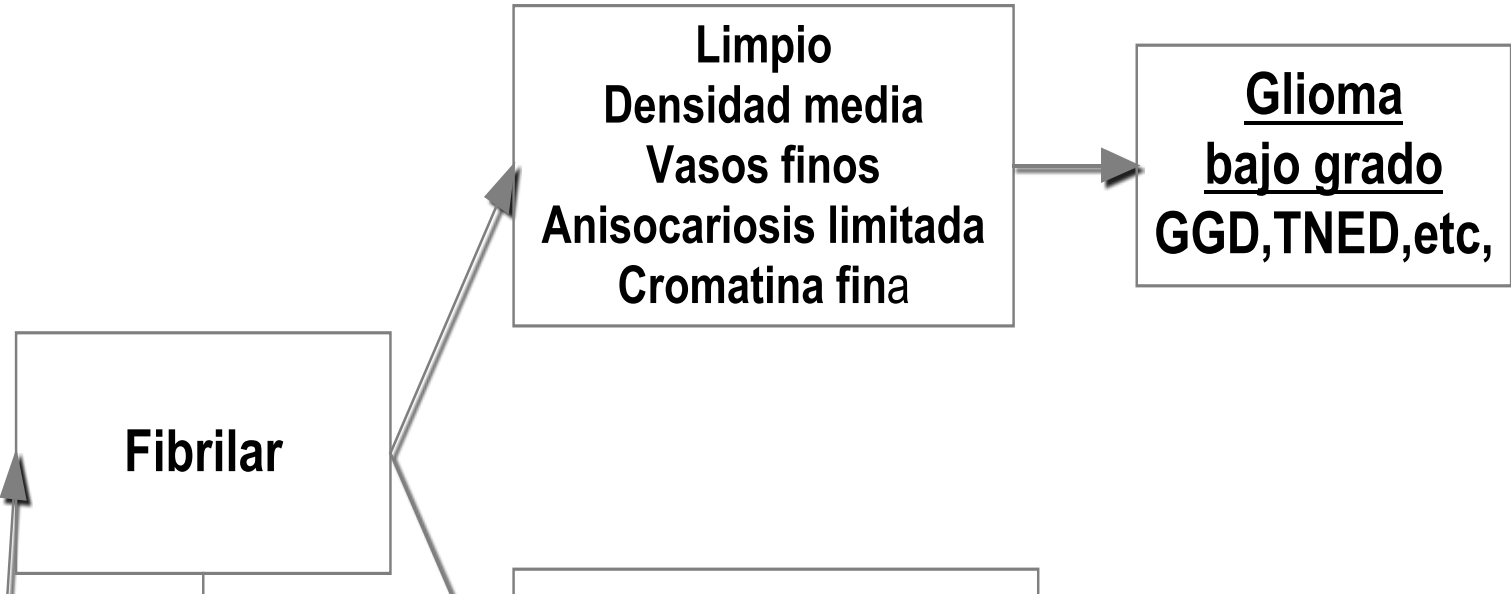


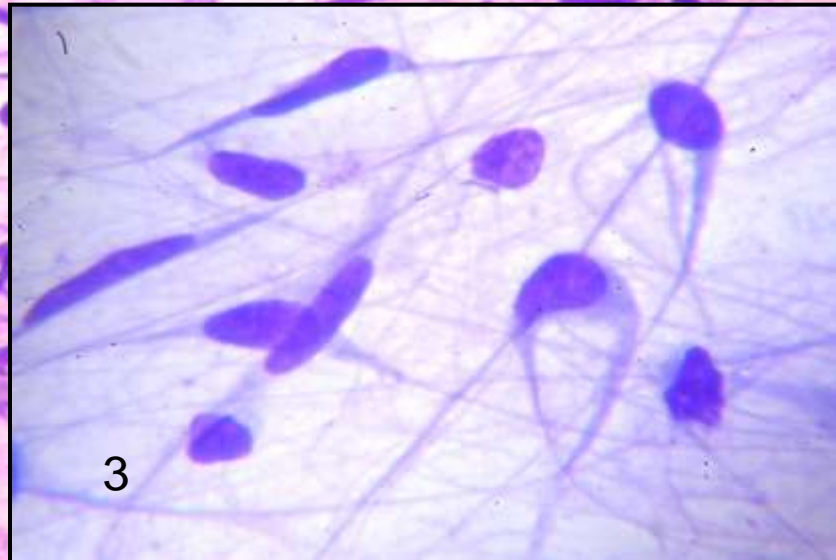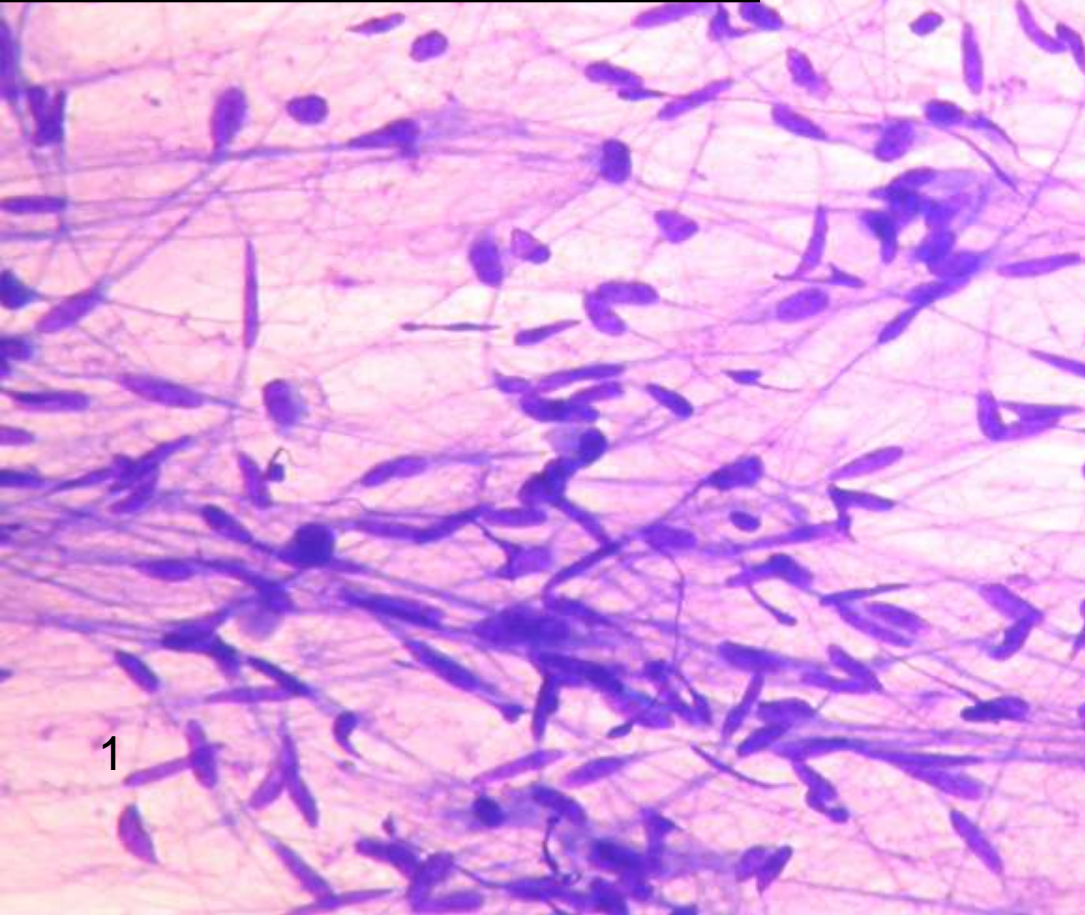
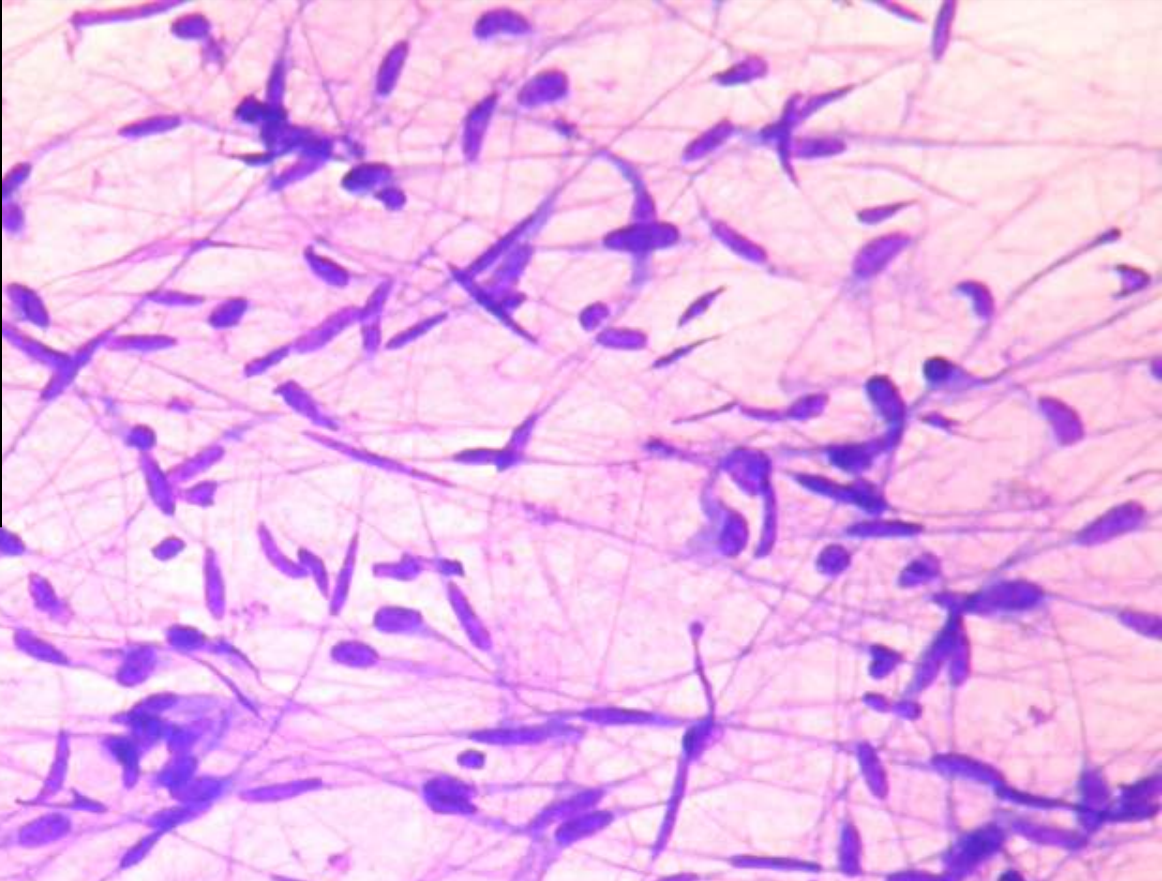
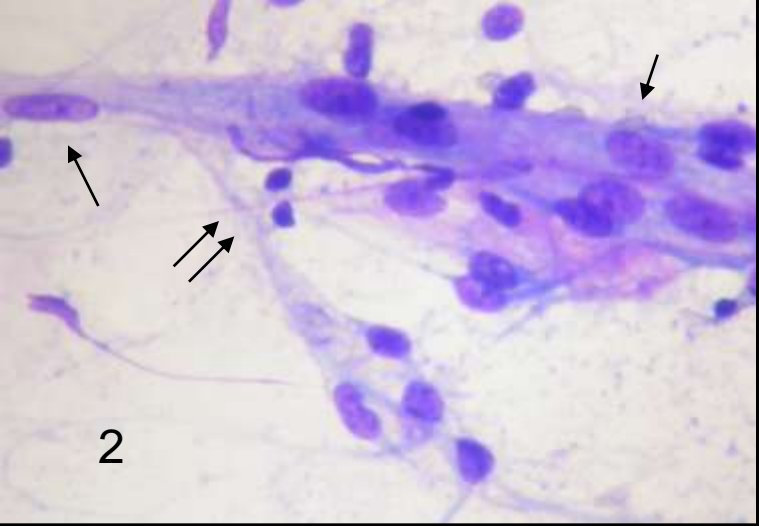


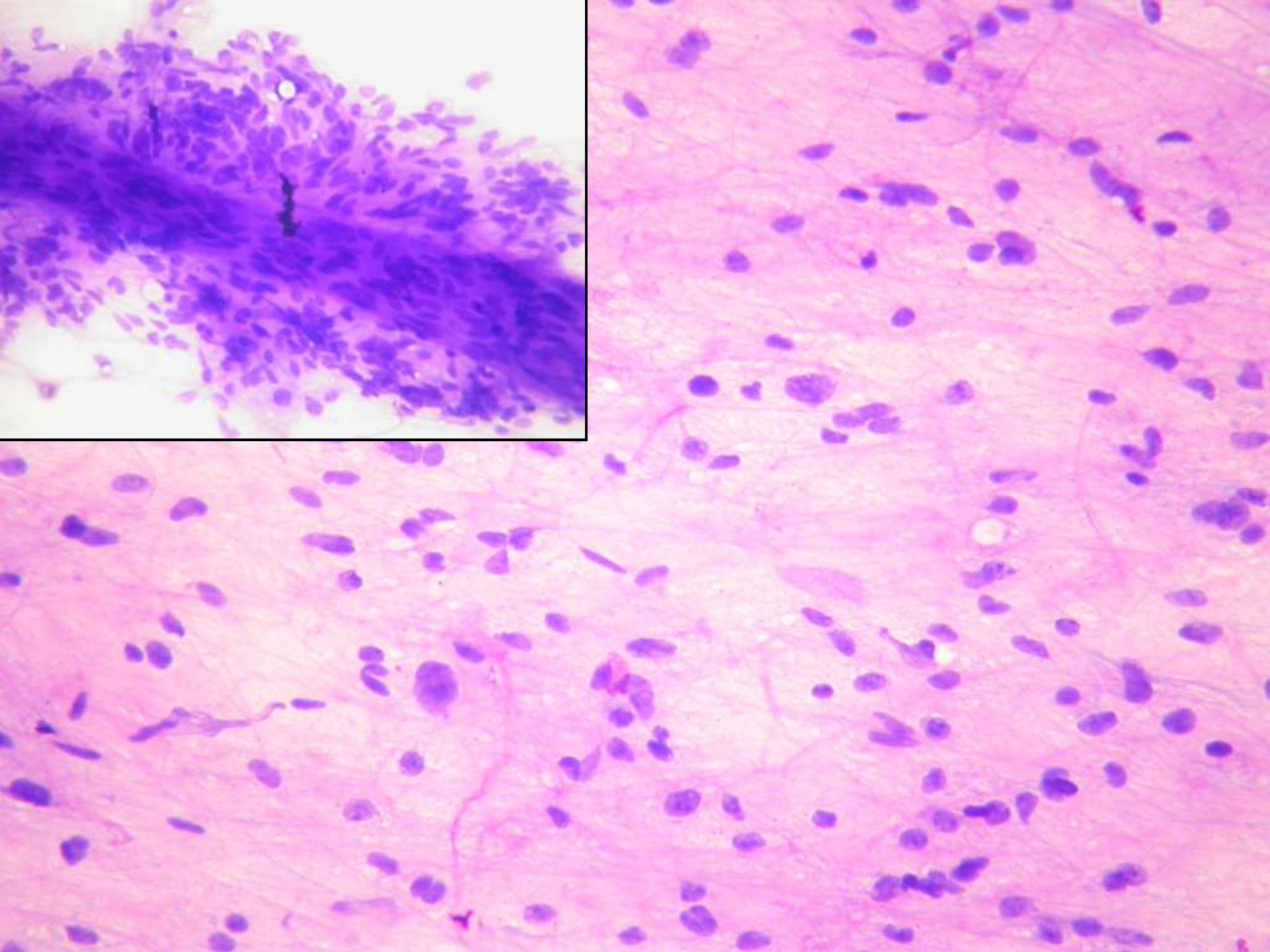
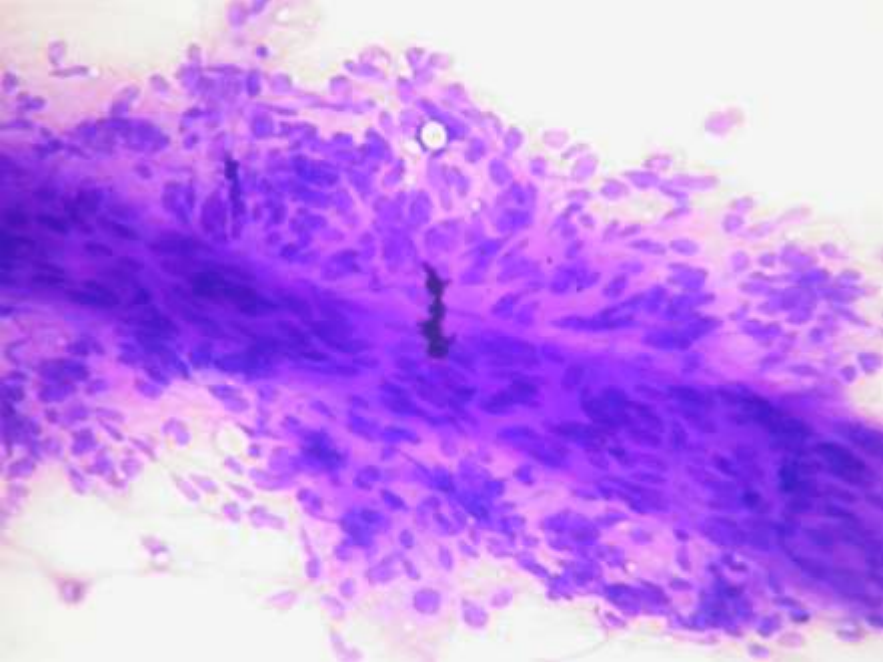


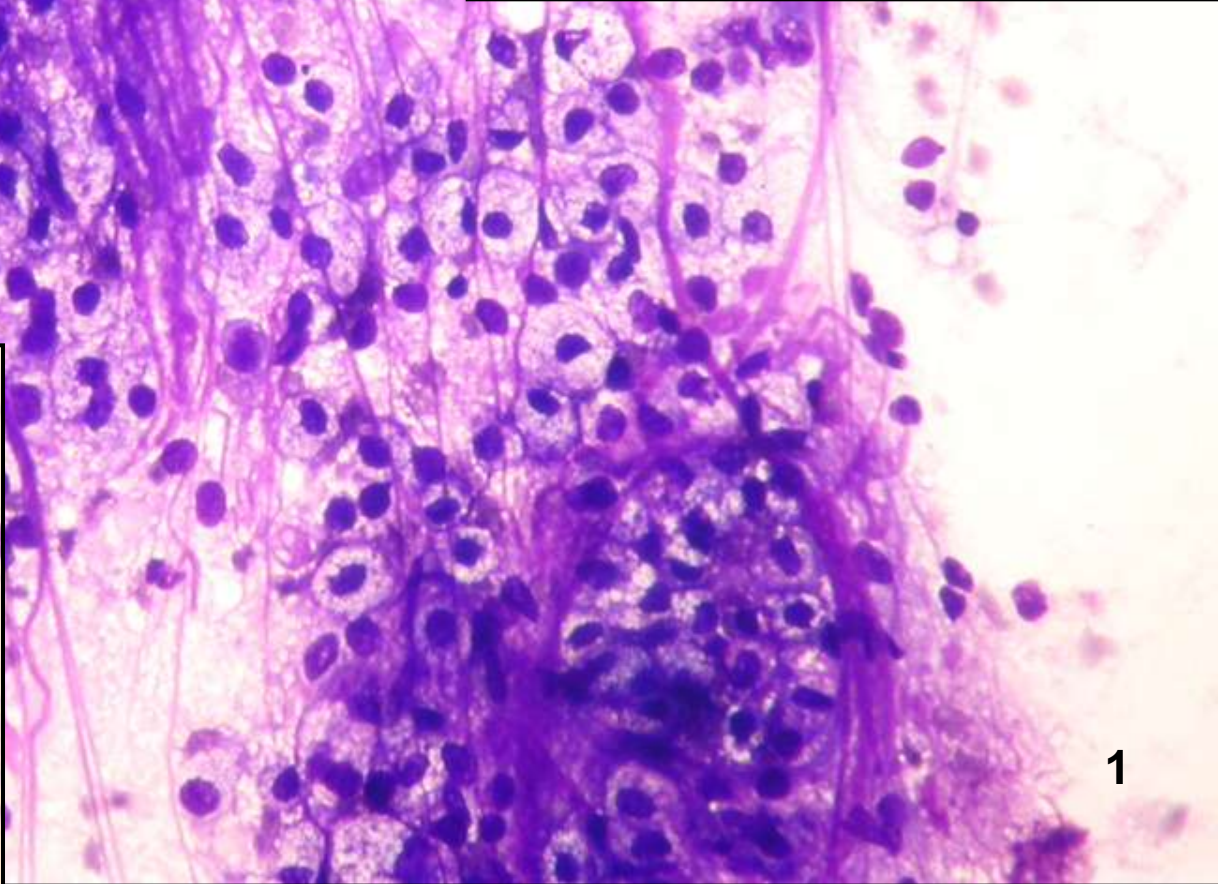
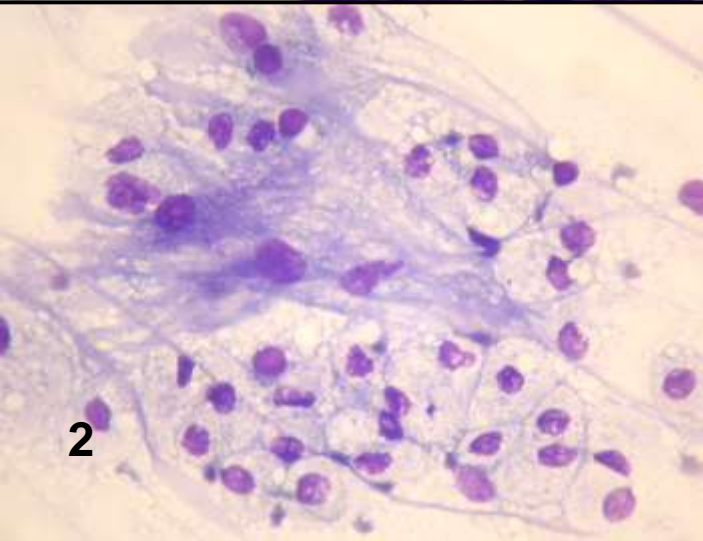
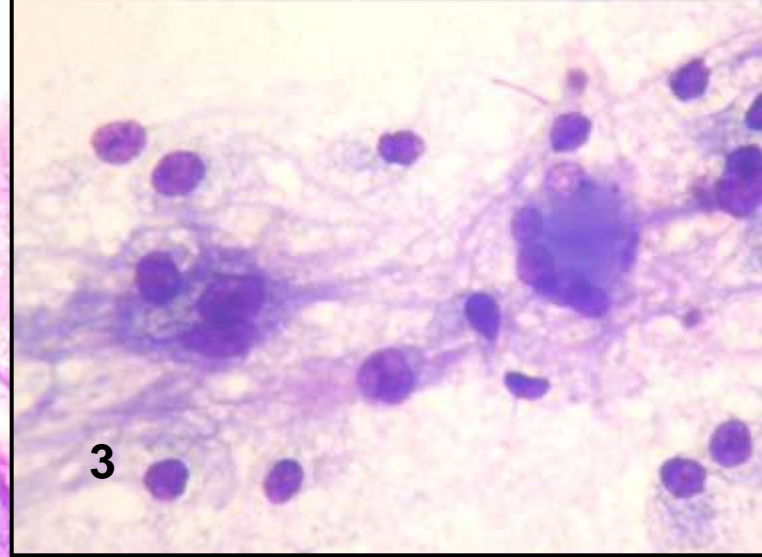
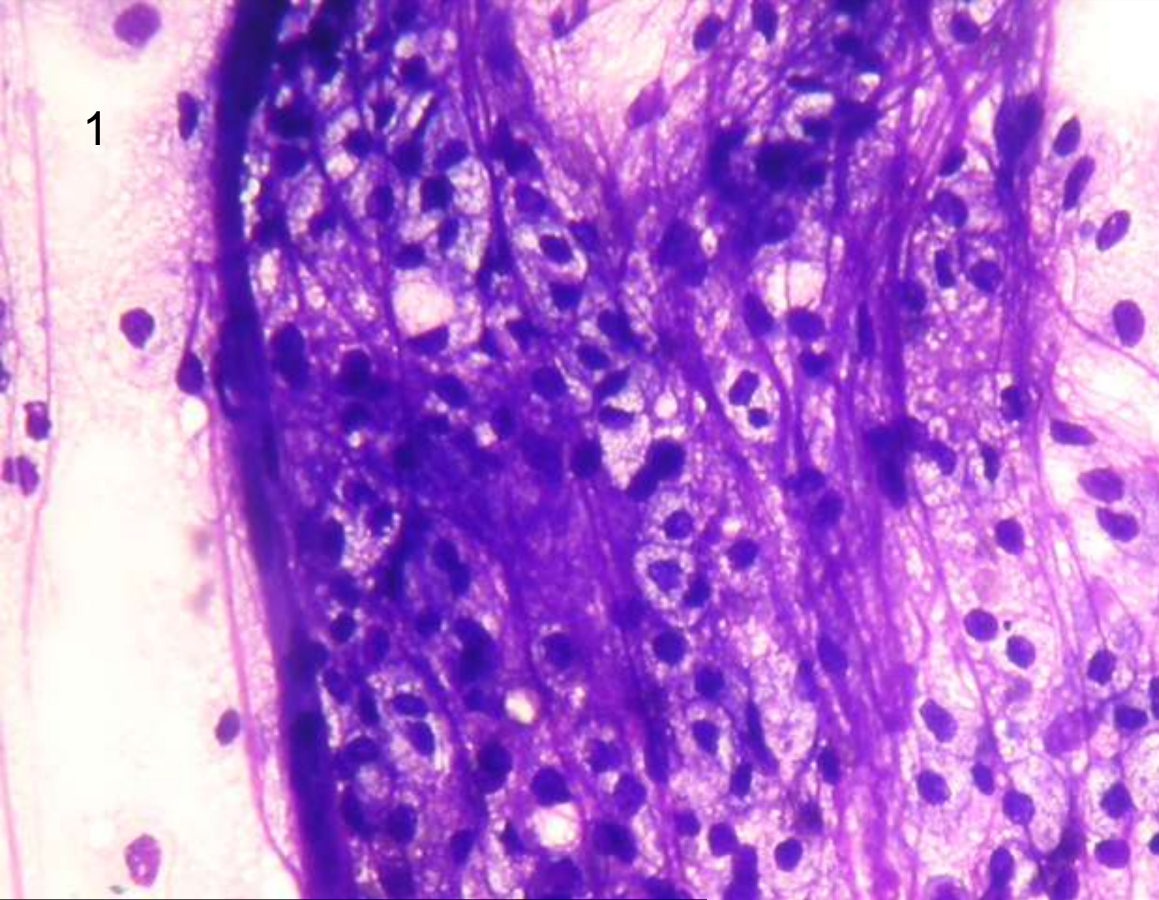


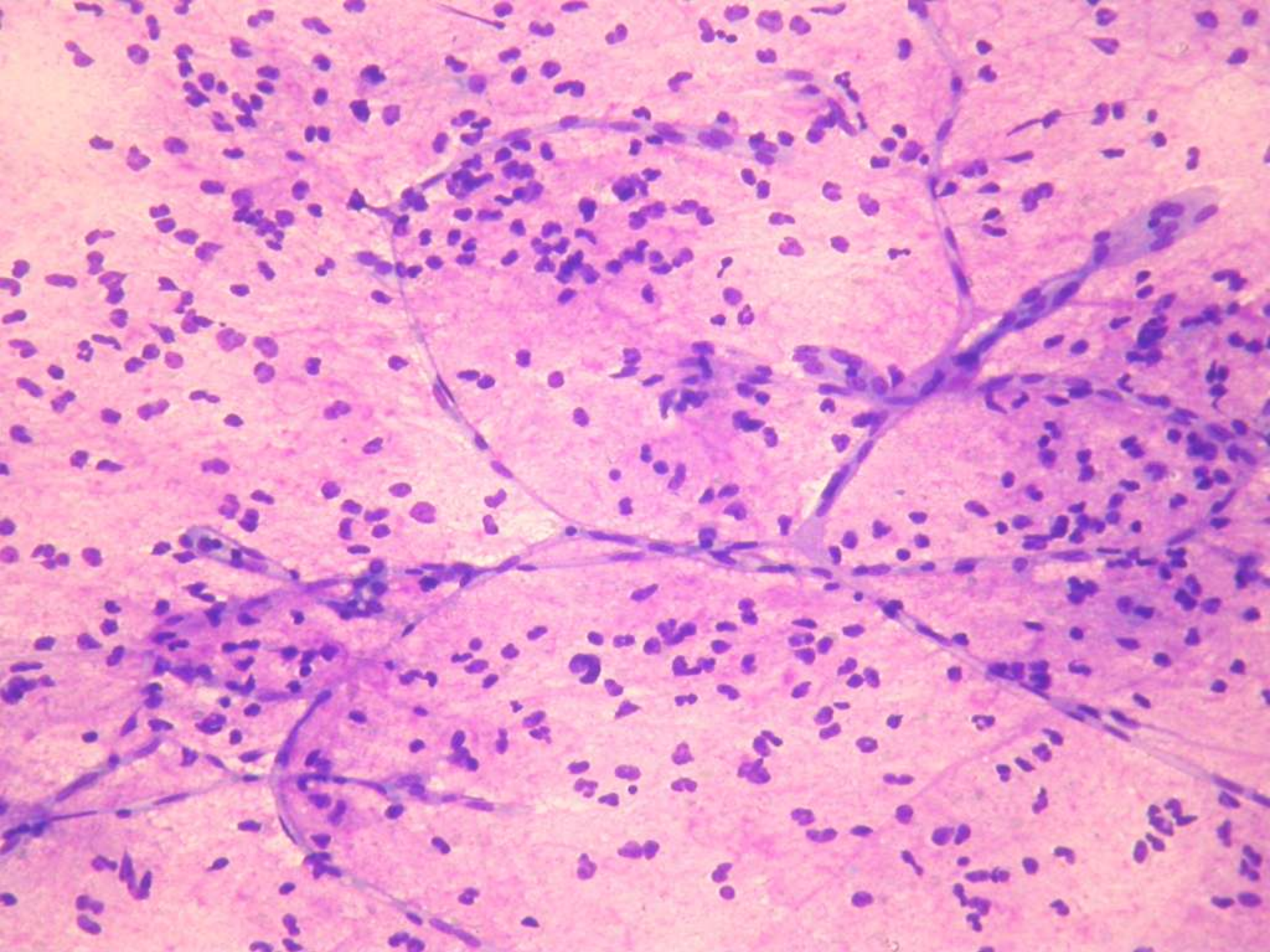


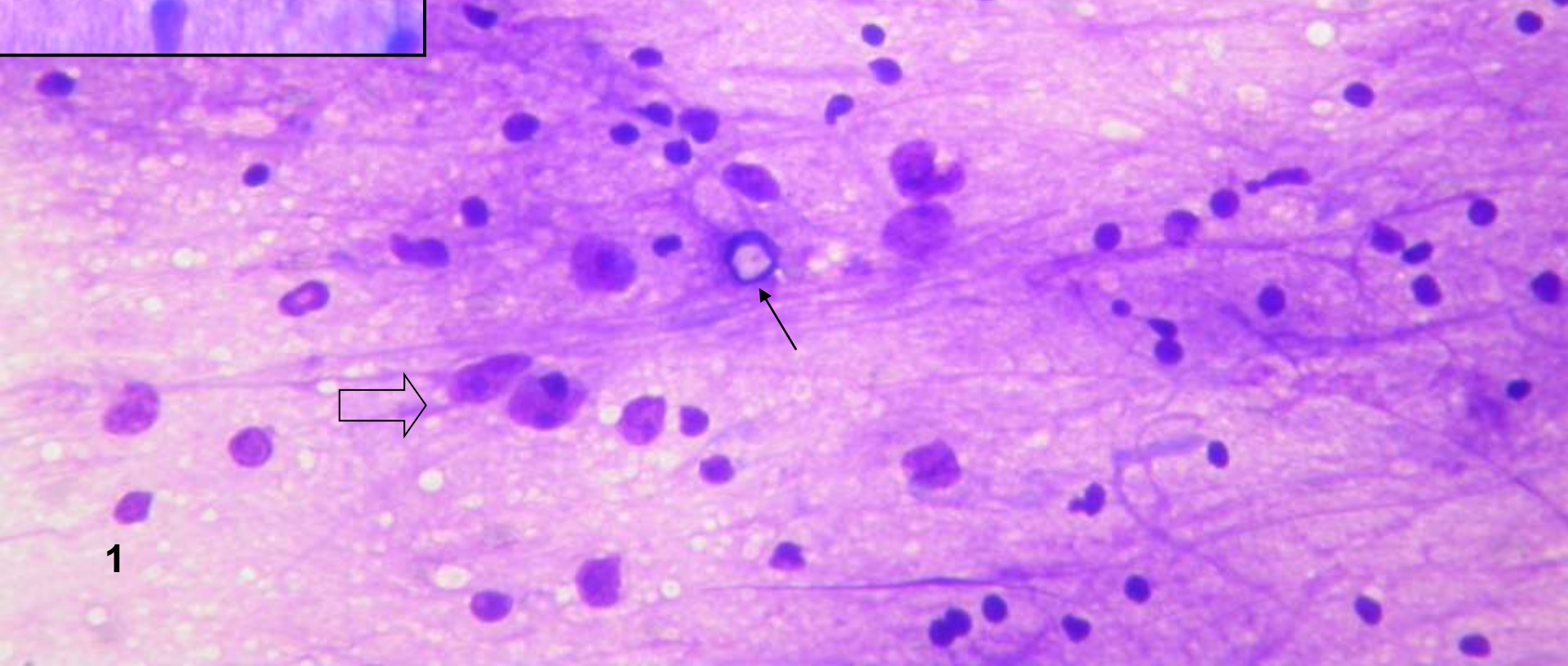
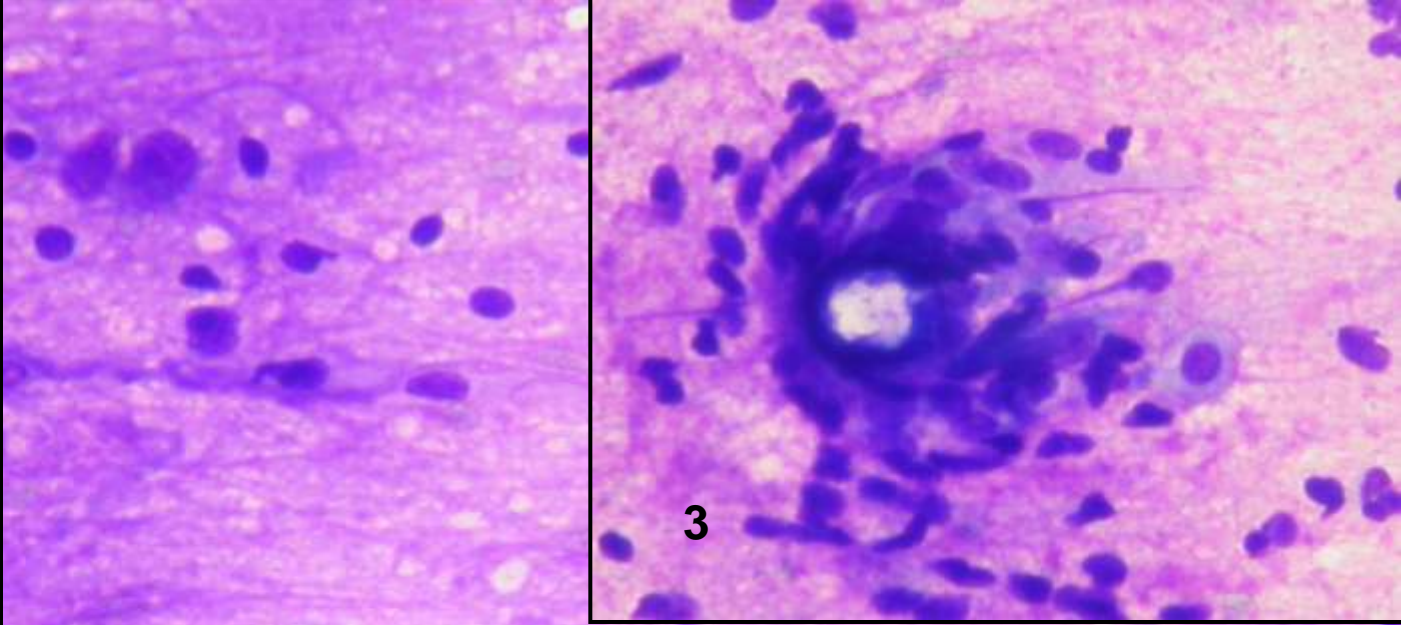
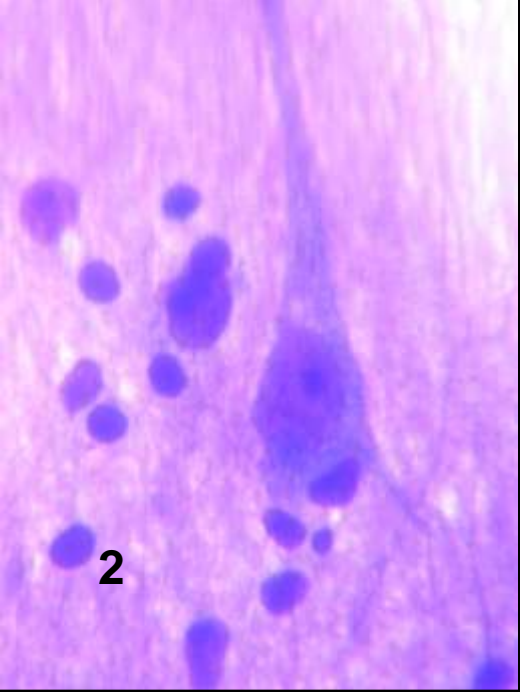


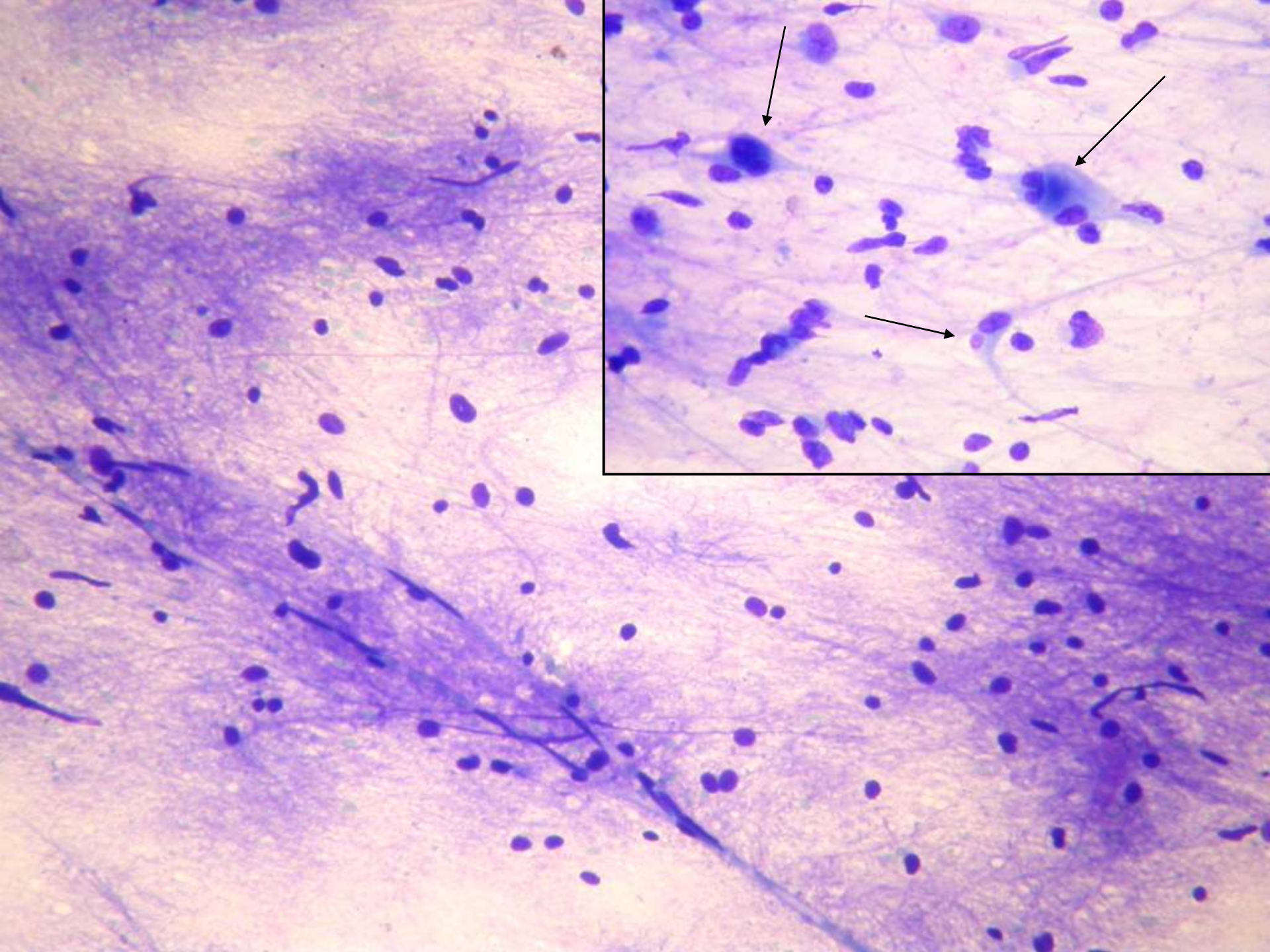


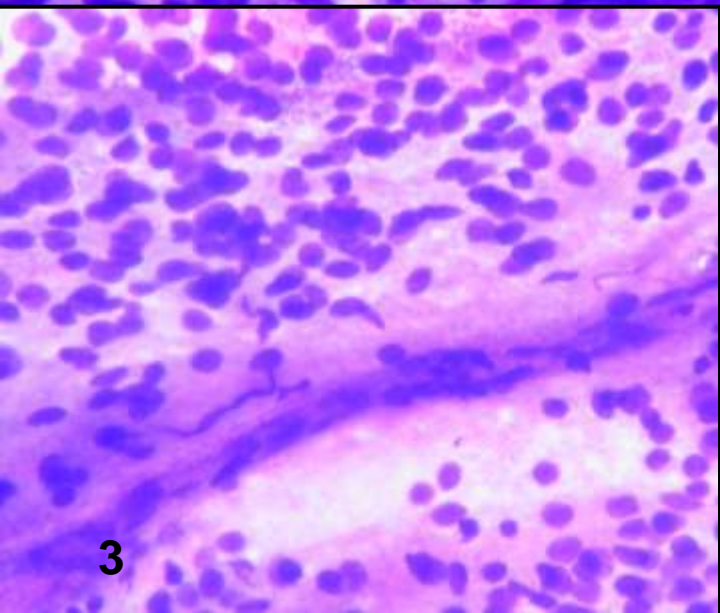
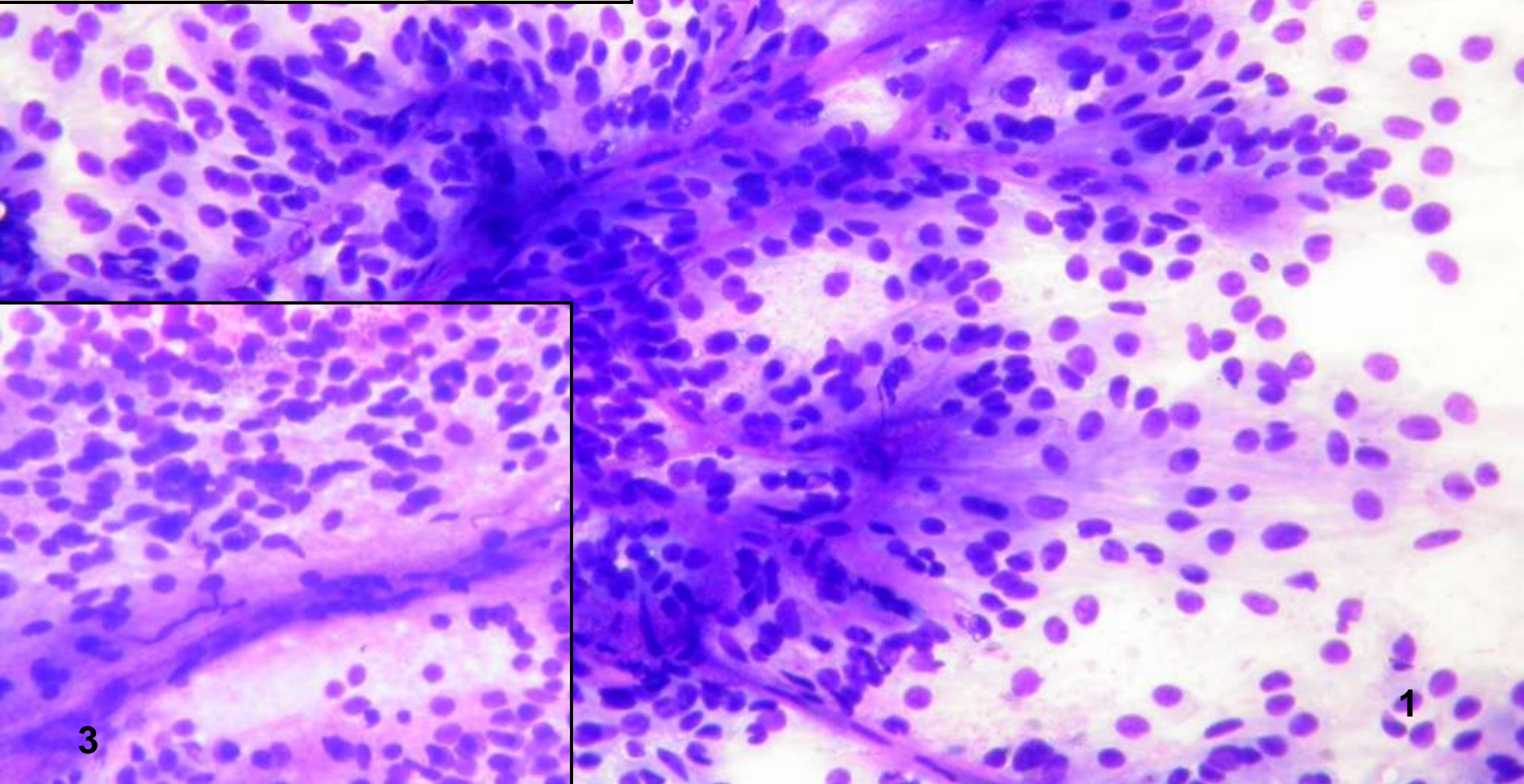
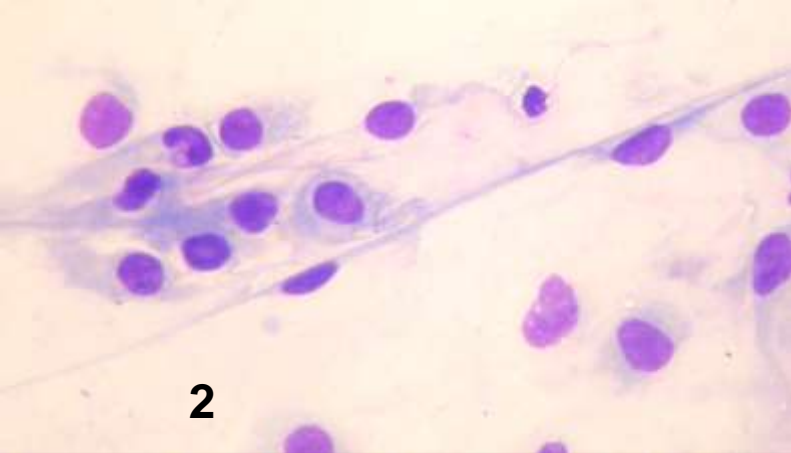




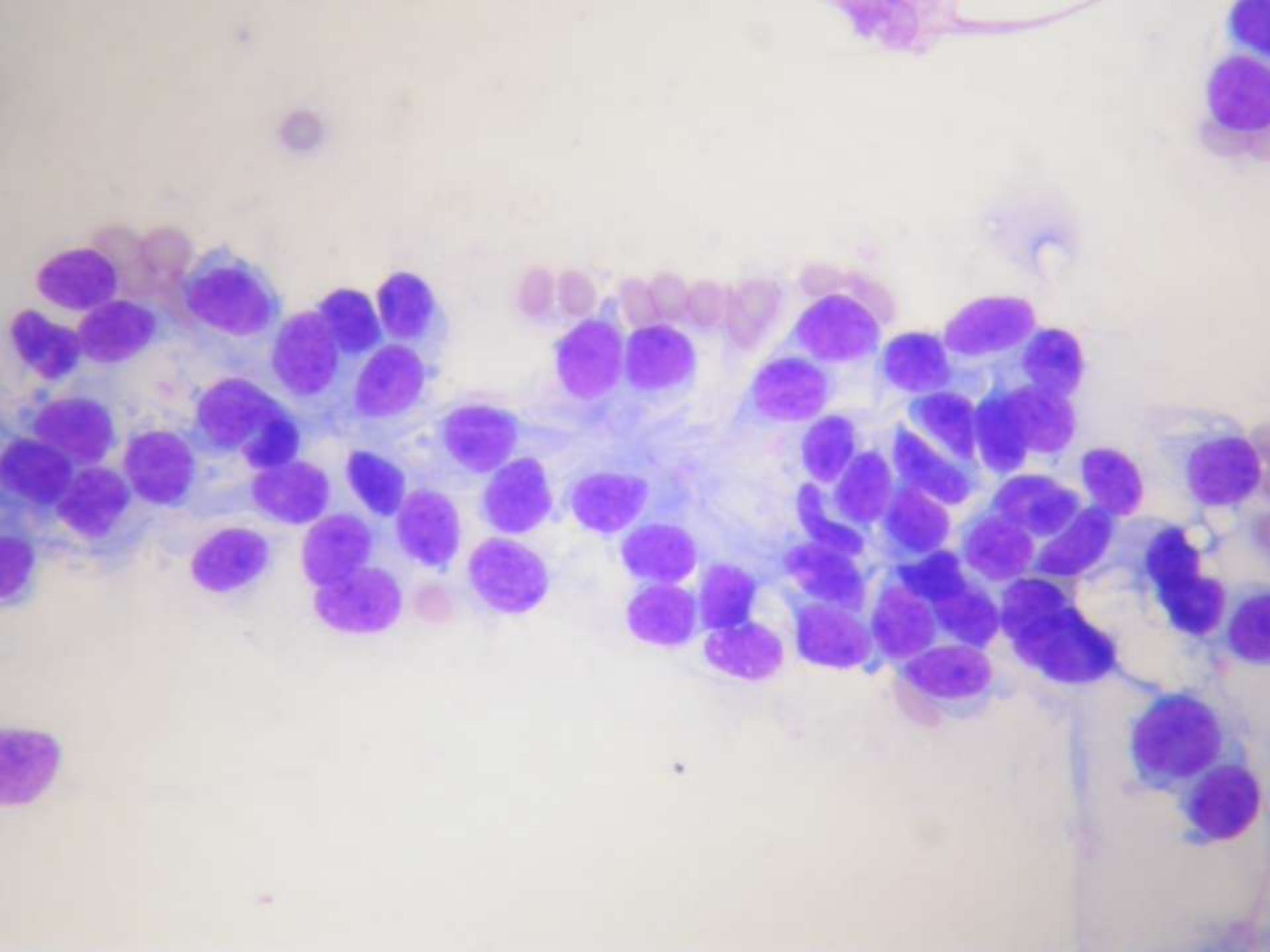


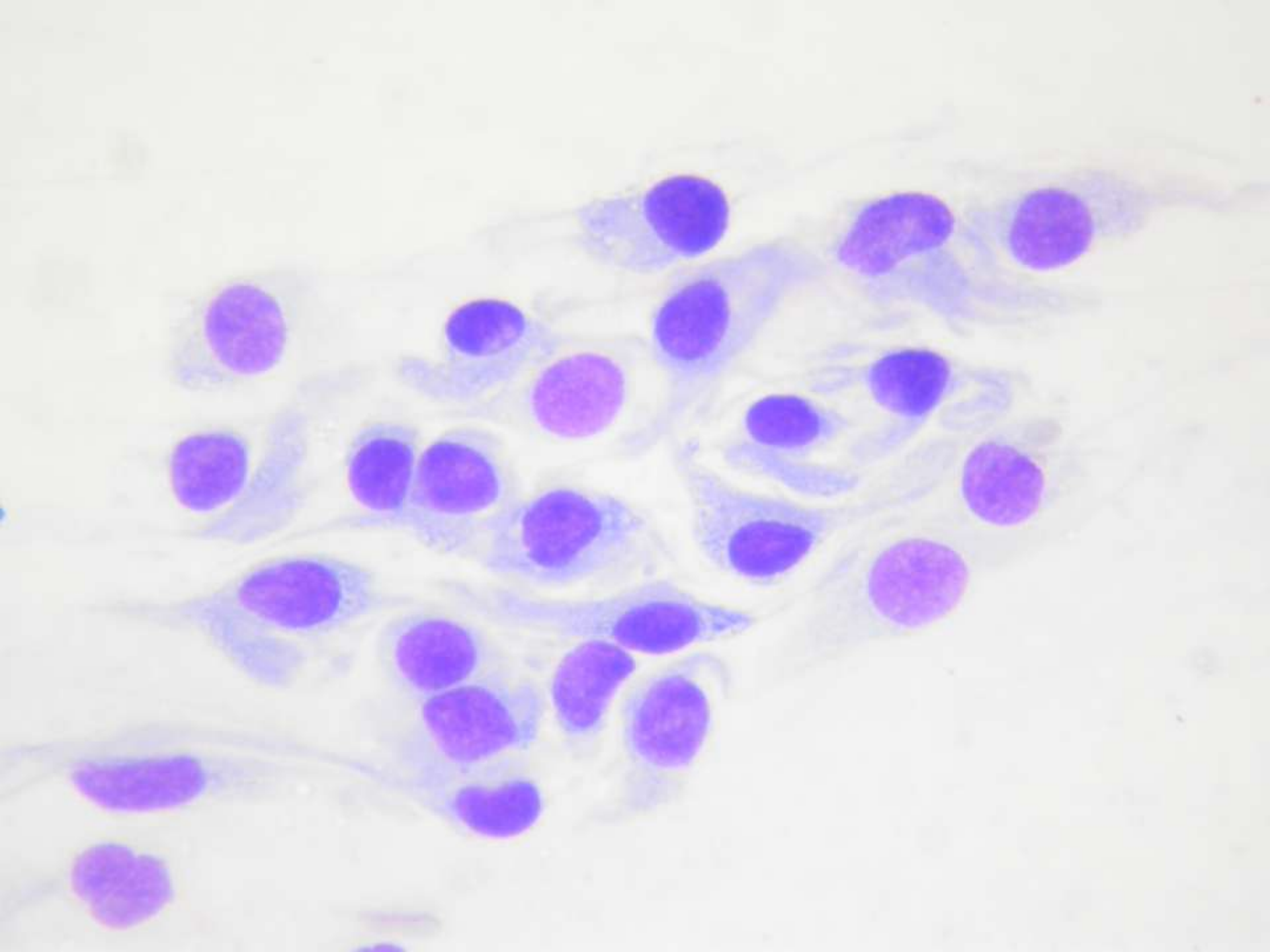


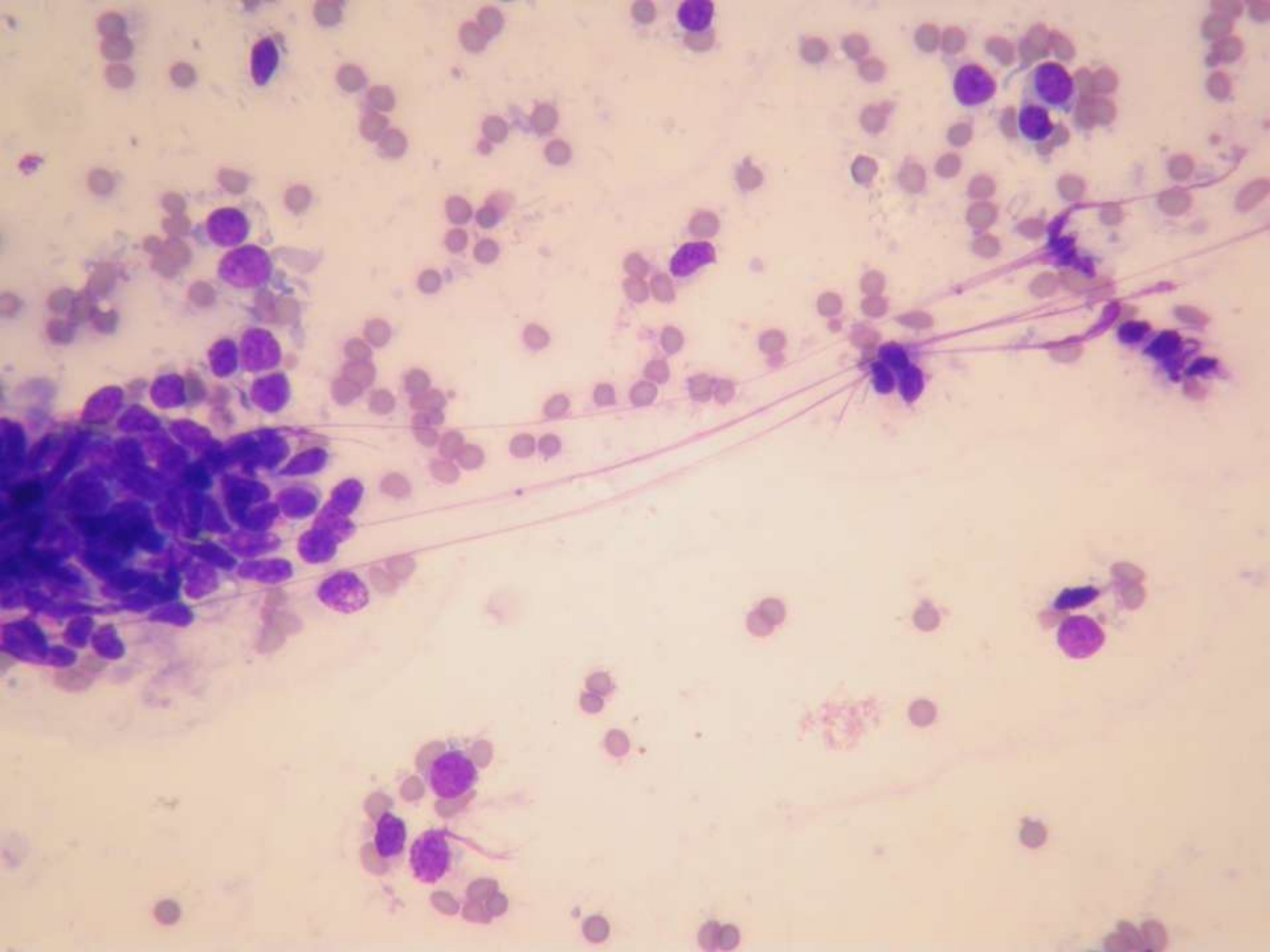


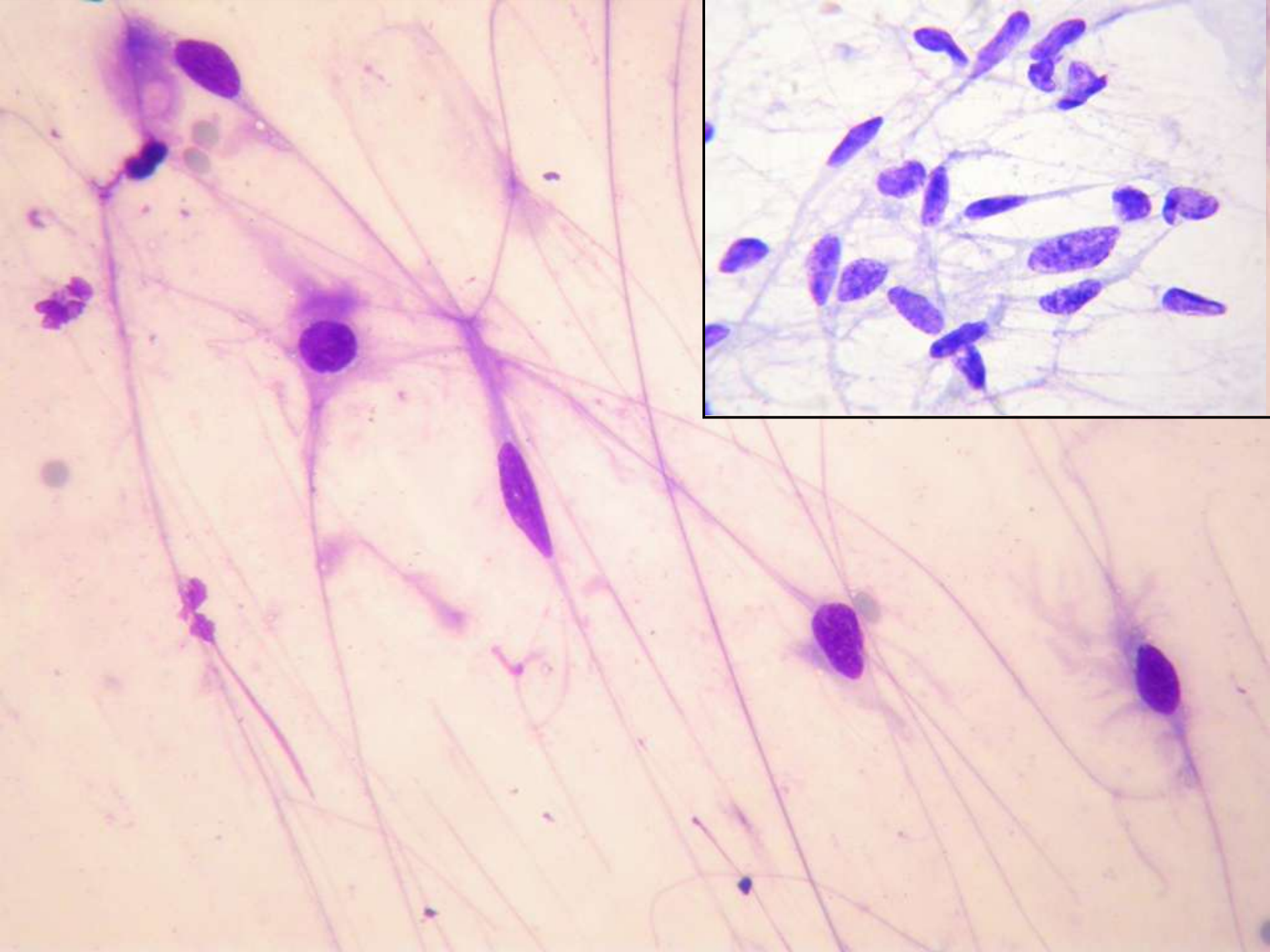


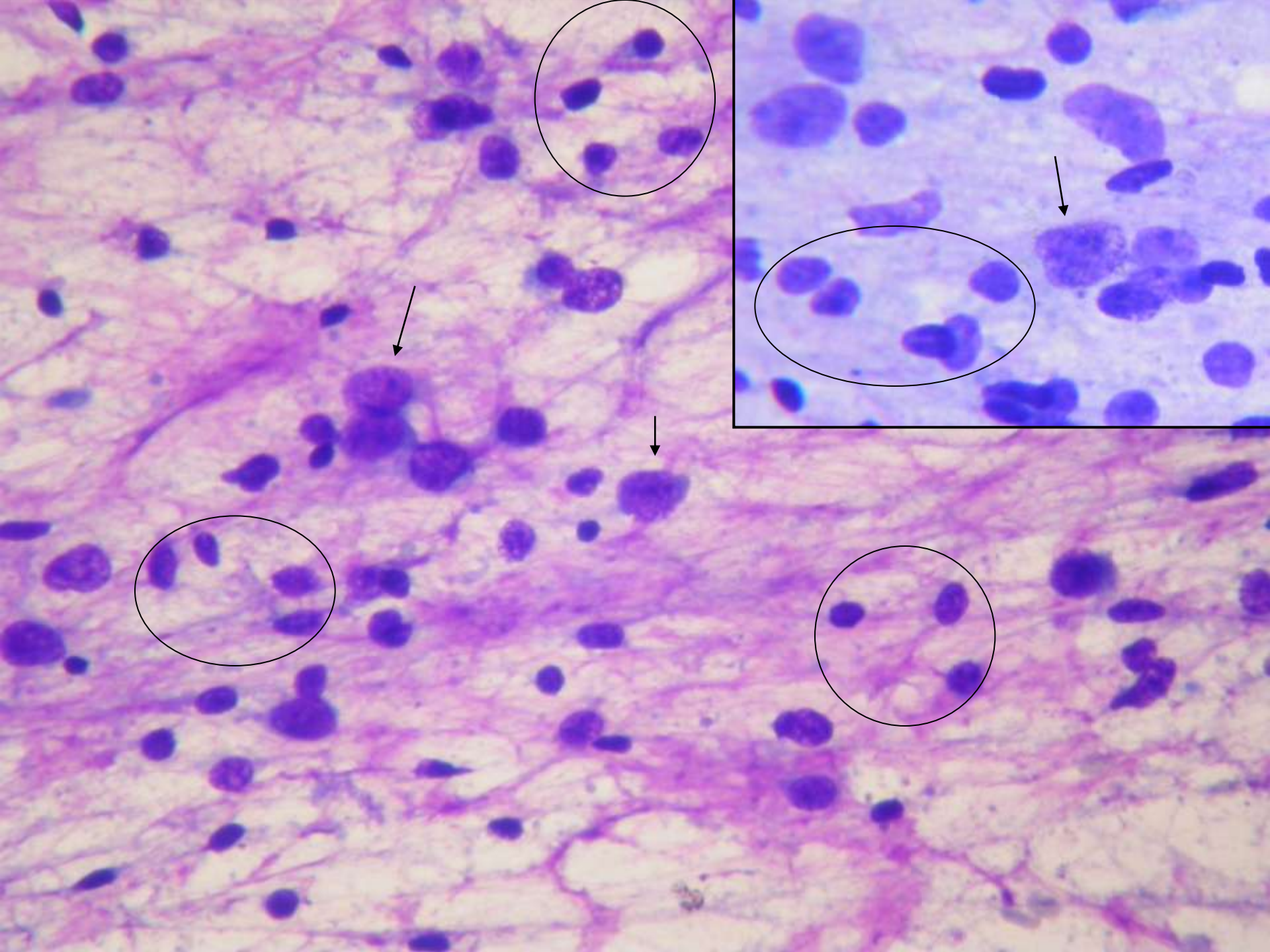


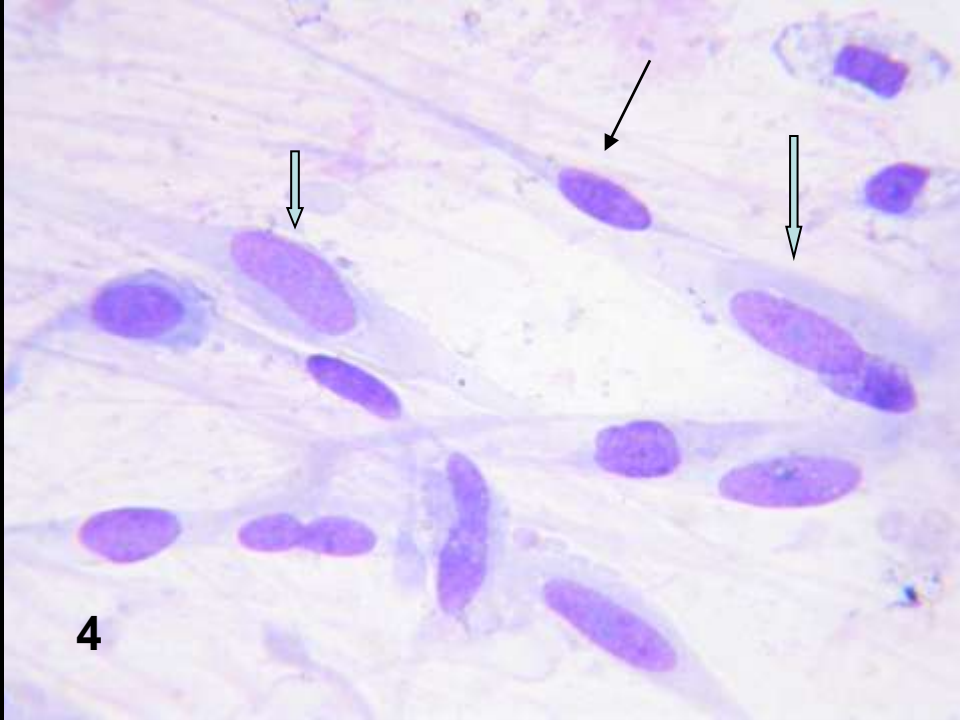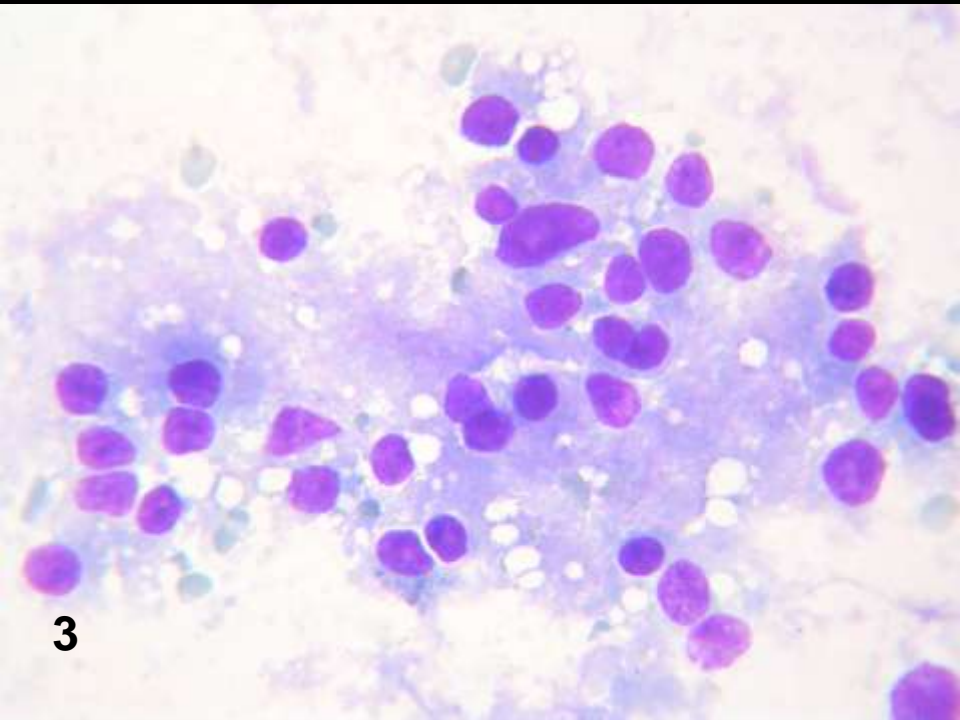
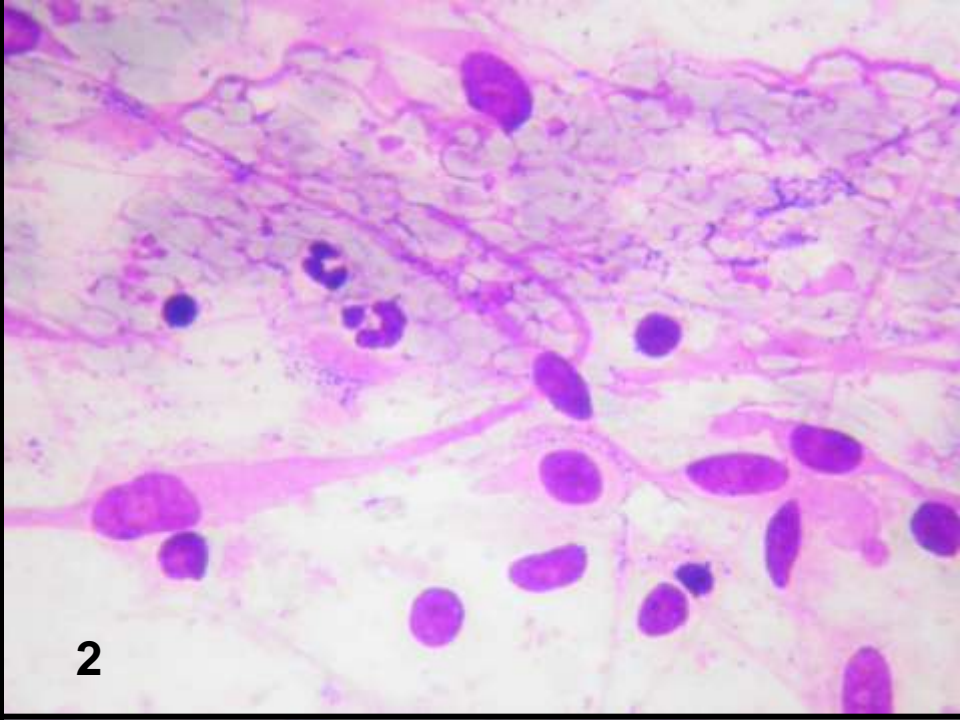
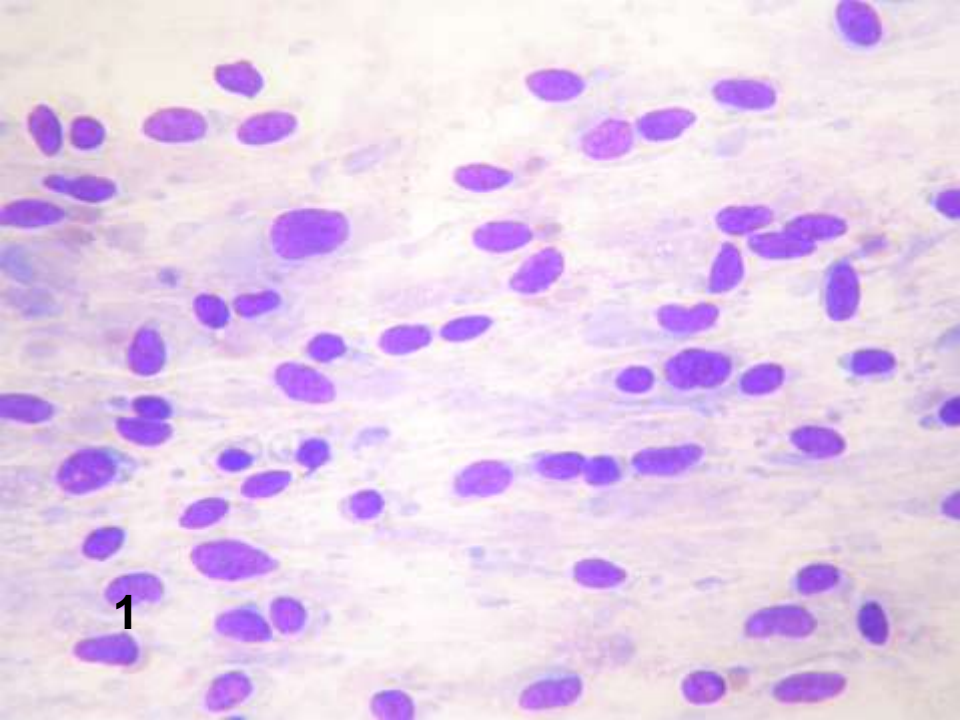


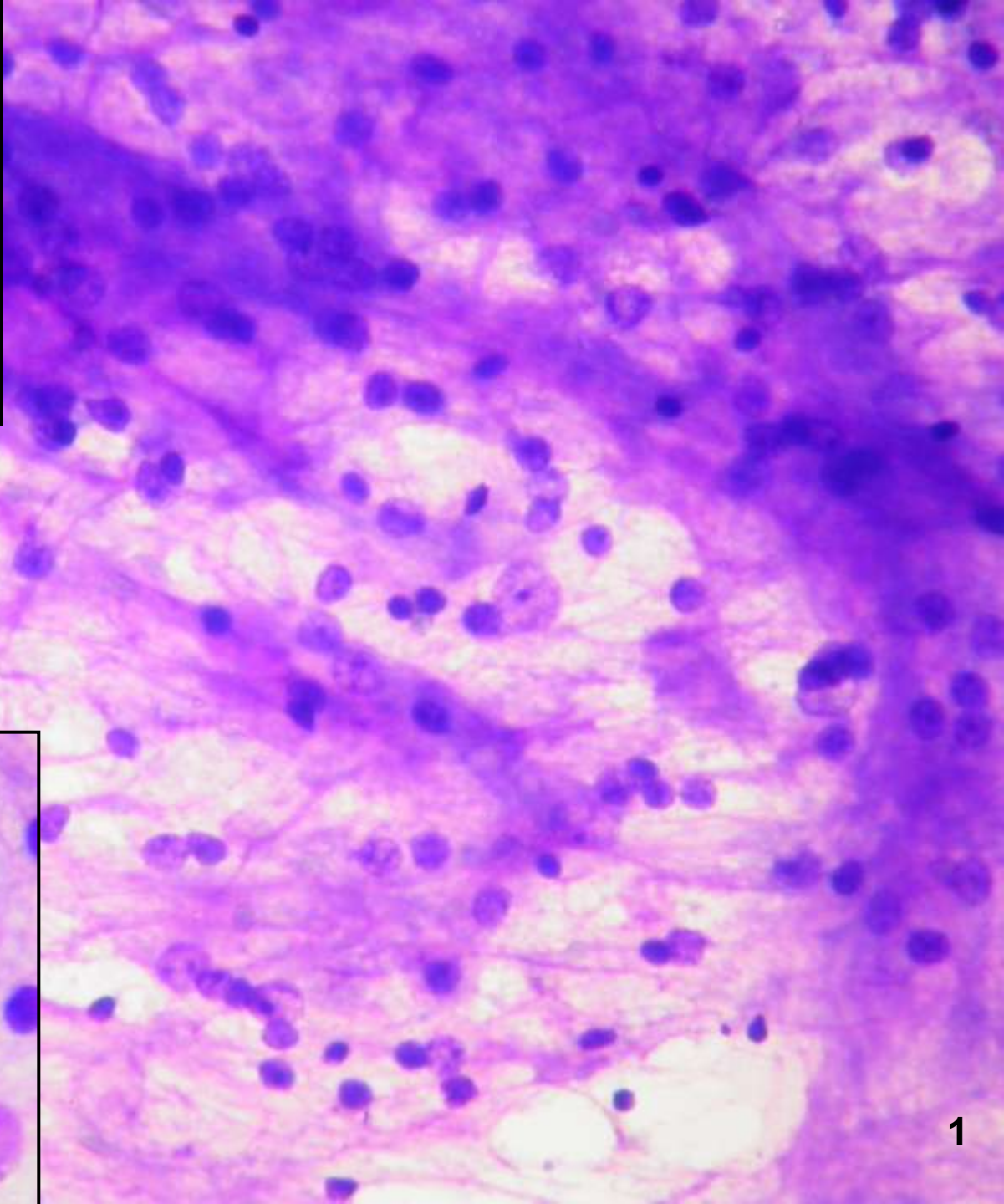
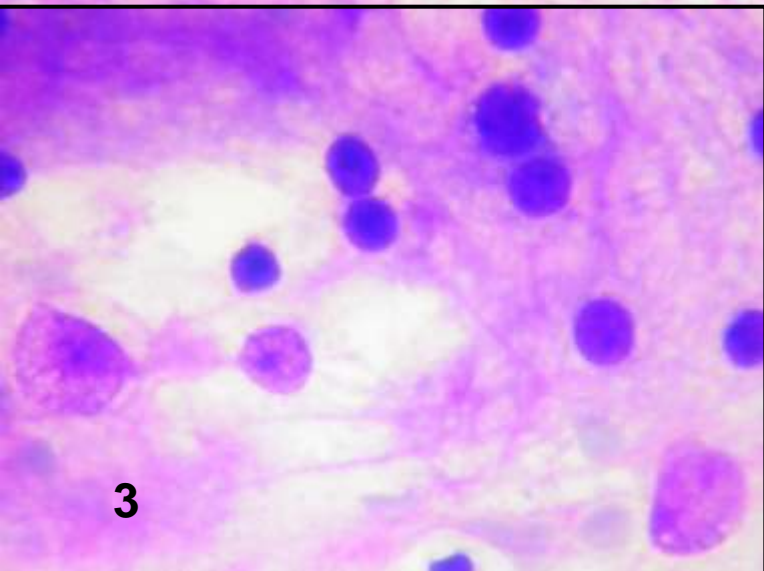
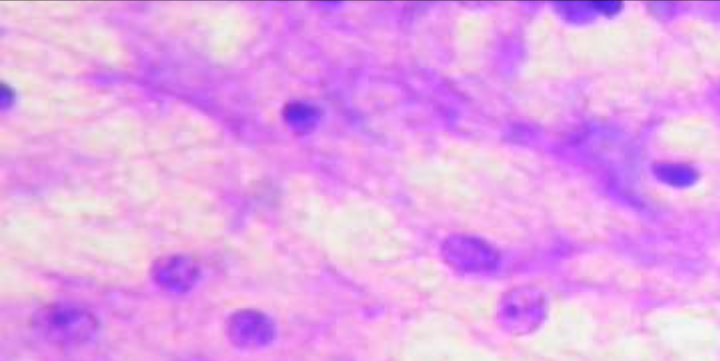
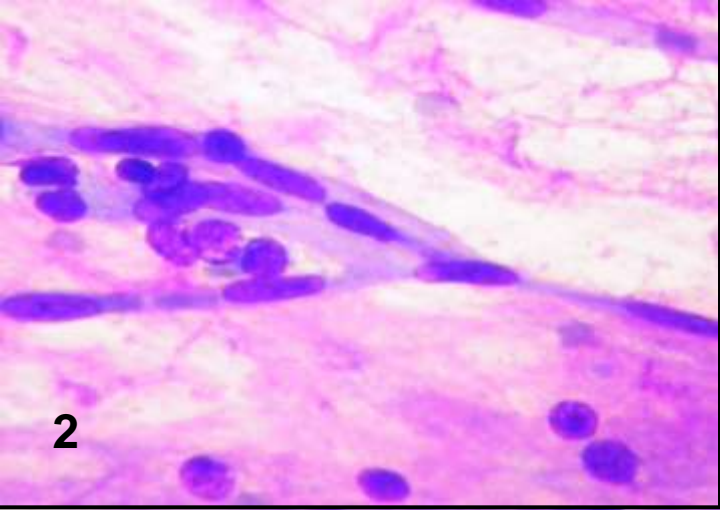


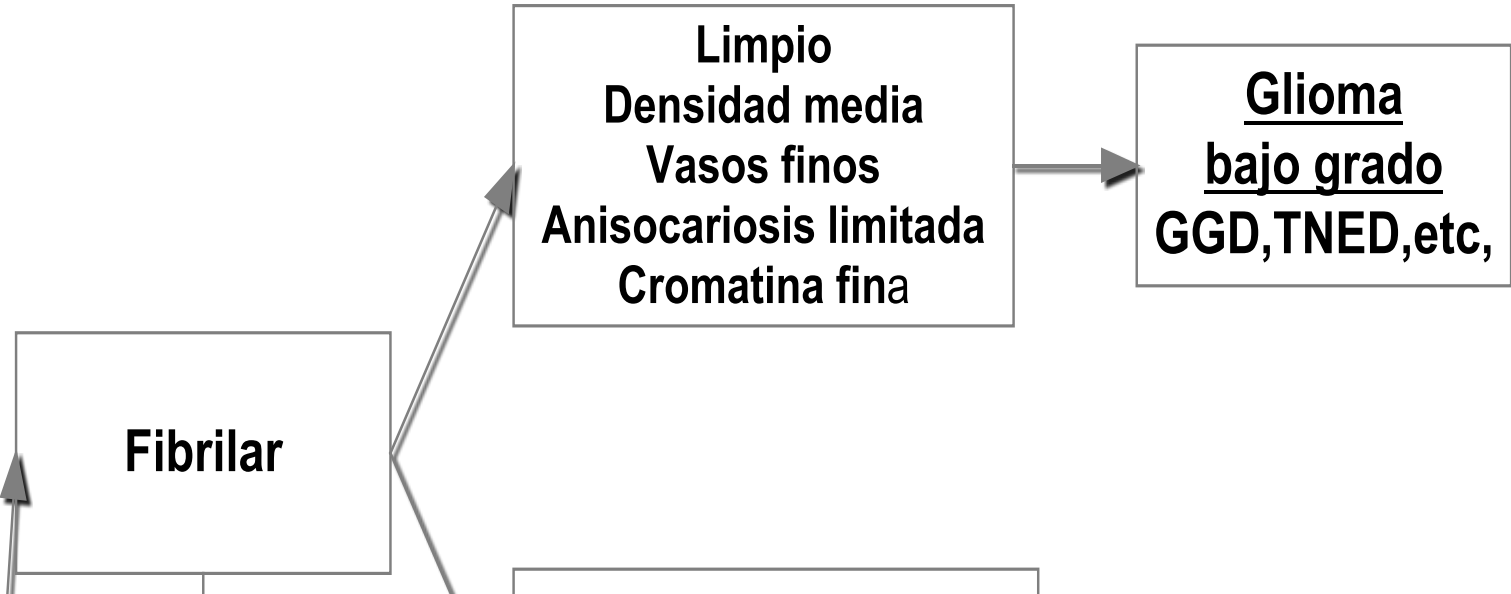












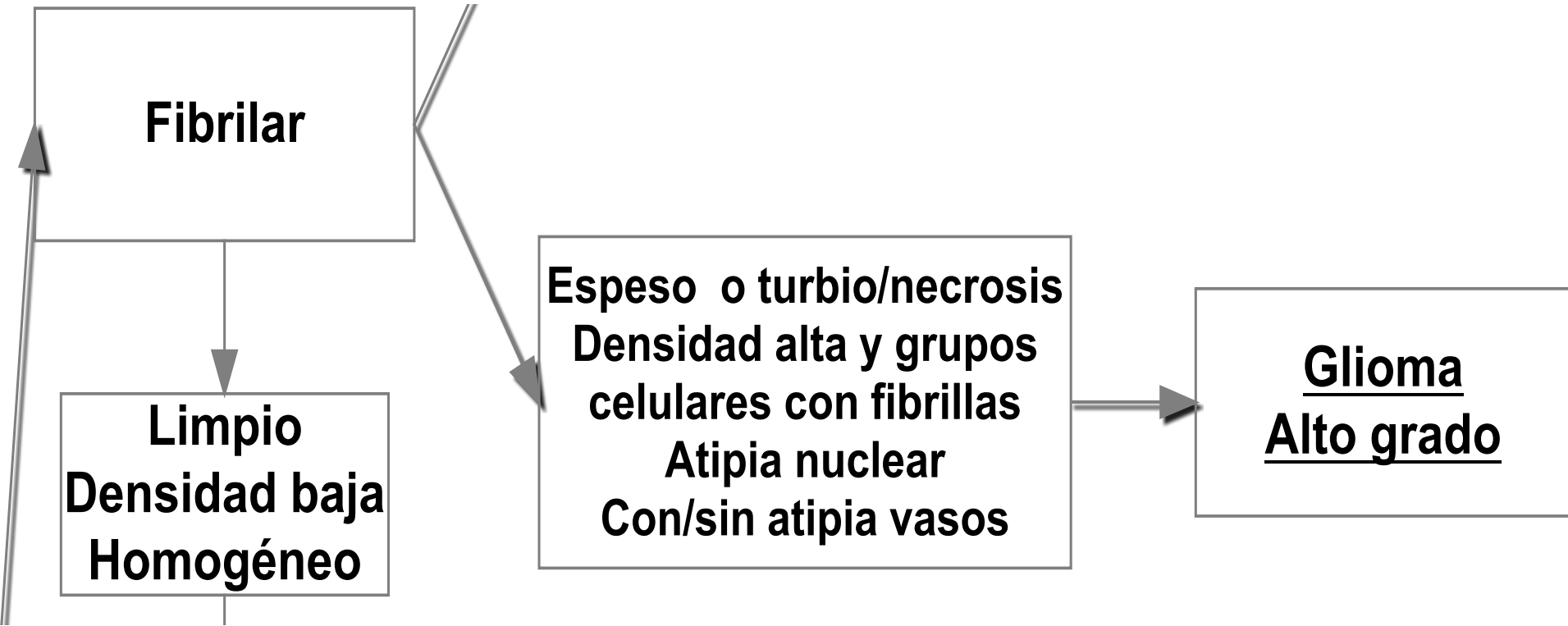


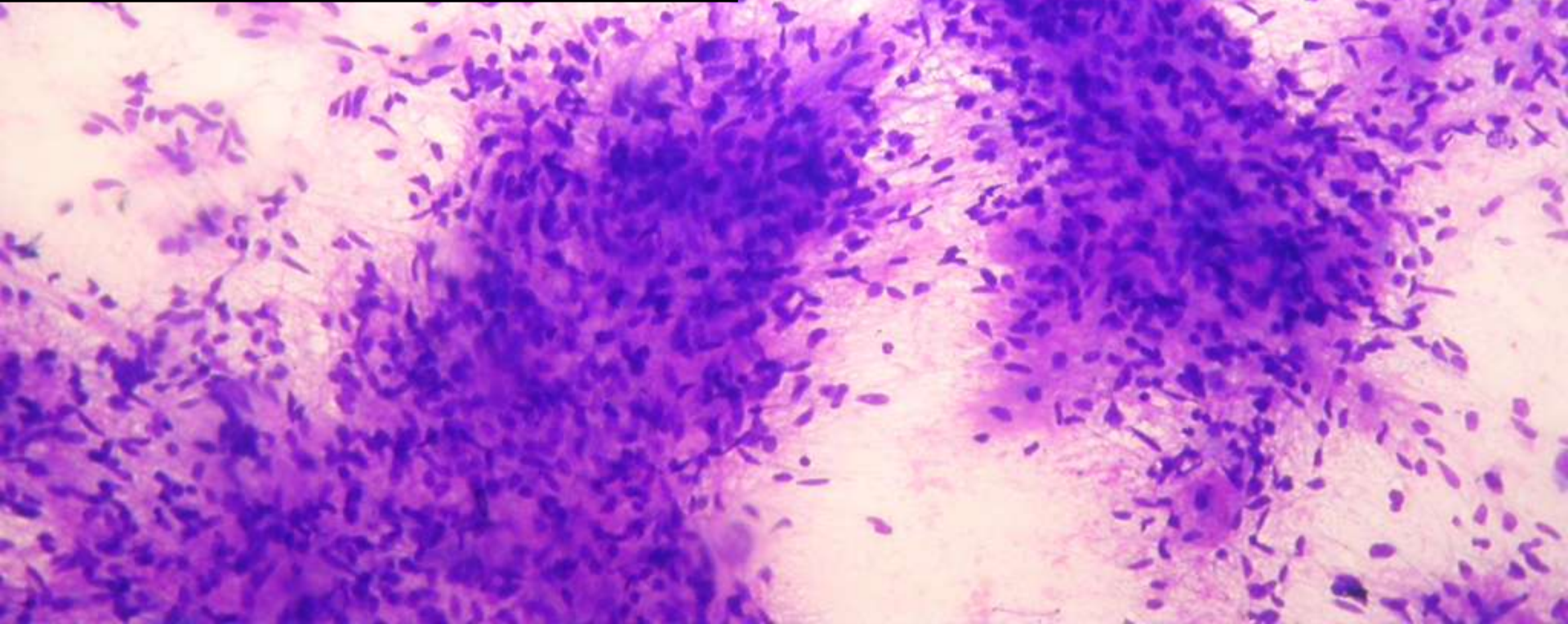
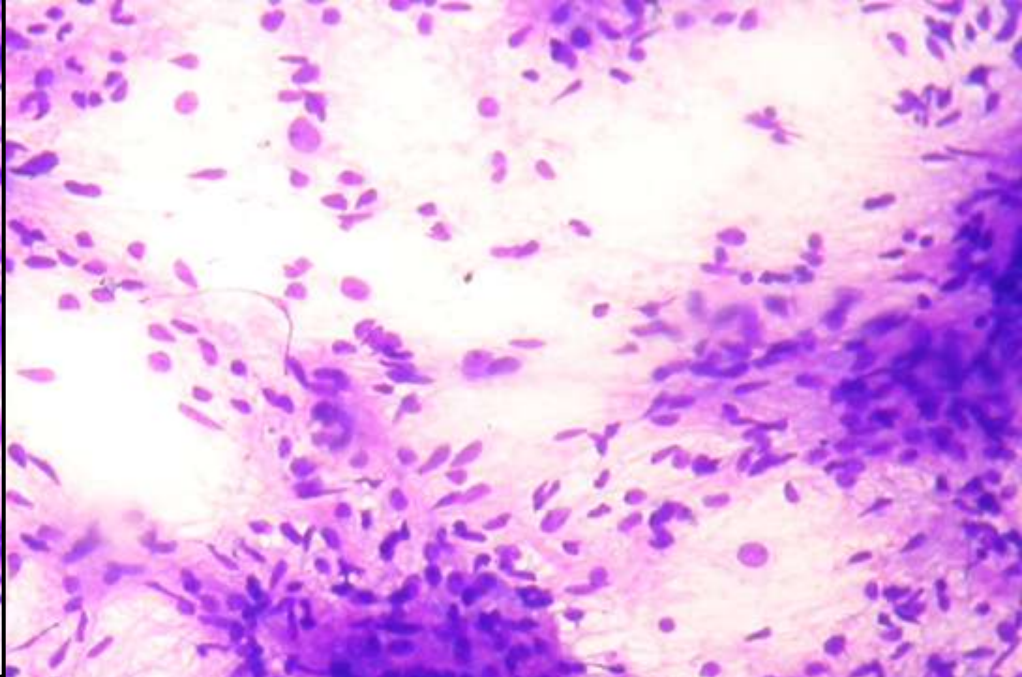
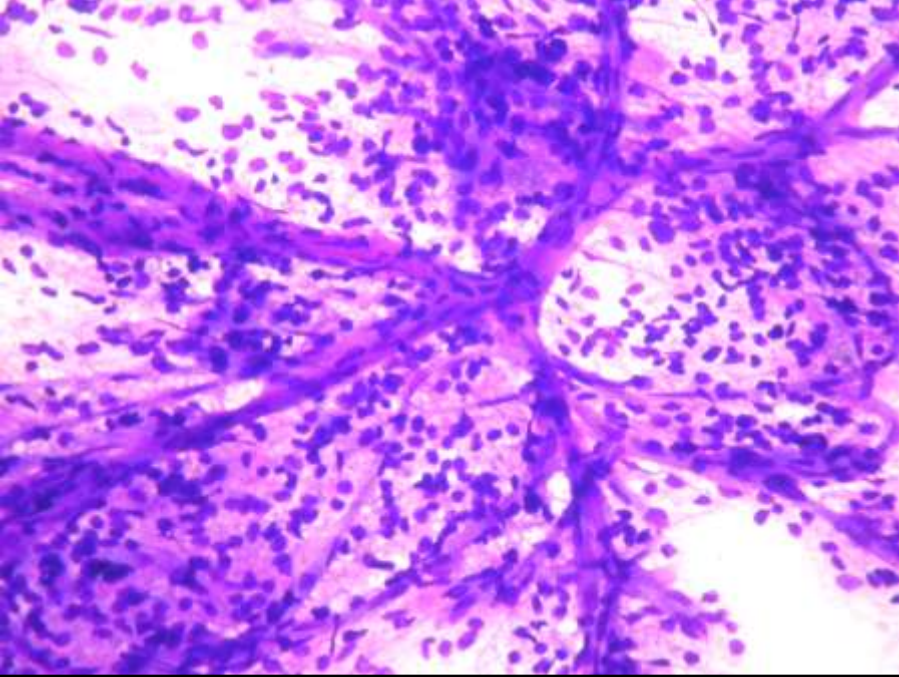
**Fibrilar**

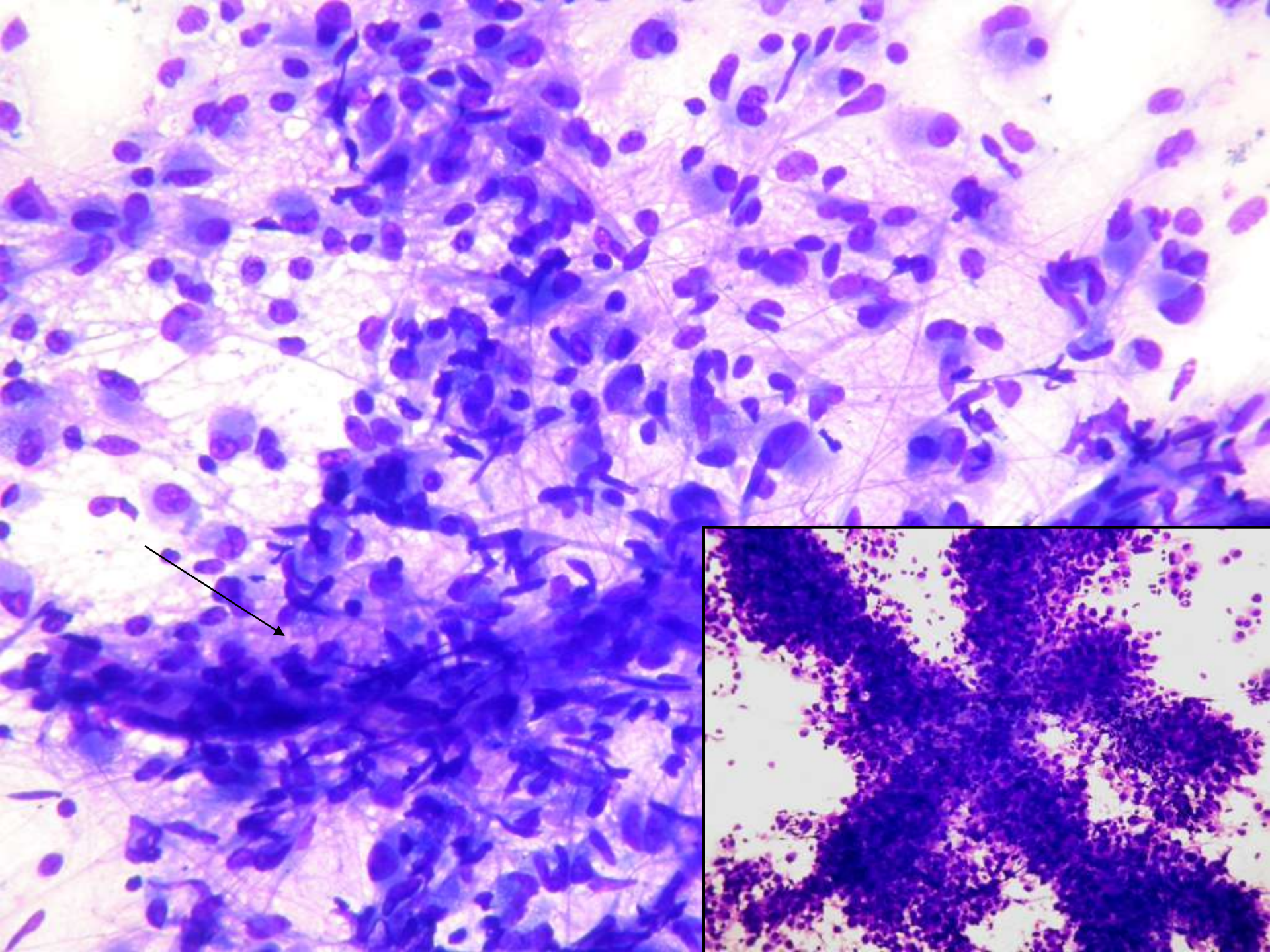
**Limpio**  
**Densidad baja**  
**Homogéneo**

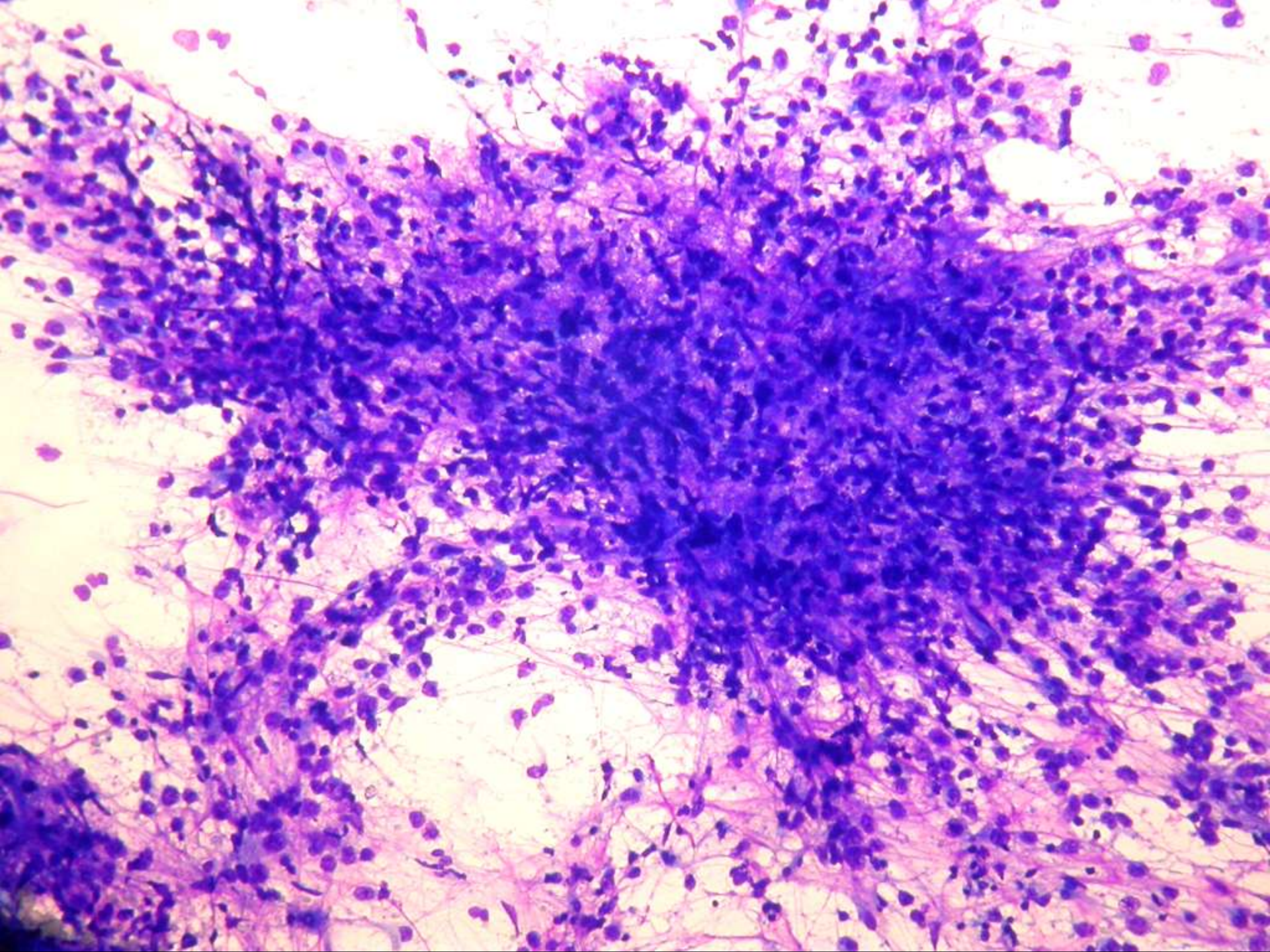
**Espeso o turbio/necrosis**  
**Densidad alta y grupos**  
**celulares con fibrillas**  
**Atipia nuclear**  
**Con/sin atipia vasos**

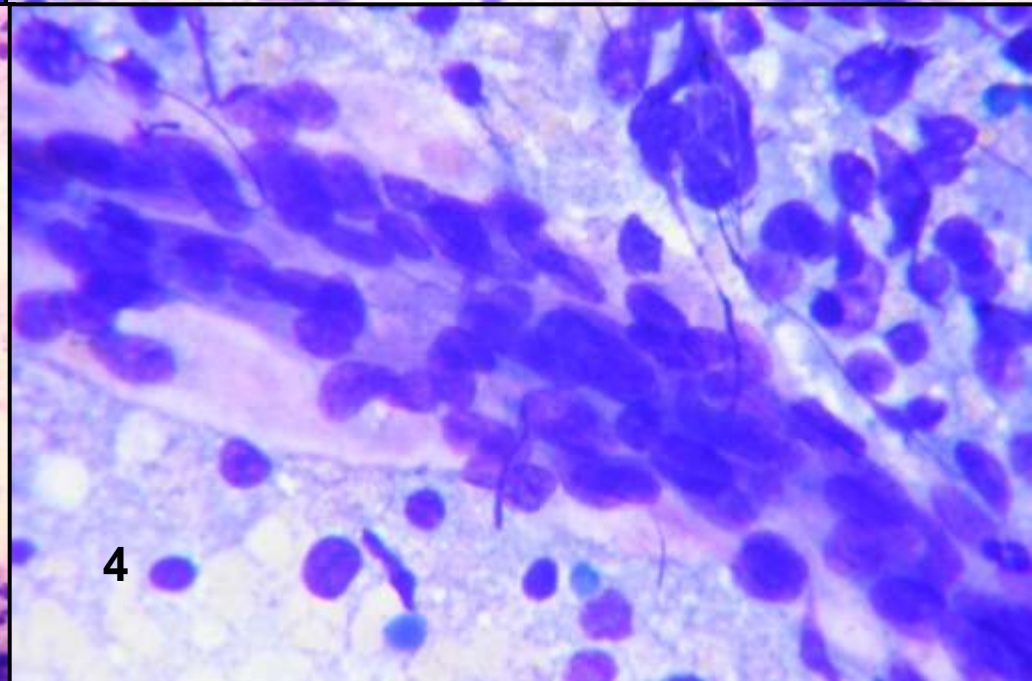
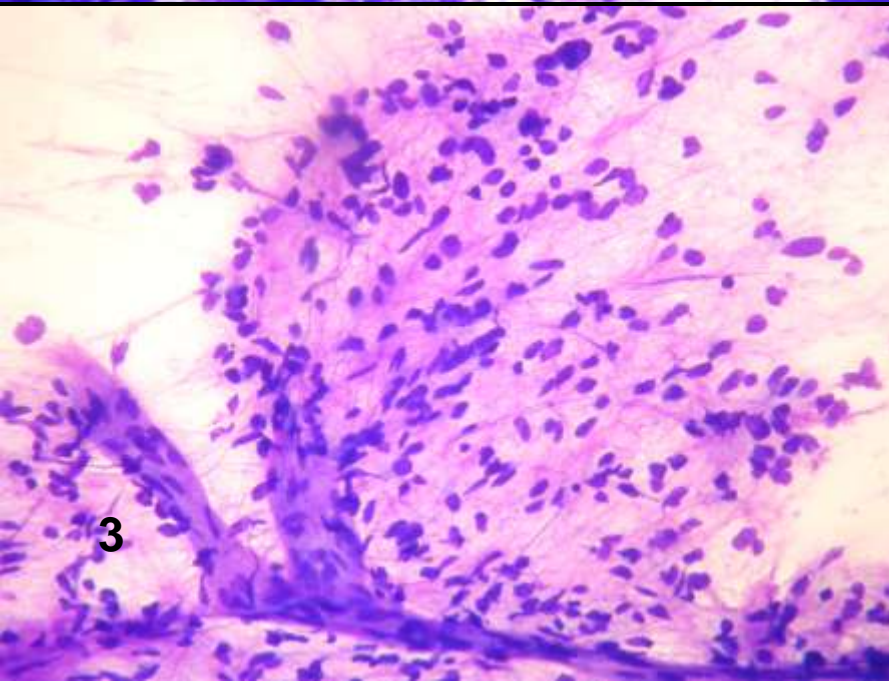
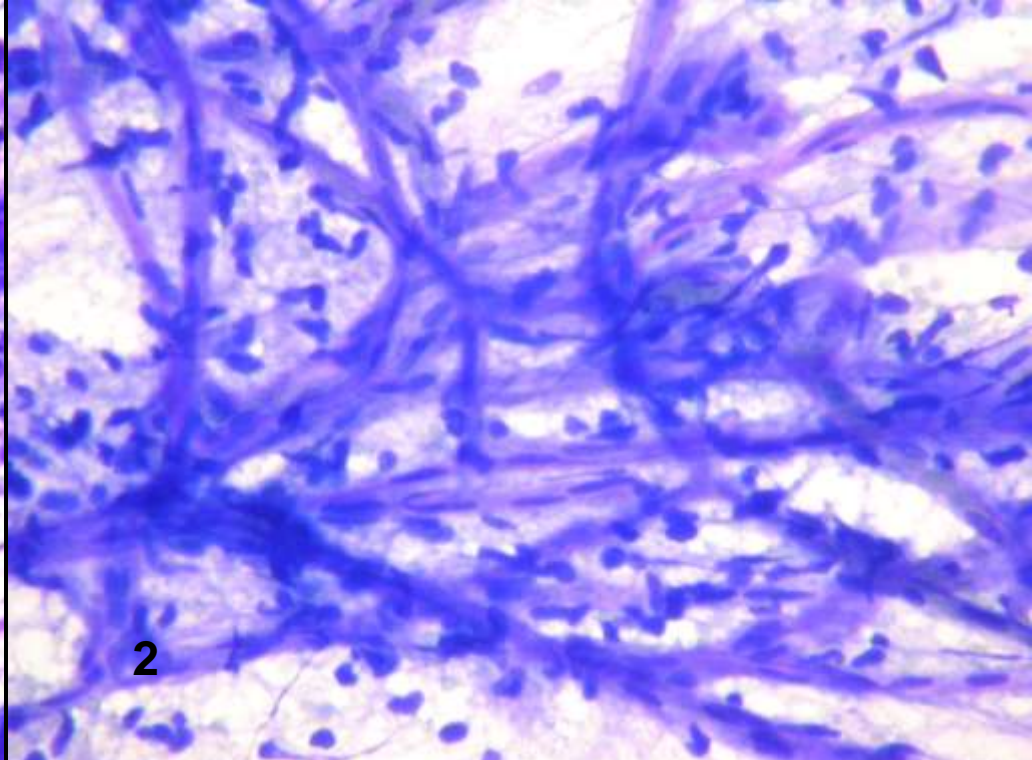
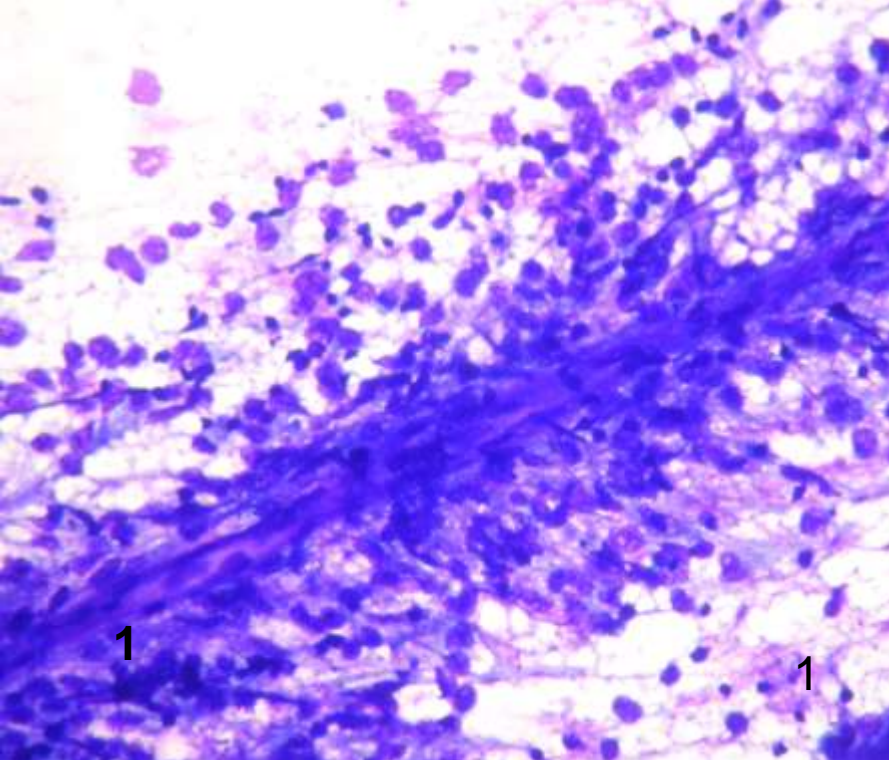
**Glioma**  
**Alto grado**

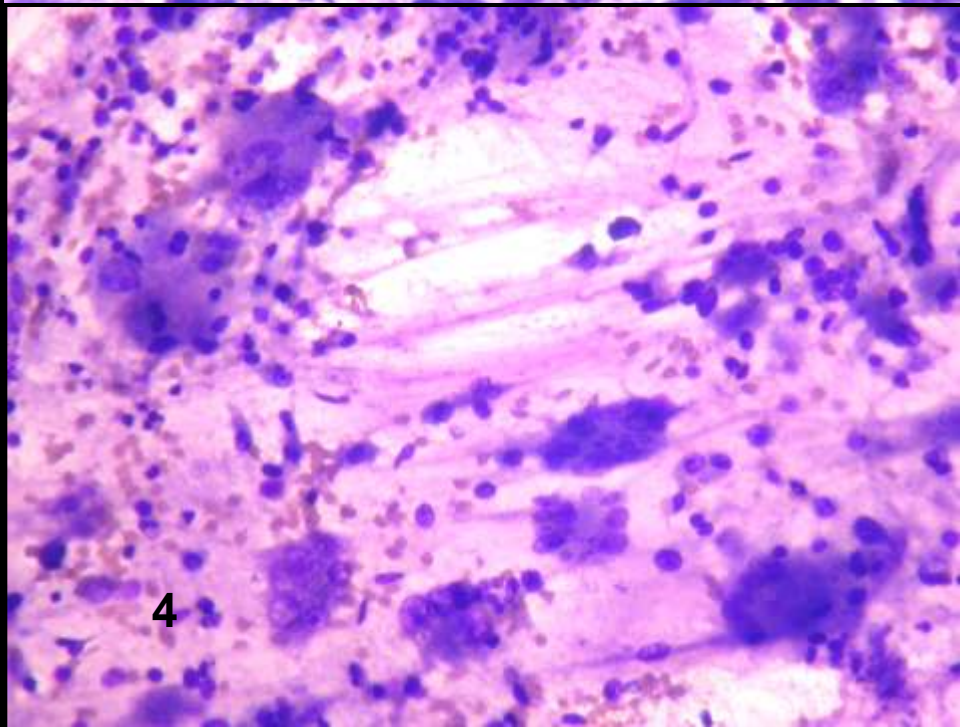
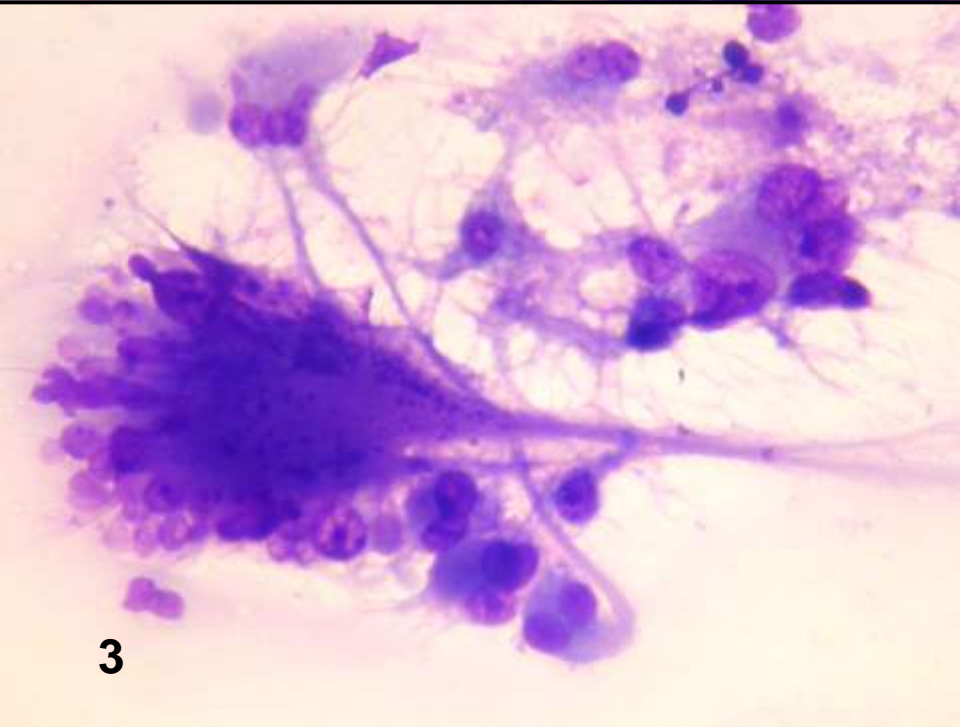
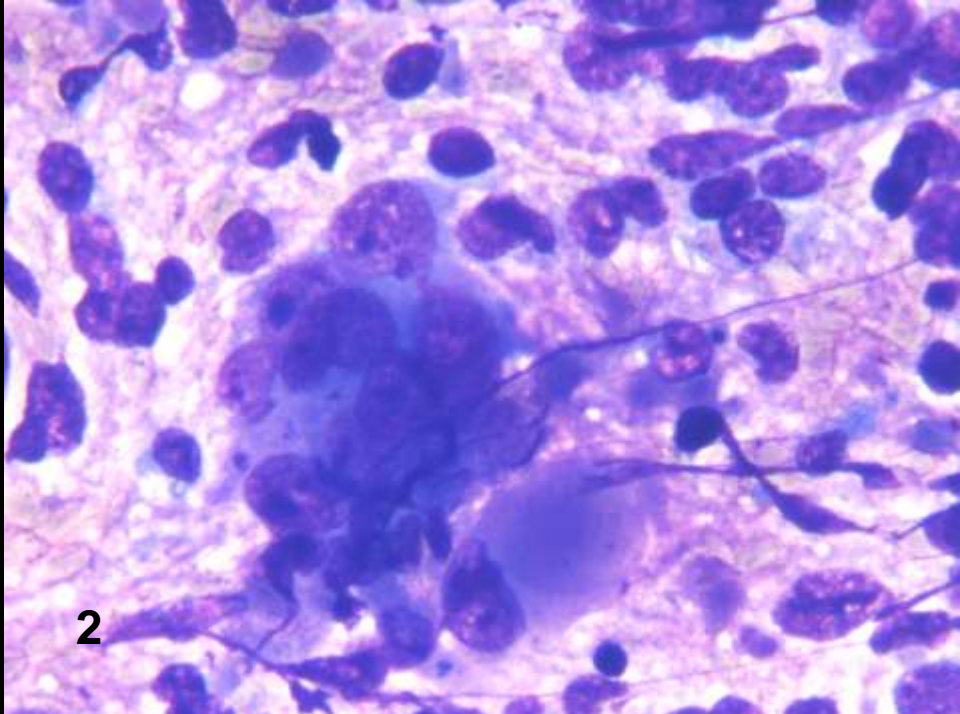
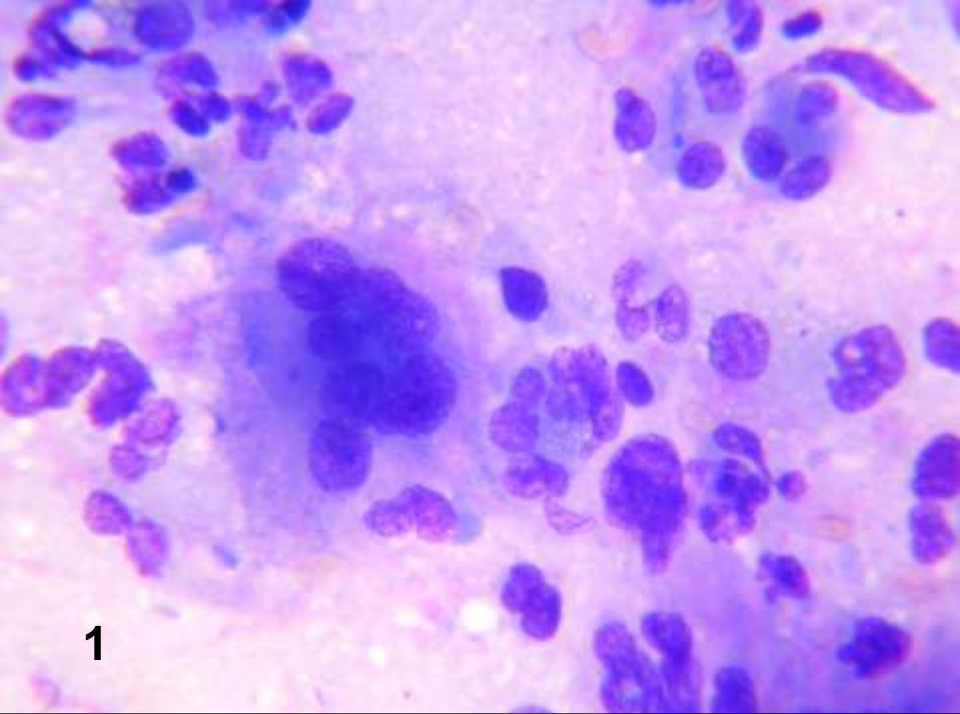


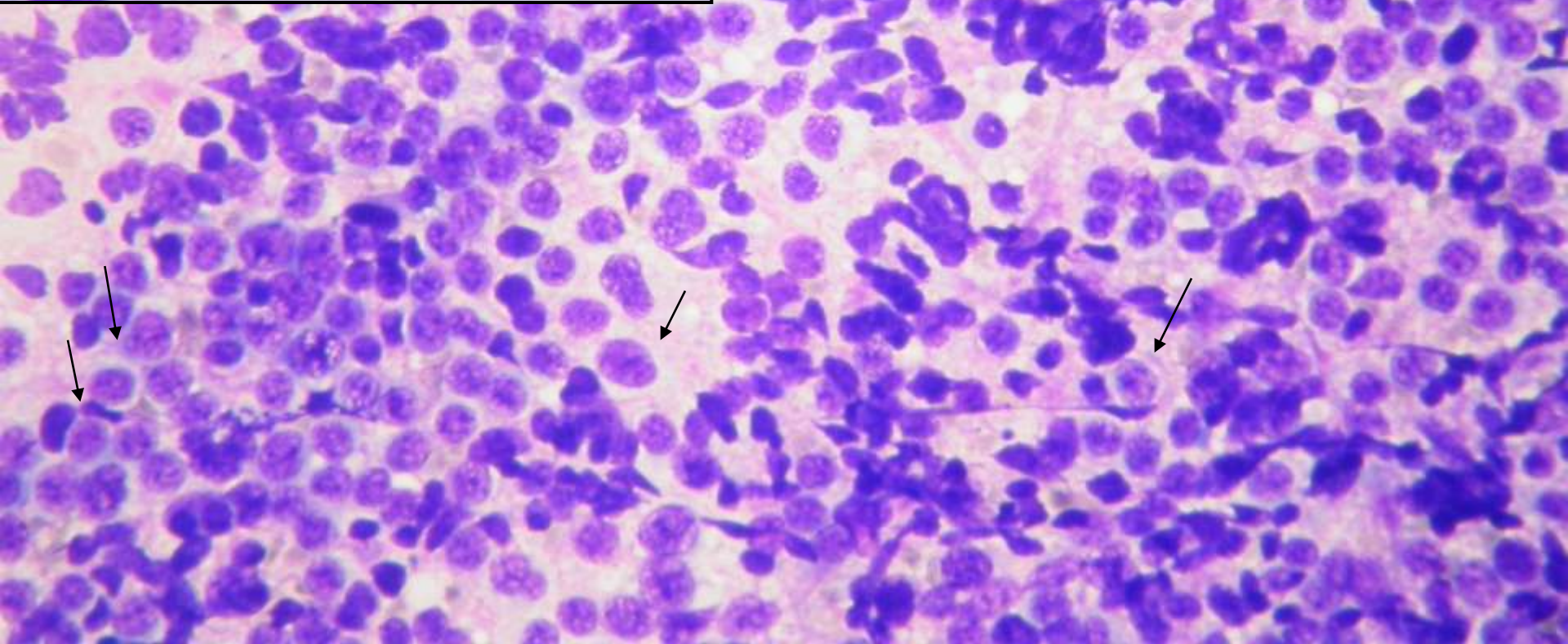
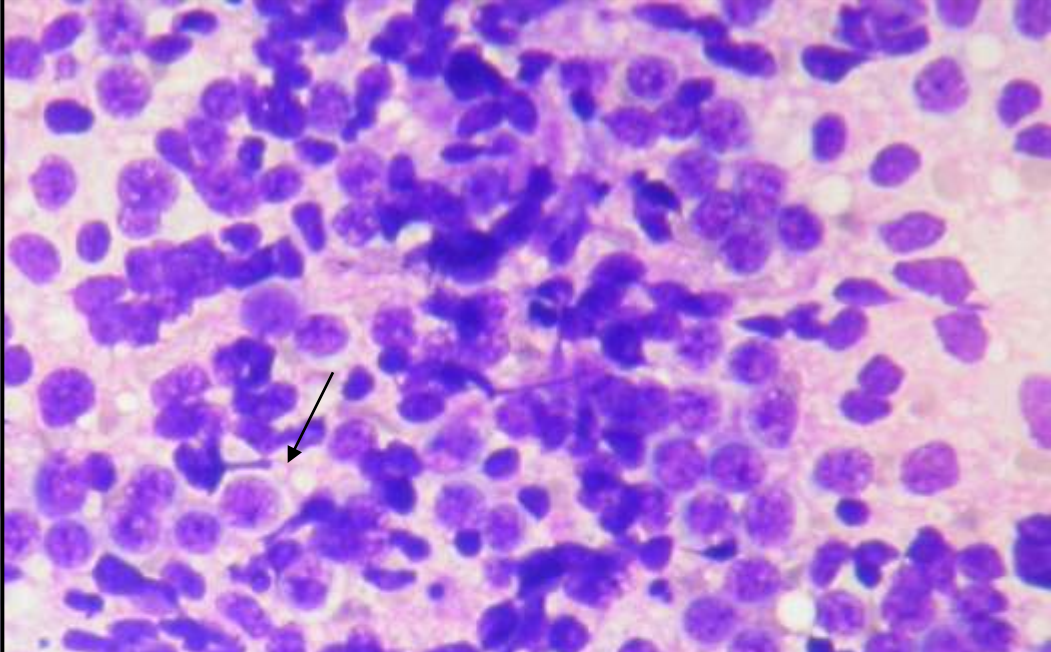
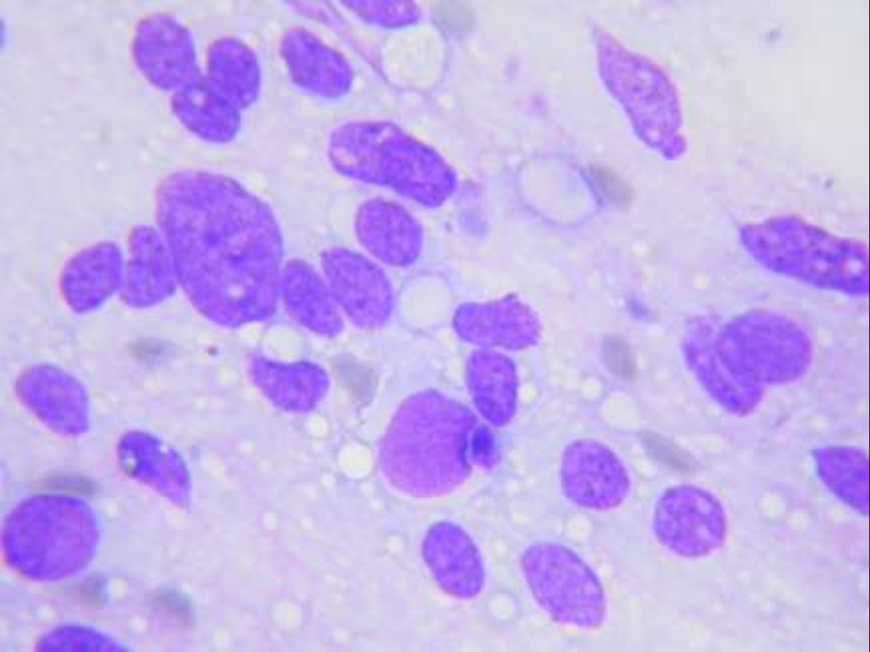


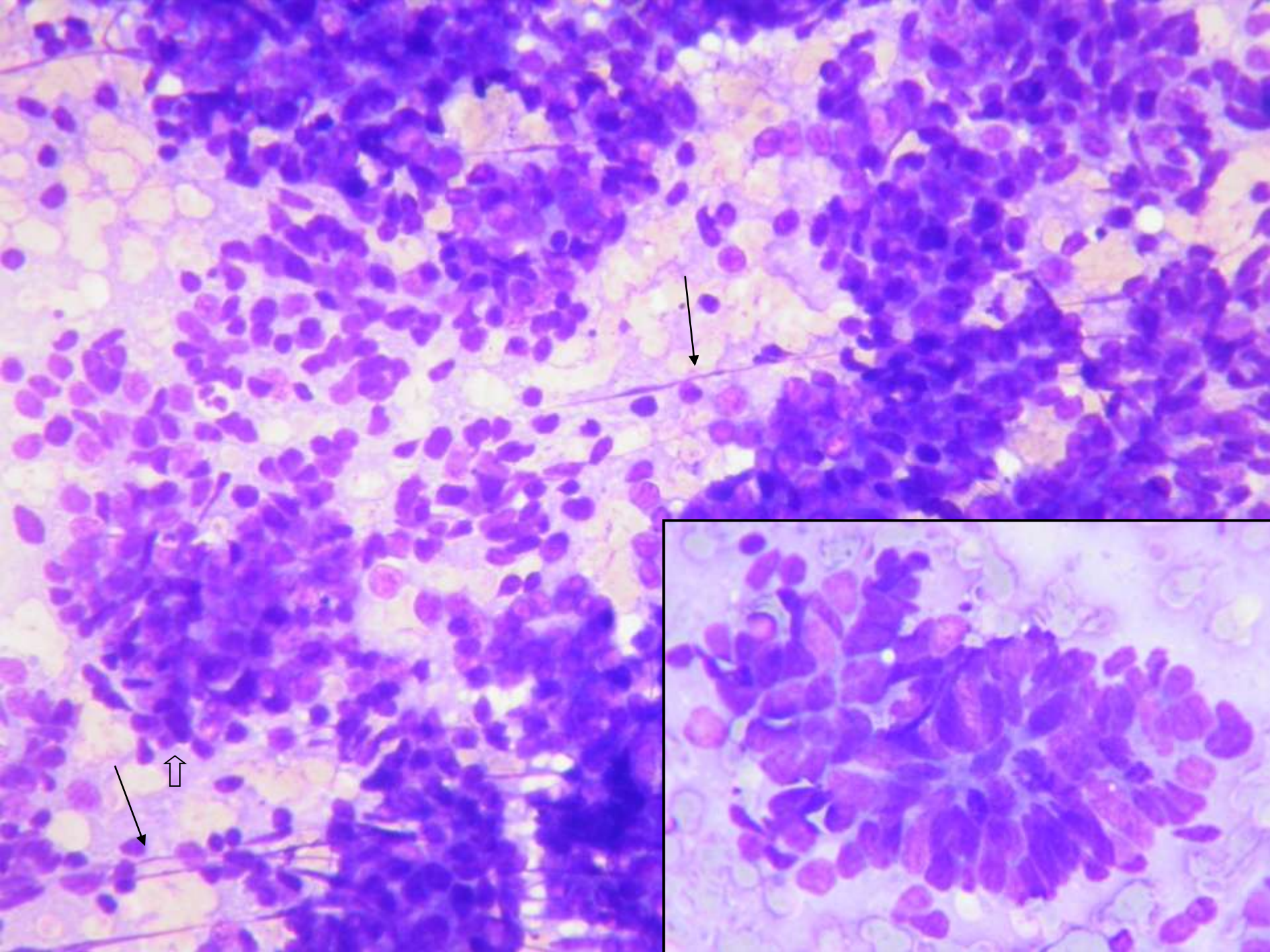




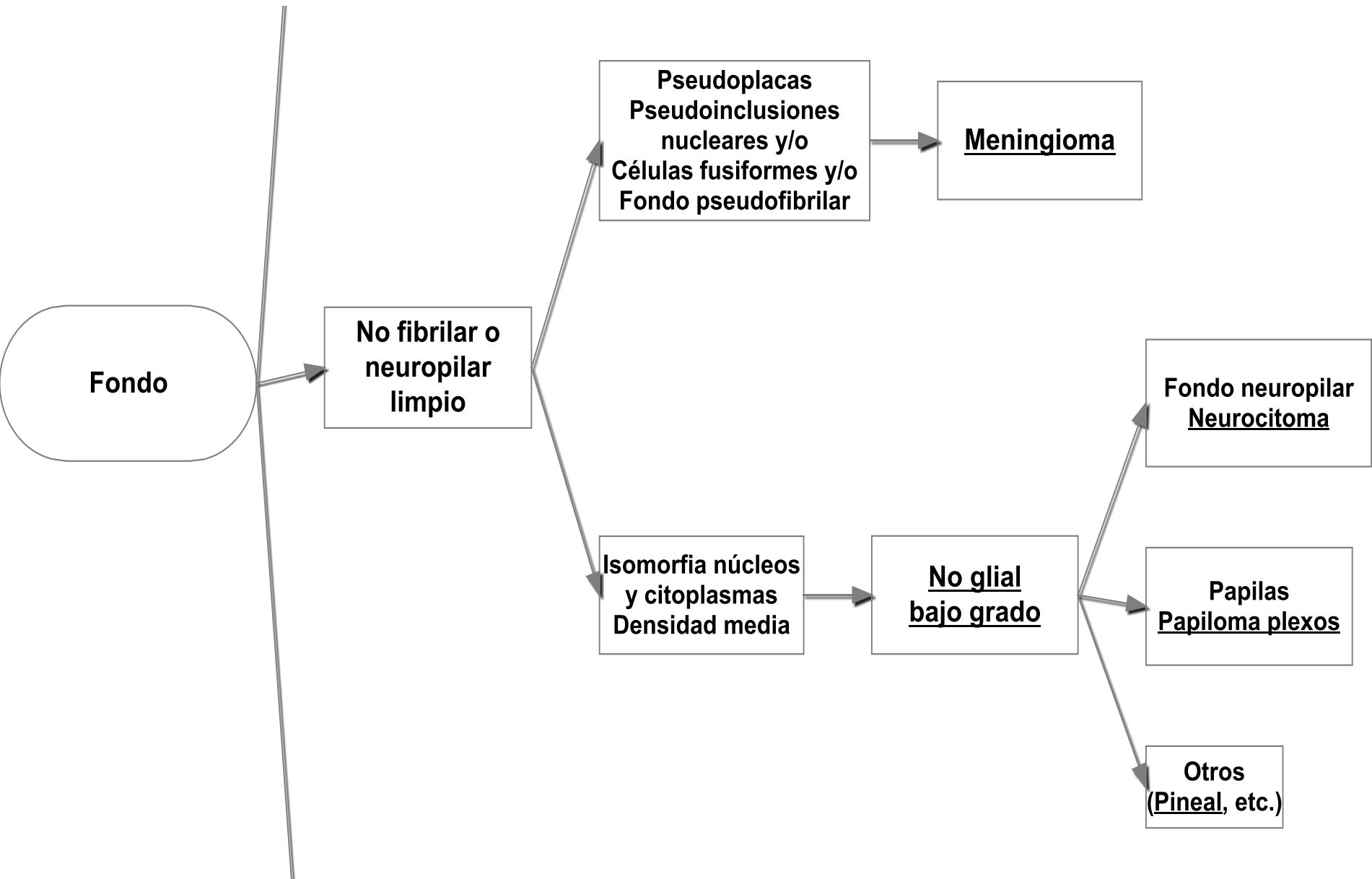












**Fondo**

**No fibrilar o neuropilar limpio**

**Pseudoplasas  
Pseudoinclusiones nucleares y/o  
Células fusiformes y/o  
Fondo pseudofibrilar**

**Meningioma**

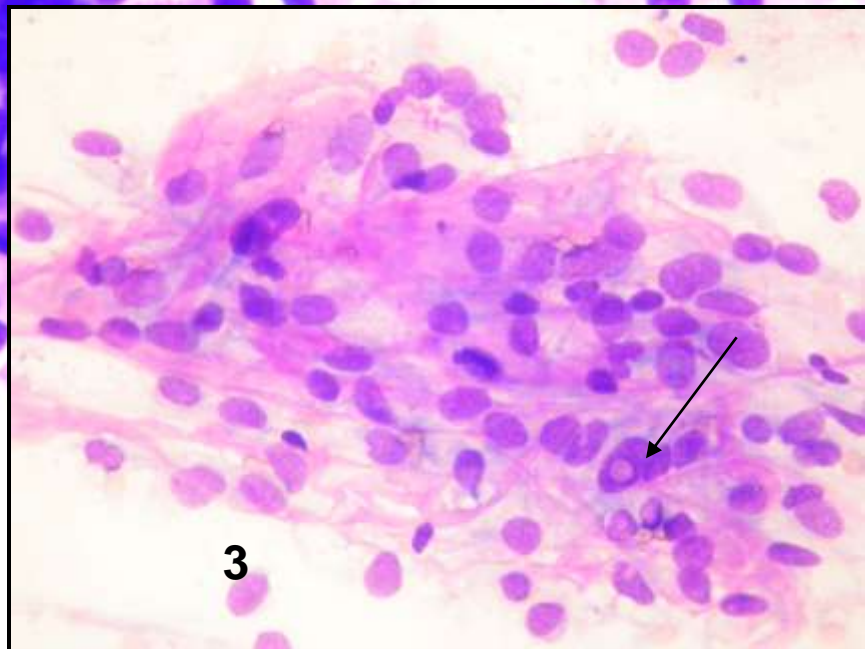
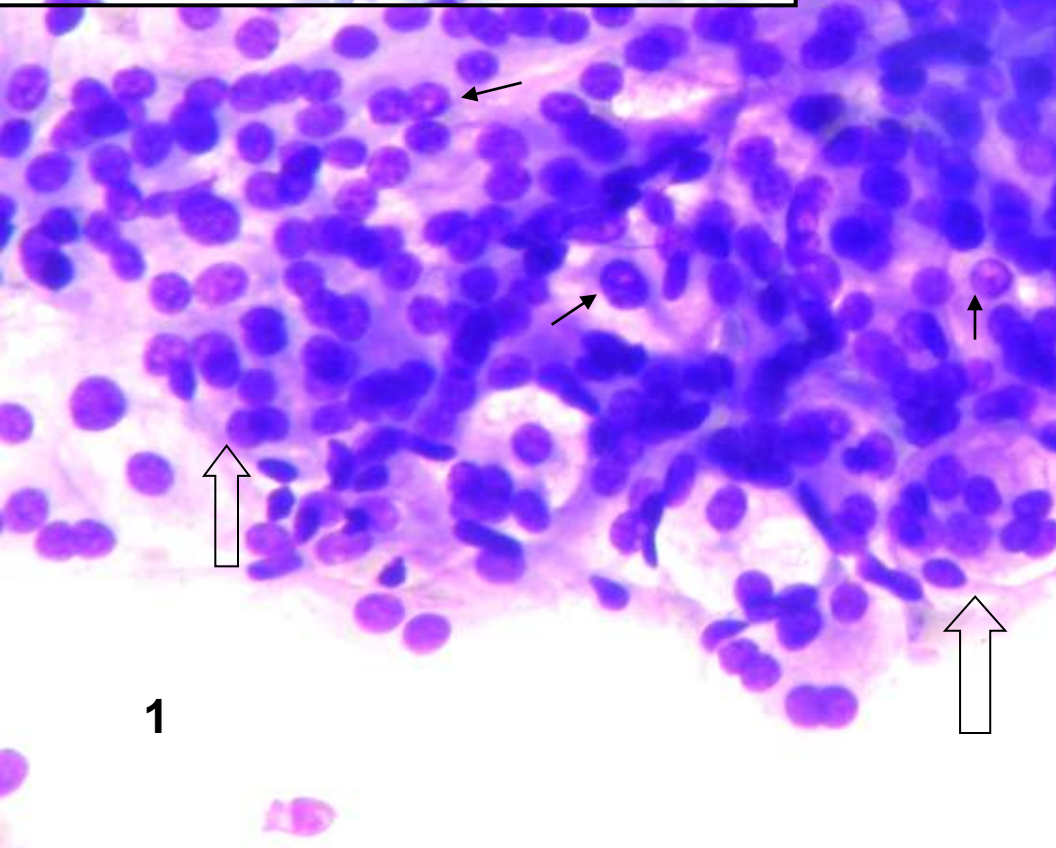
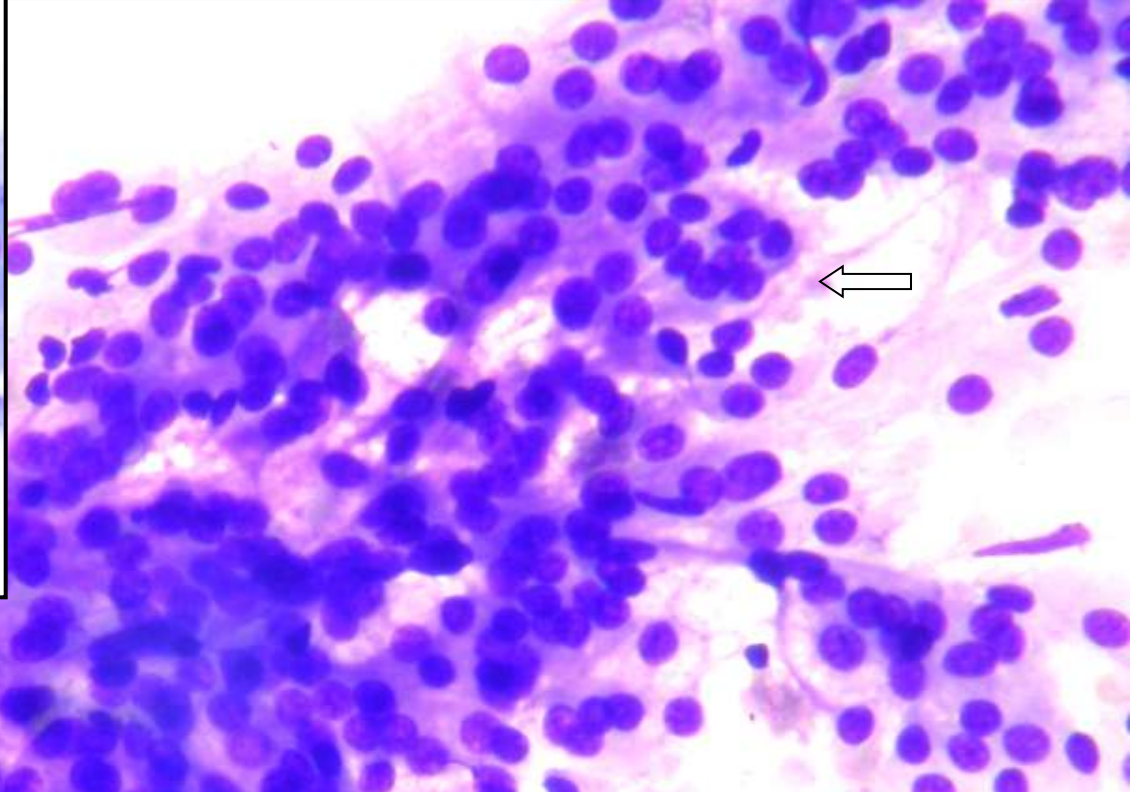
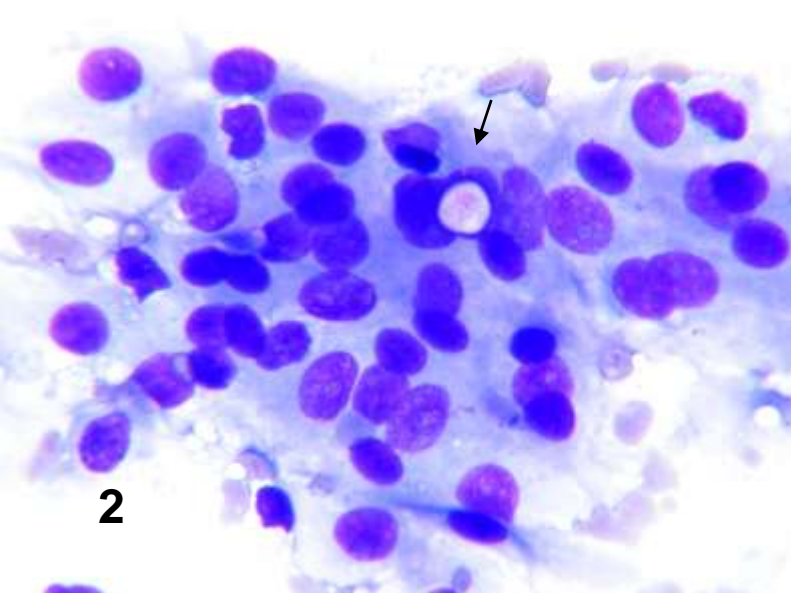
**Isomorfia núcleos y citoplasmas  
Densidad media**

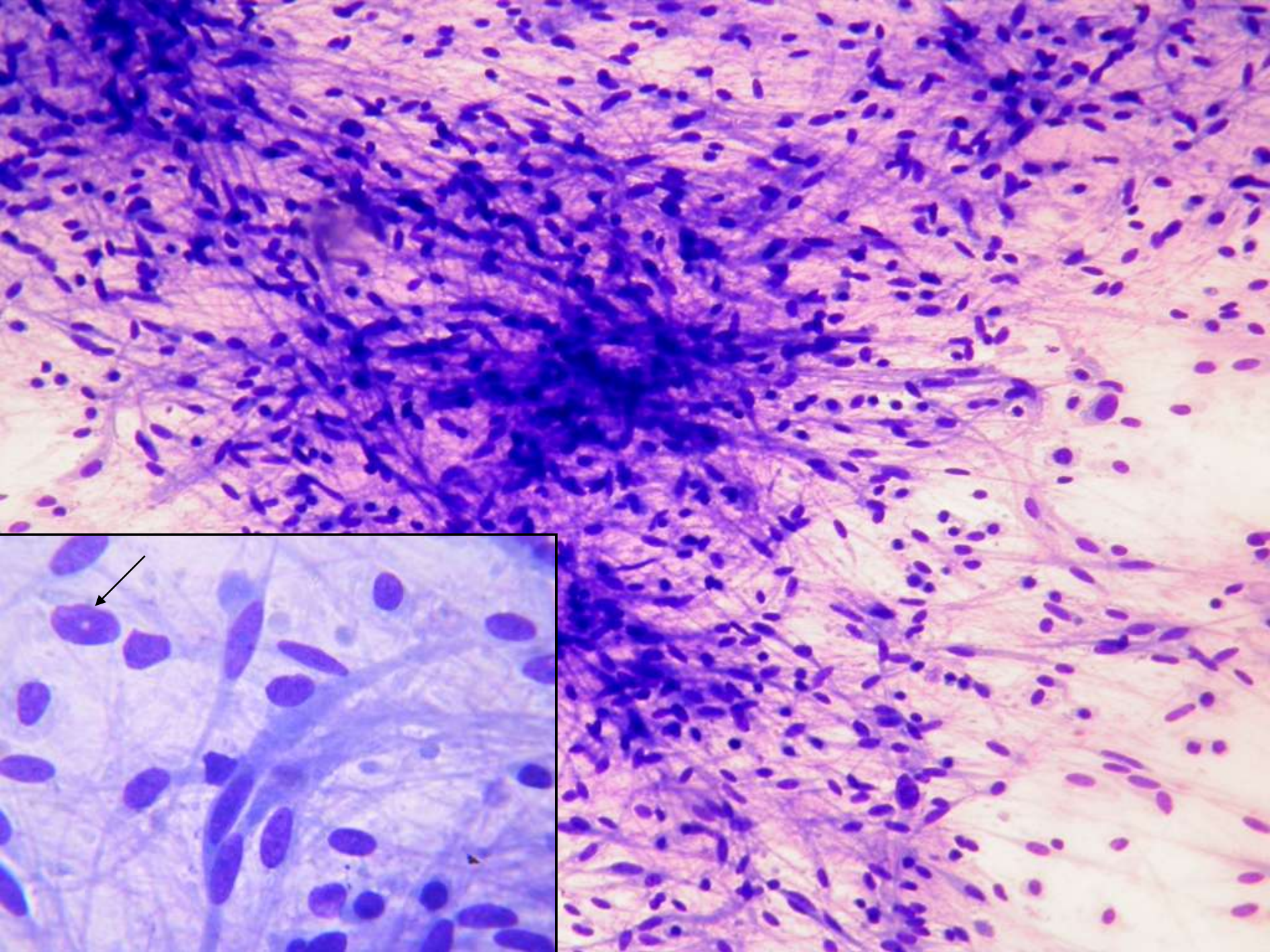
**No glial bajo grado**

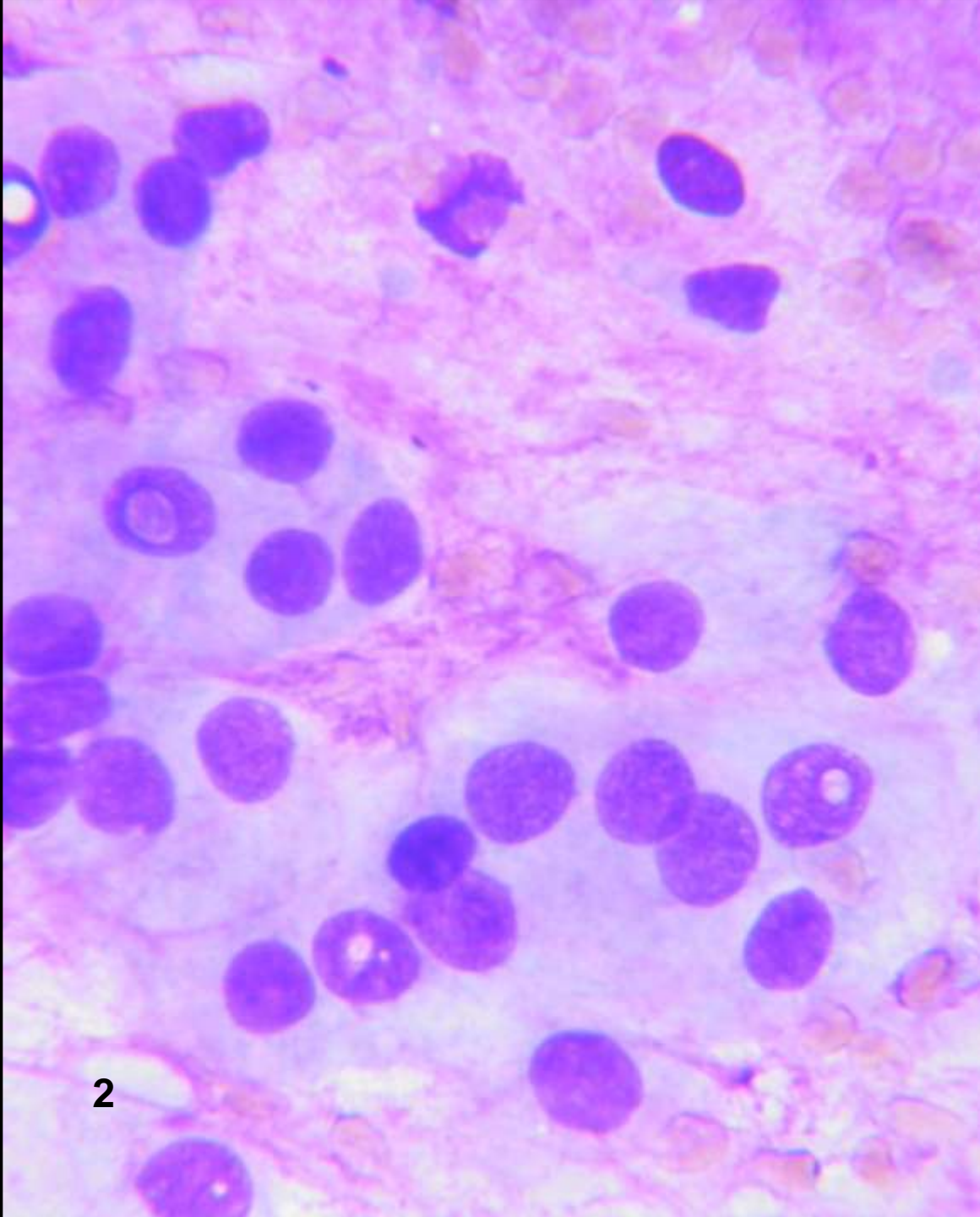
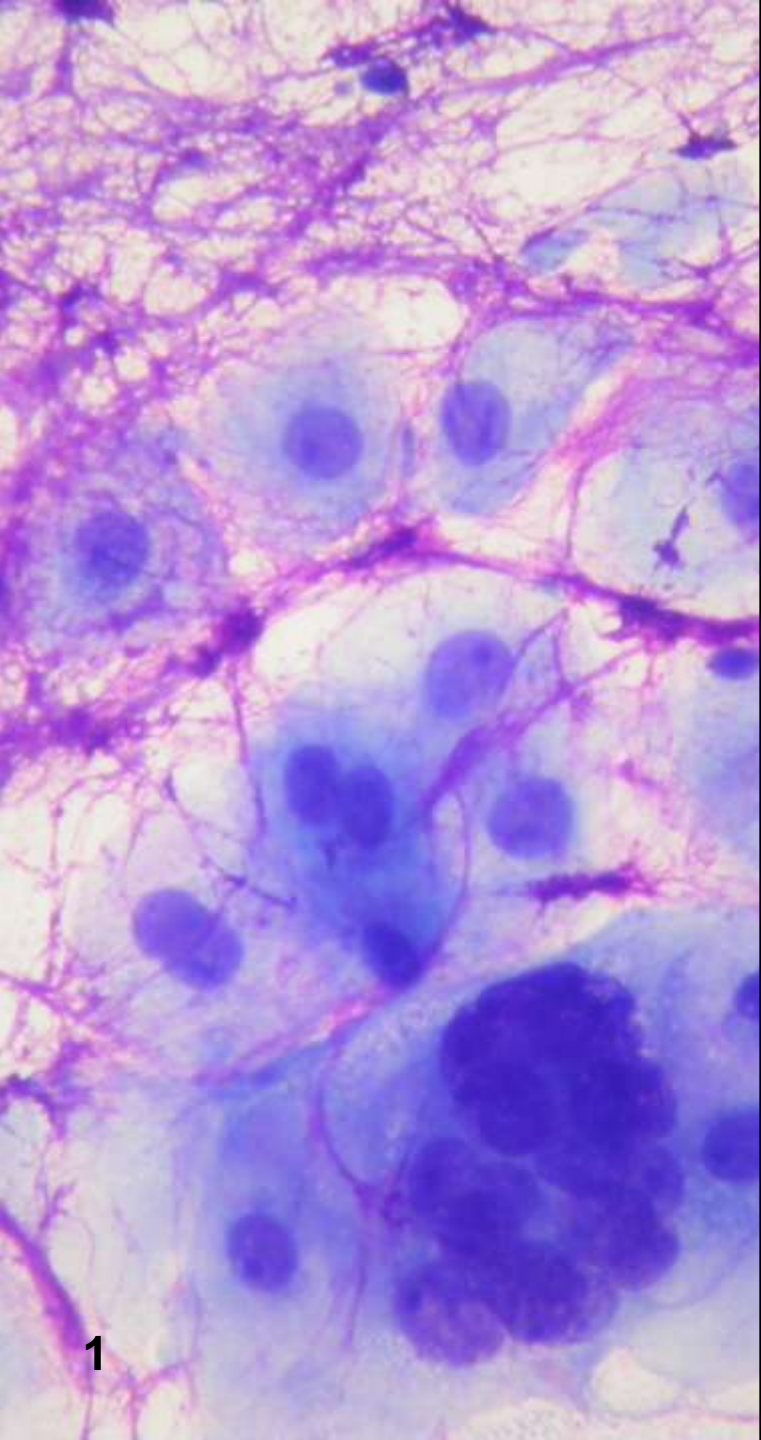
**Fondo neuropilar  
Neurocitoma**

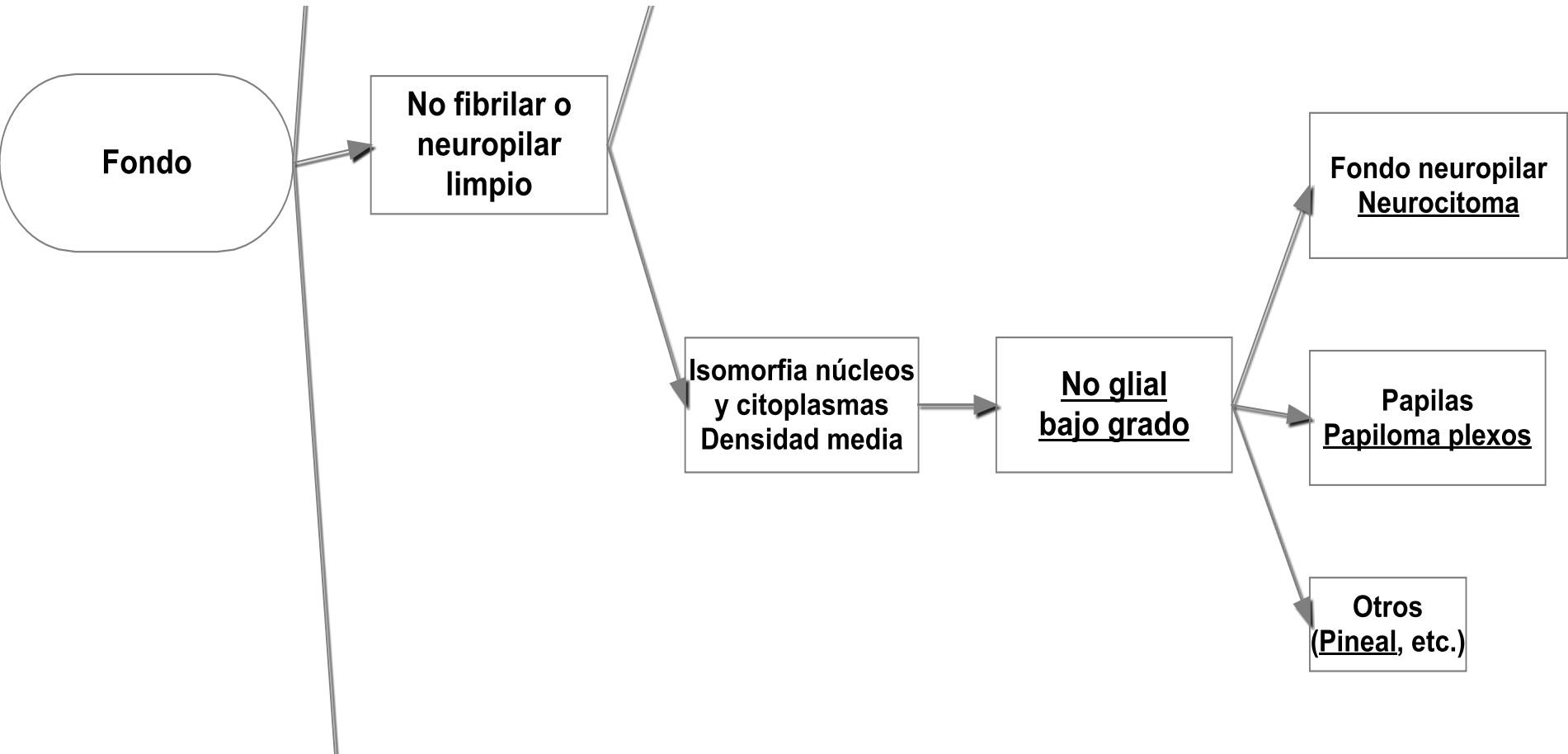
**Papilas  
Papiloma plexos**

**Otros  
(Pineal, etc.)**









**Fondo**

**No fibrilar o neuropilar limpio**

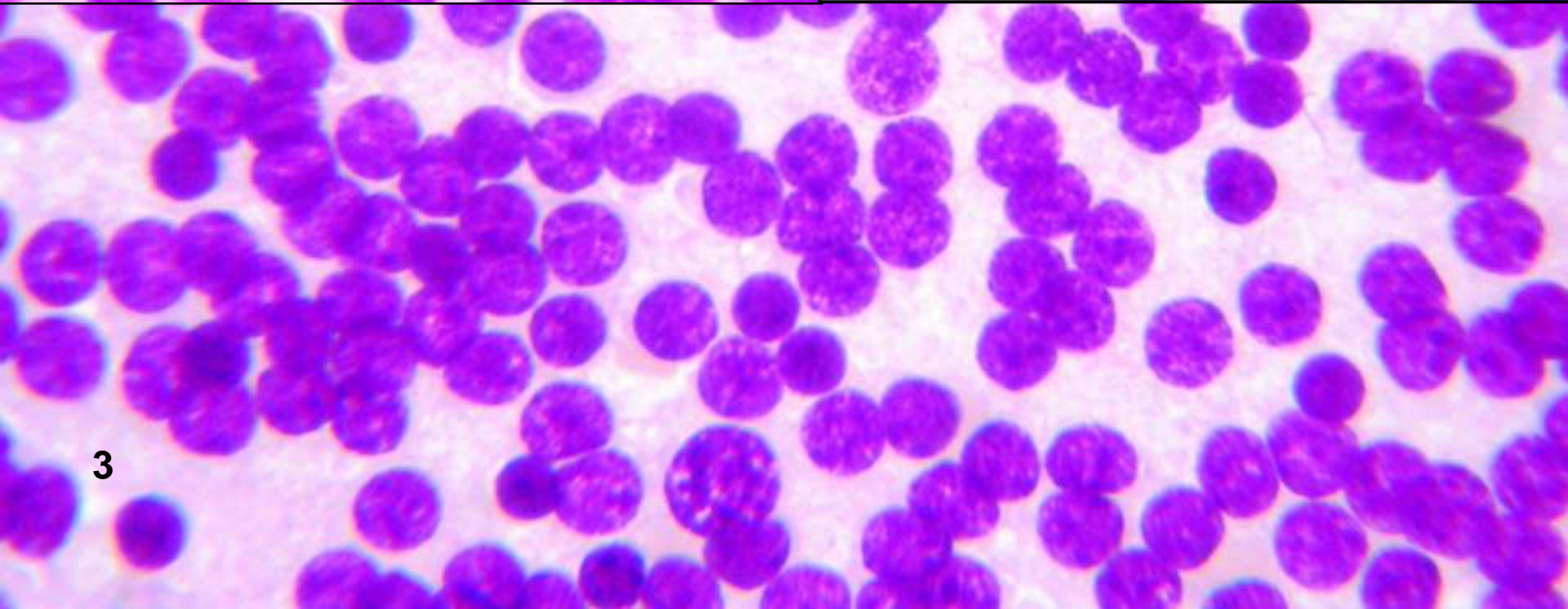
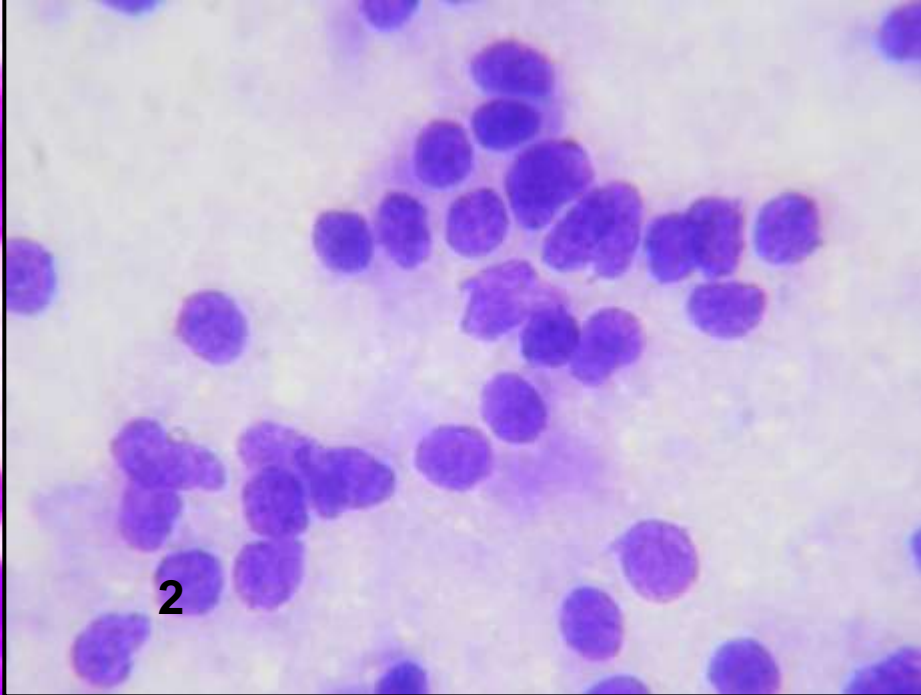
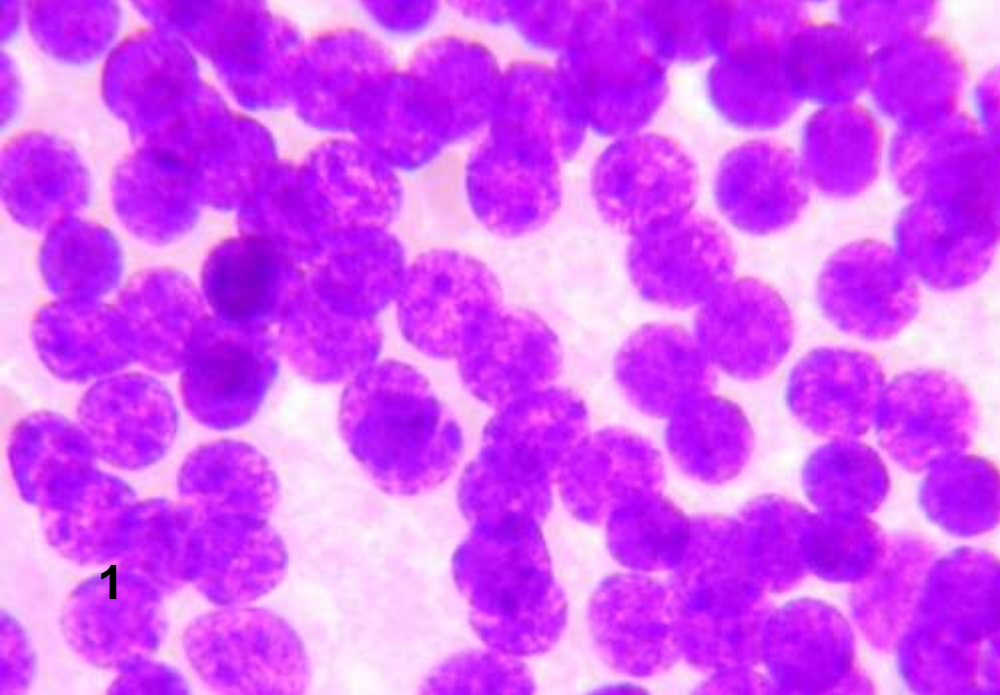
**Isomorfia núcleos y citoplasmas  
Densidad media**

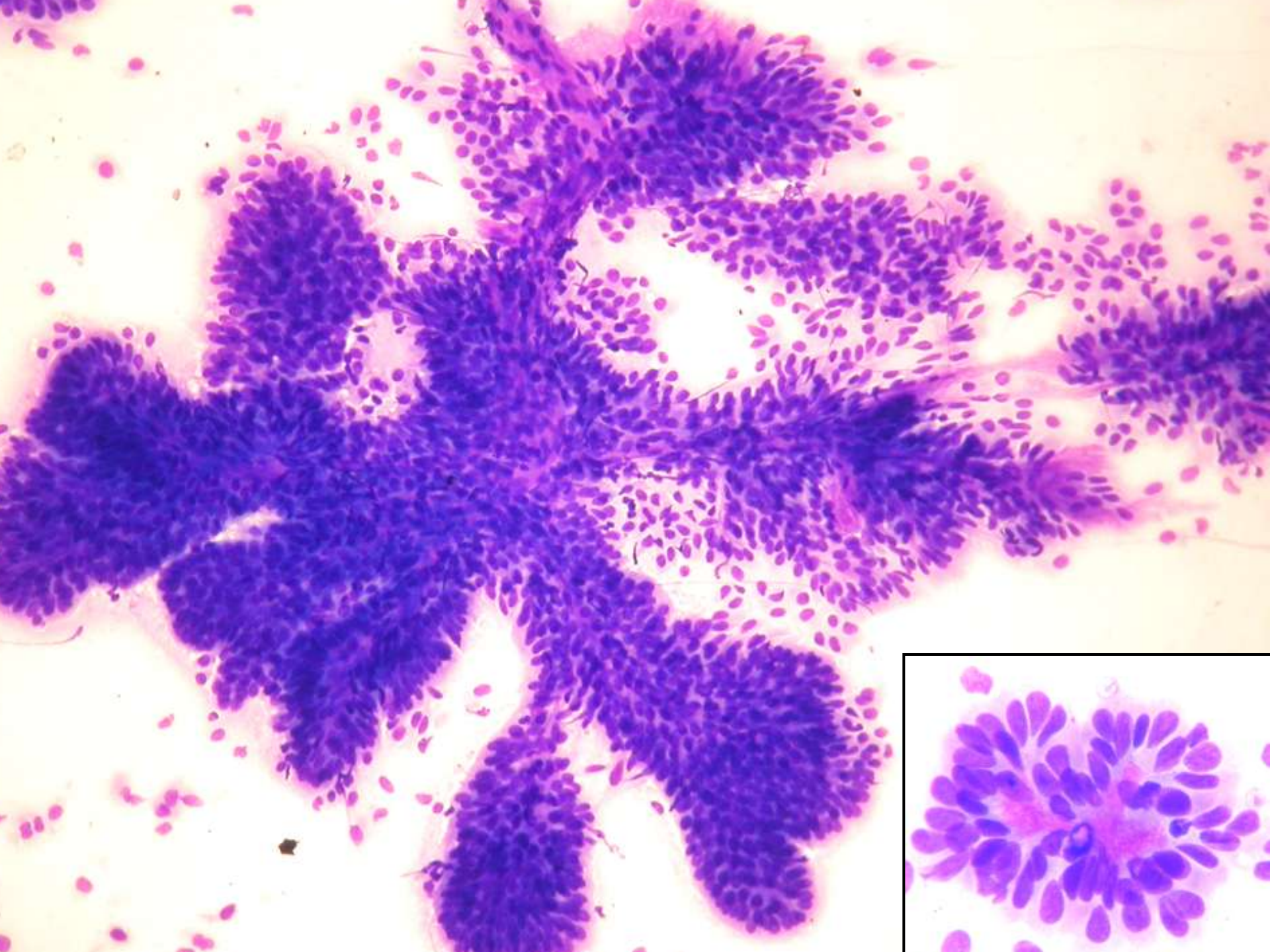
**No glial  
bajo grado**

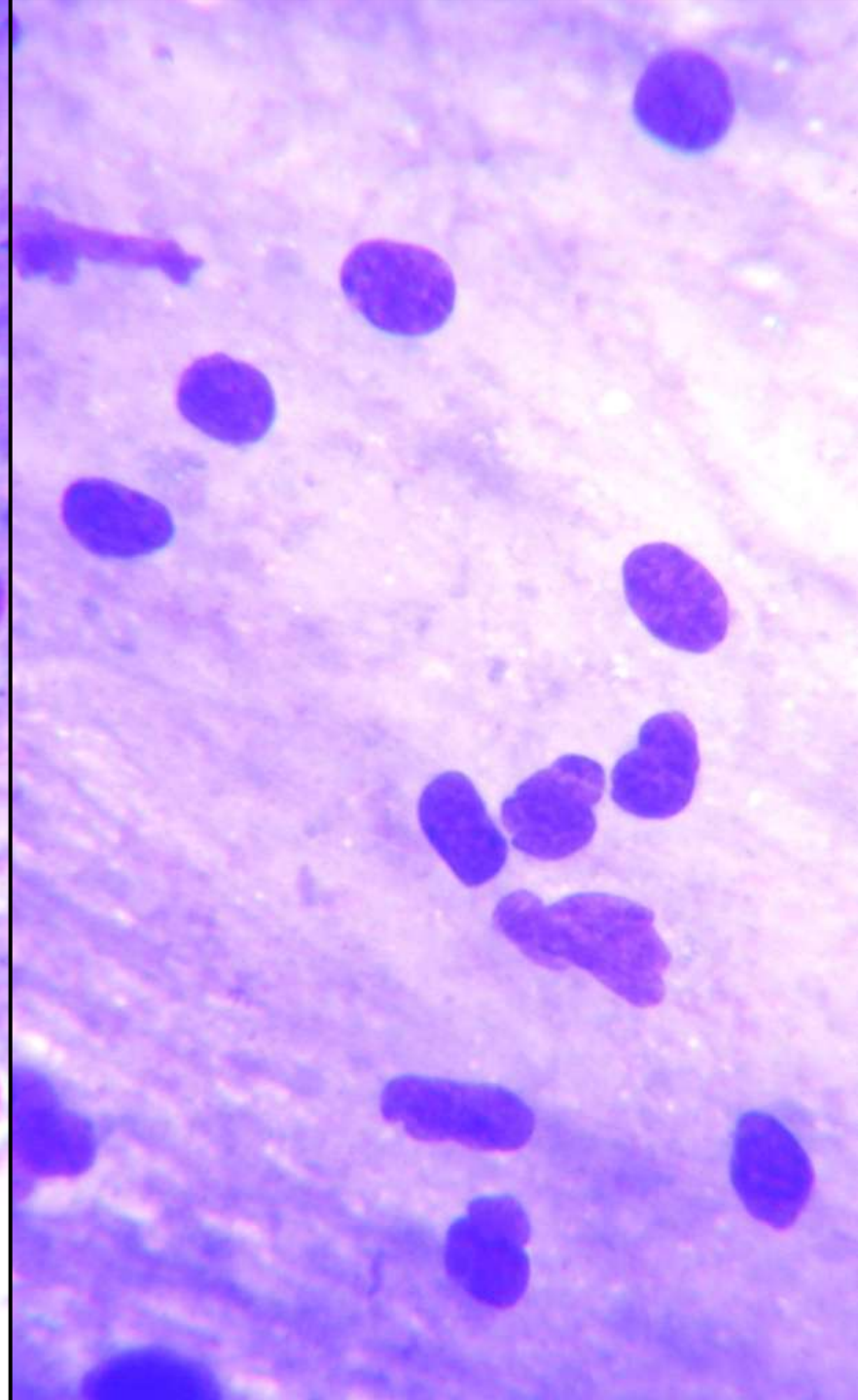
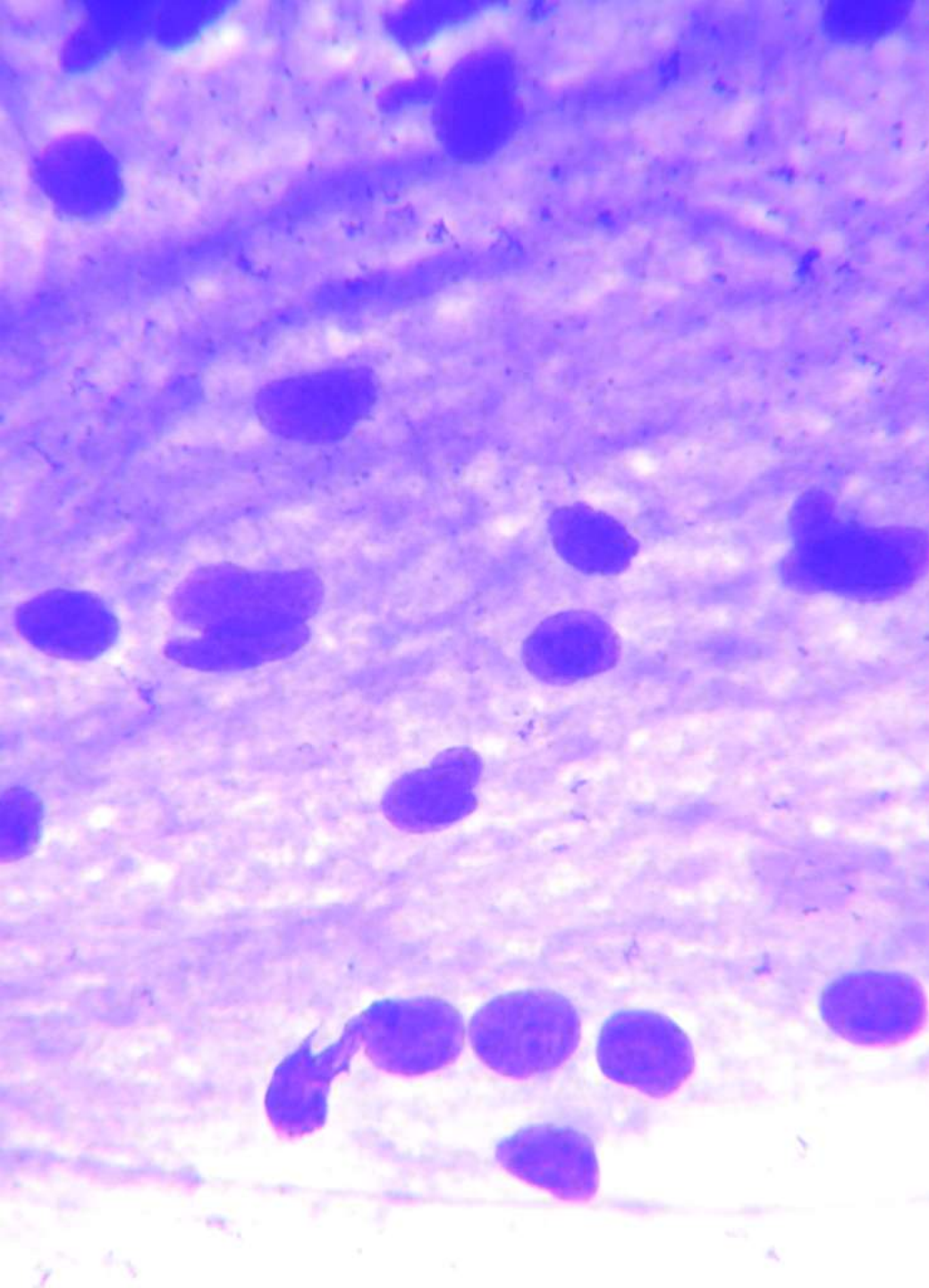
**Fondo neuropilar  
Neurocitoma**

**Papilas  
Papiloma plexos**

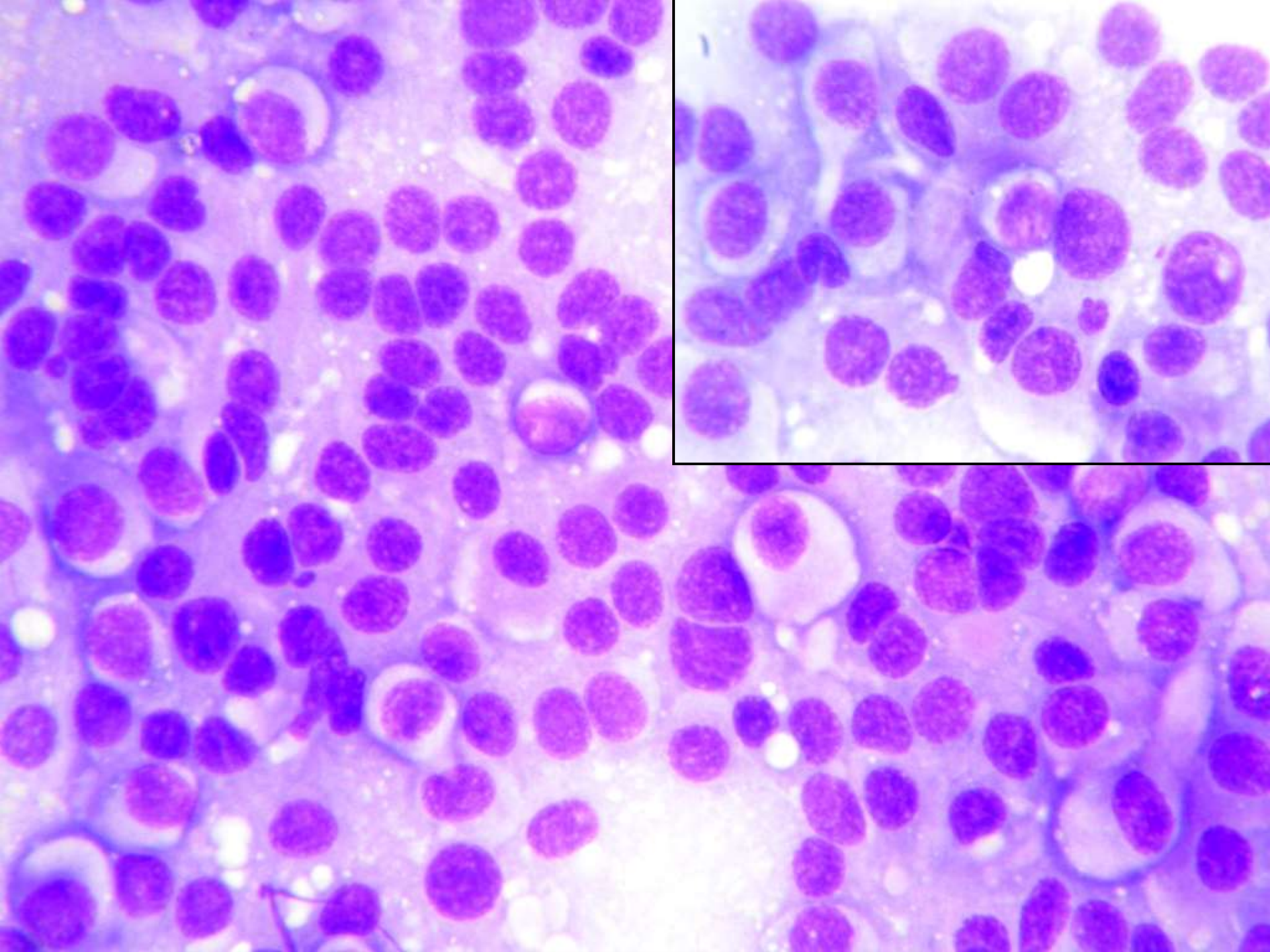
**Otros  
(Pineal, etc.)**

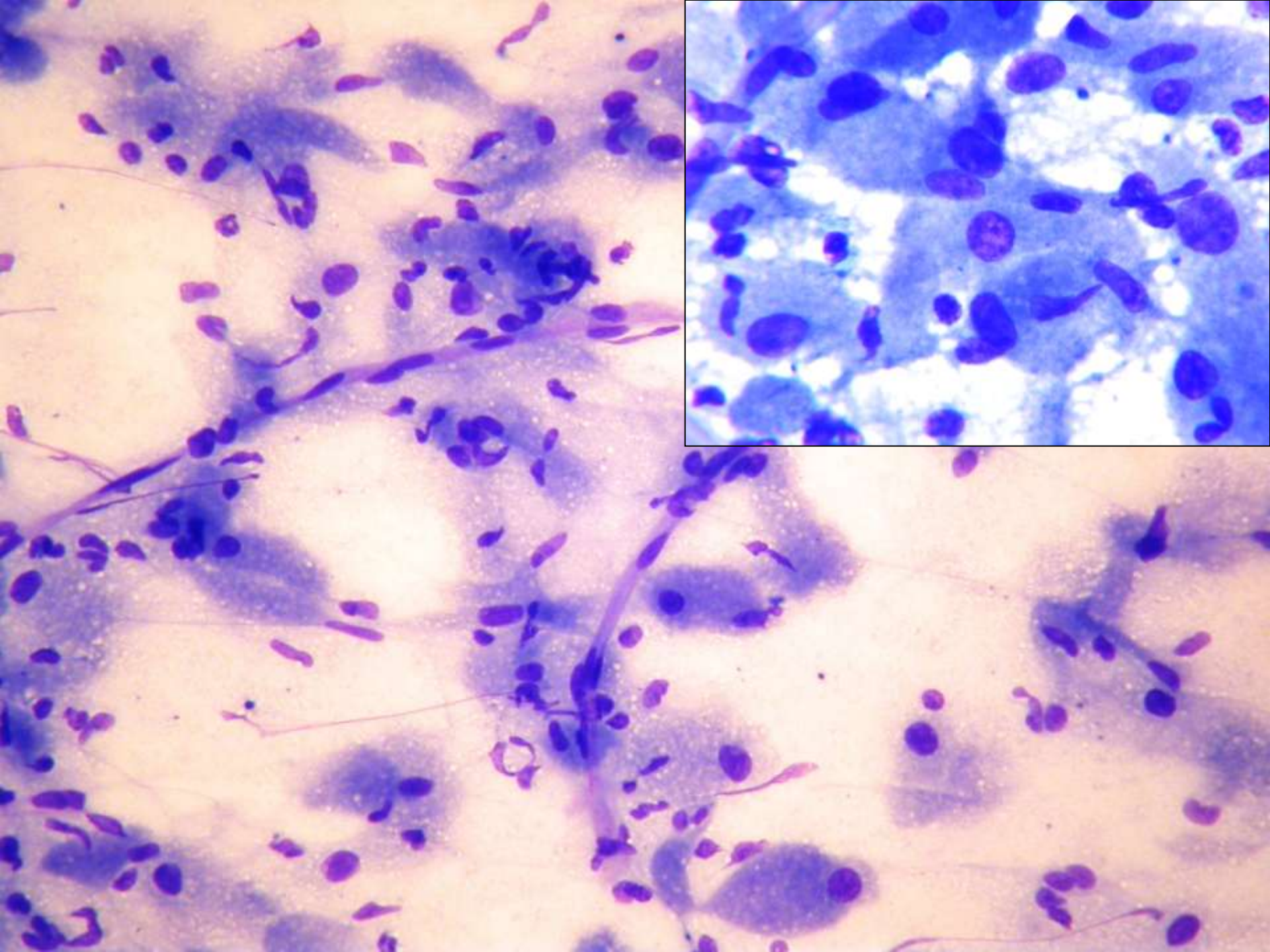


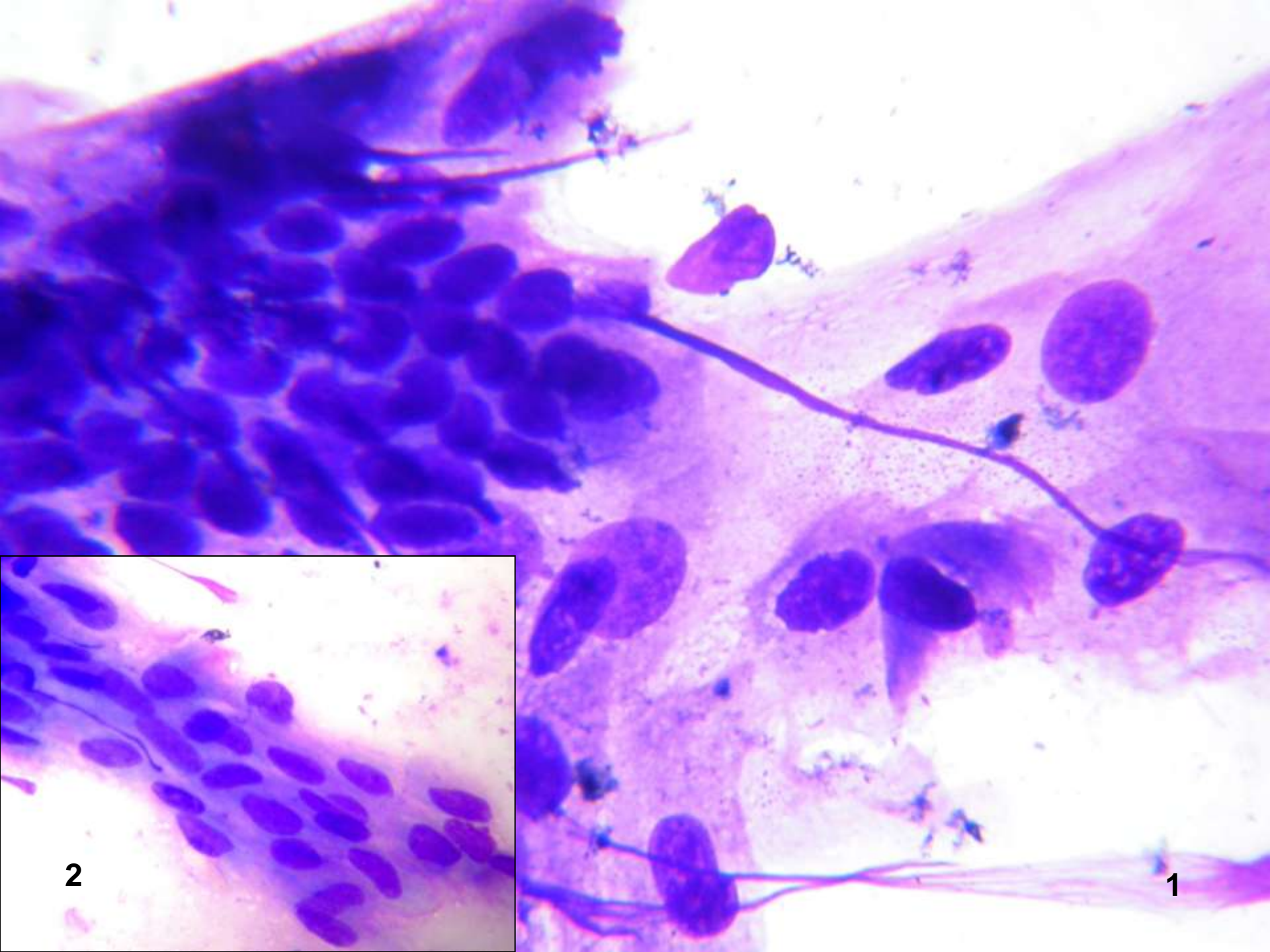






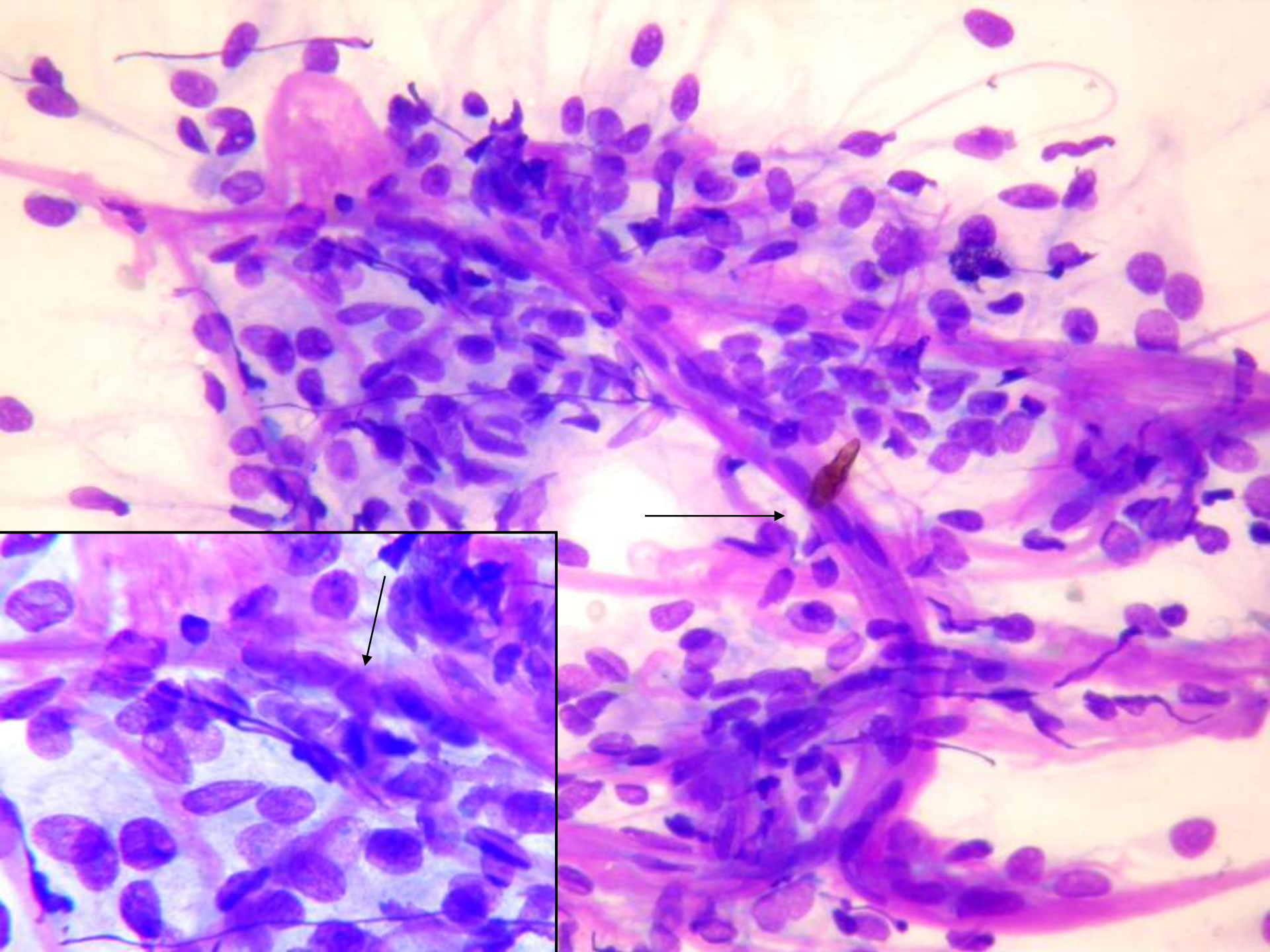


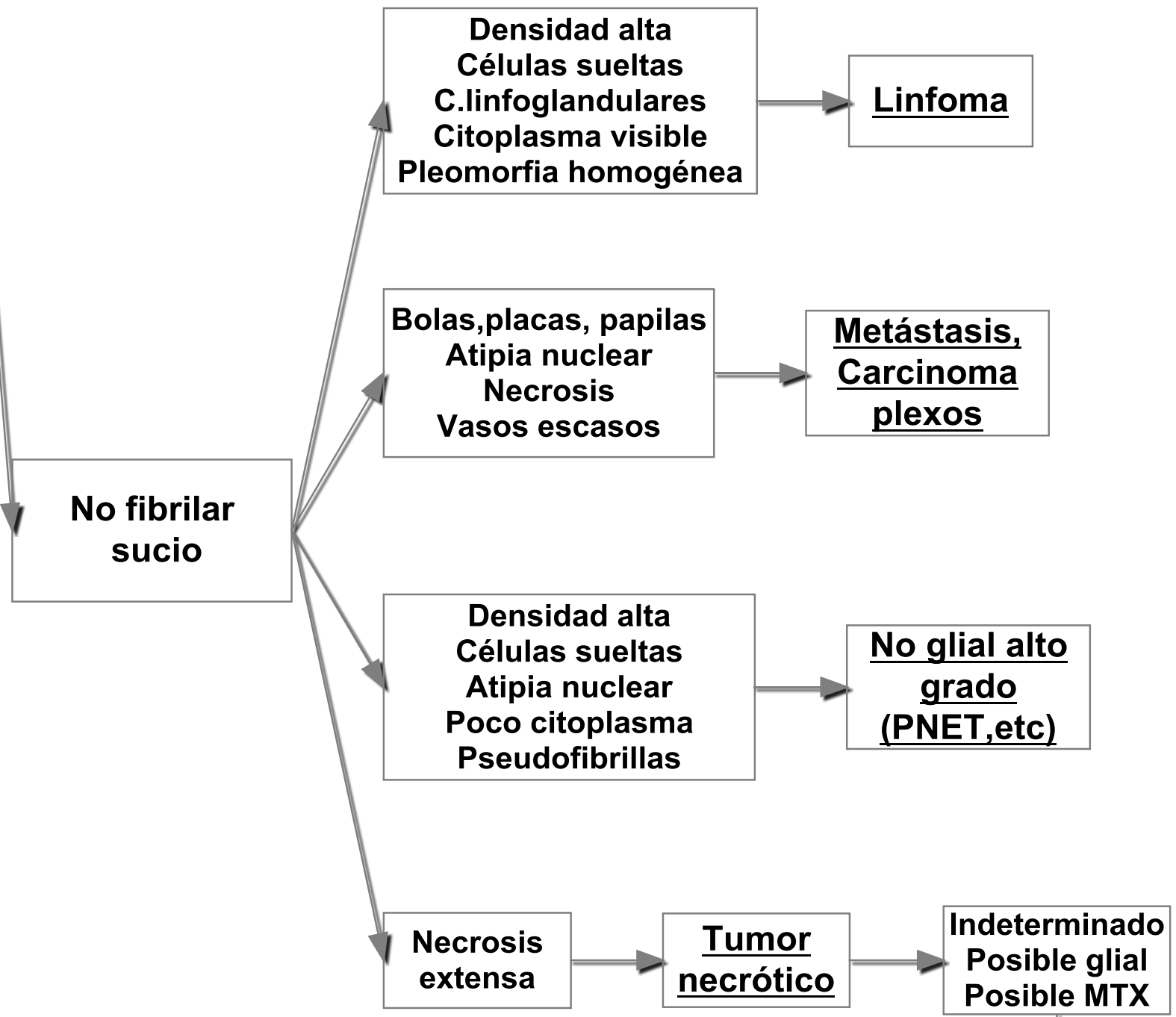


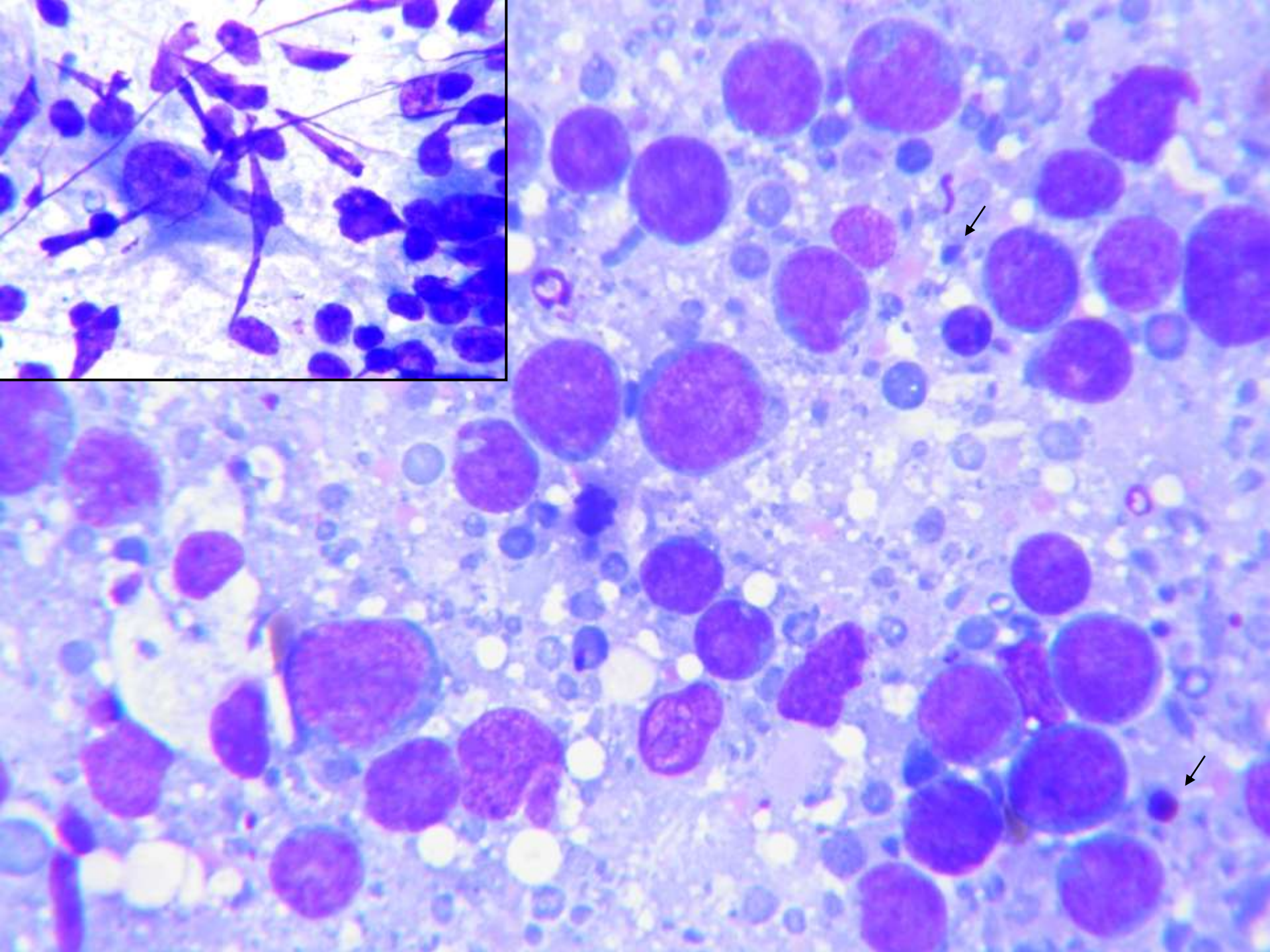
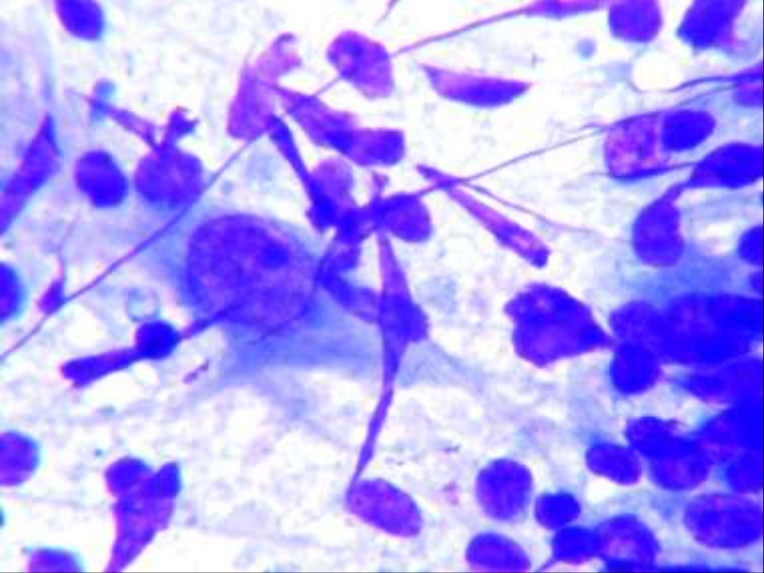


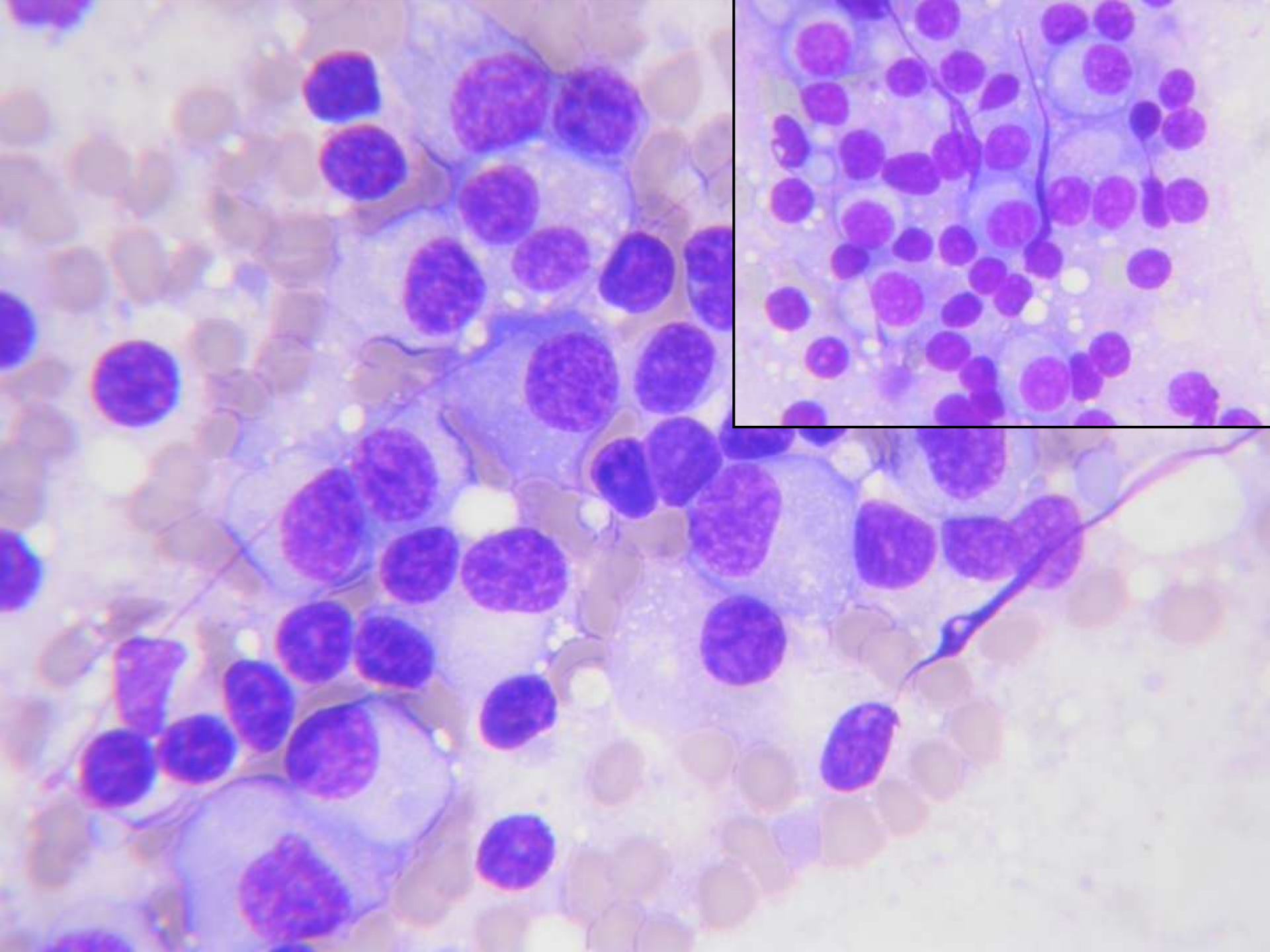
2

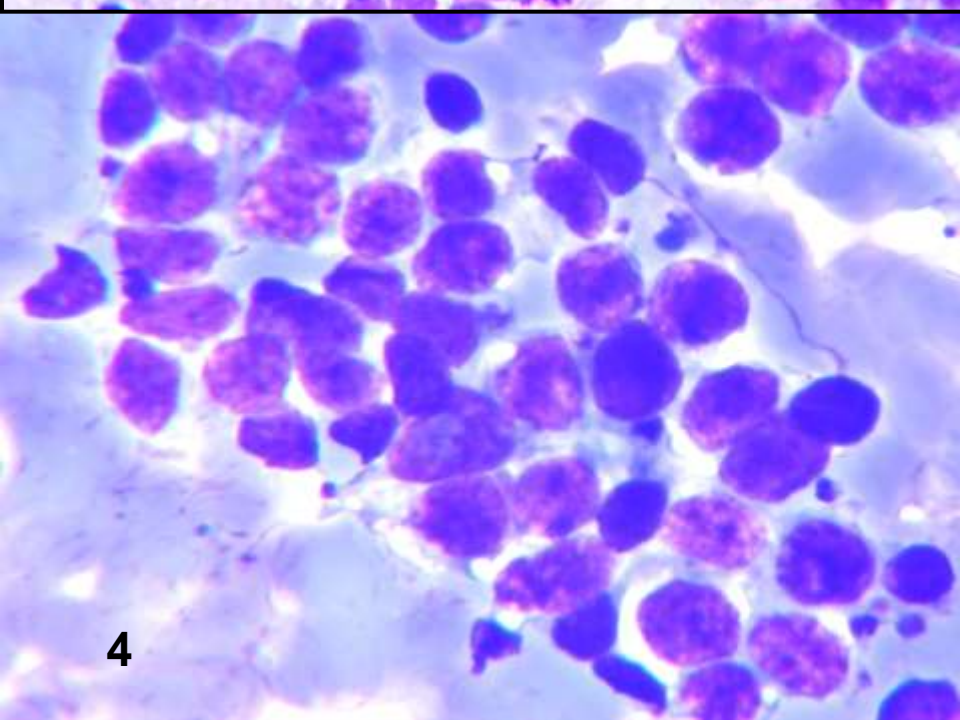
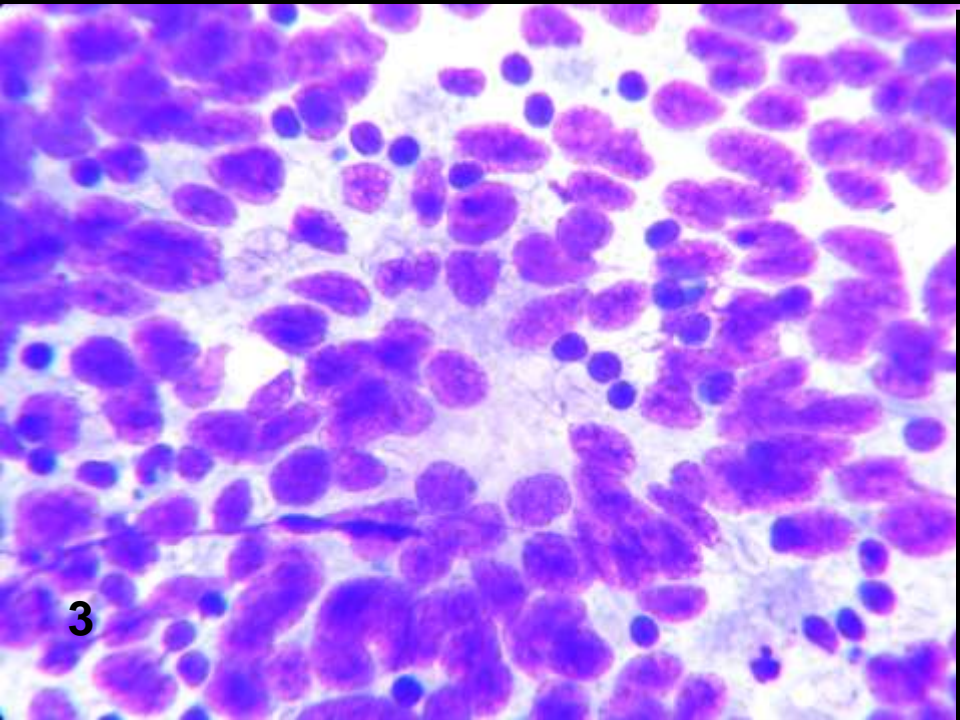
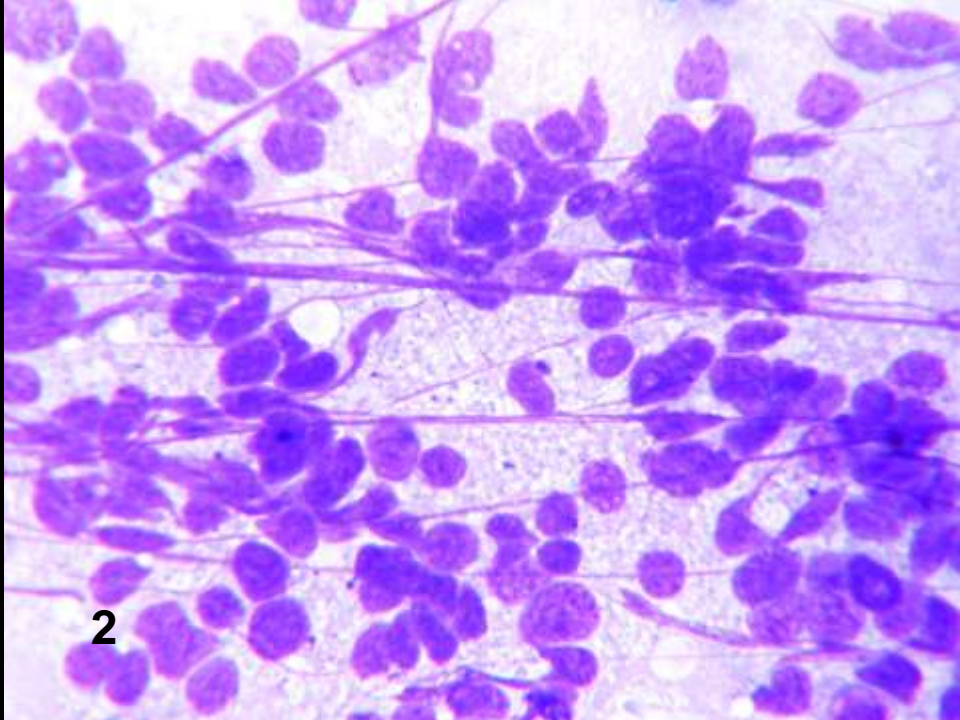
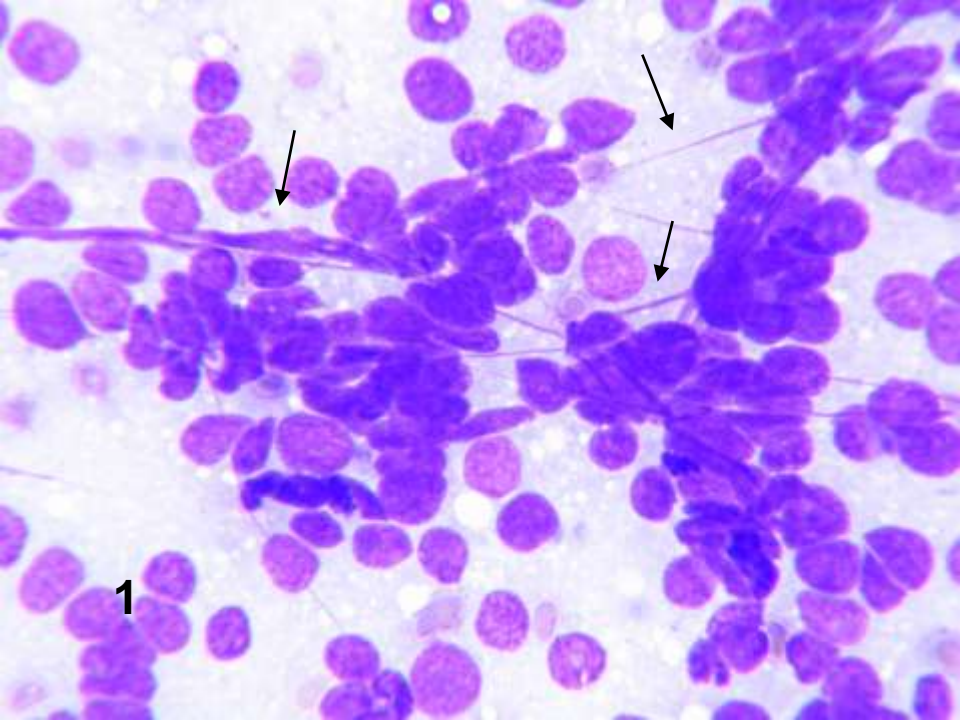
1



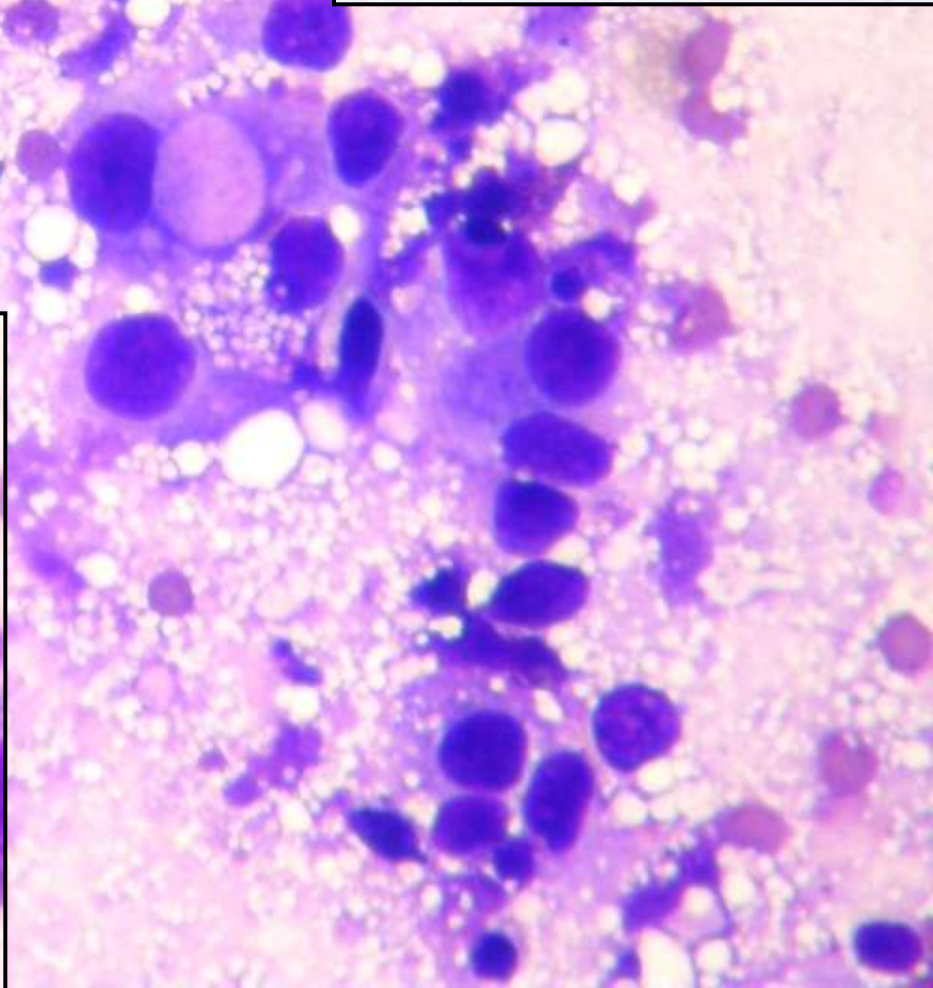
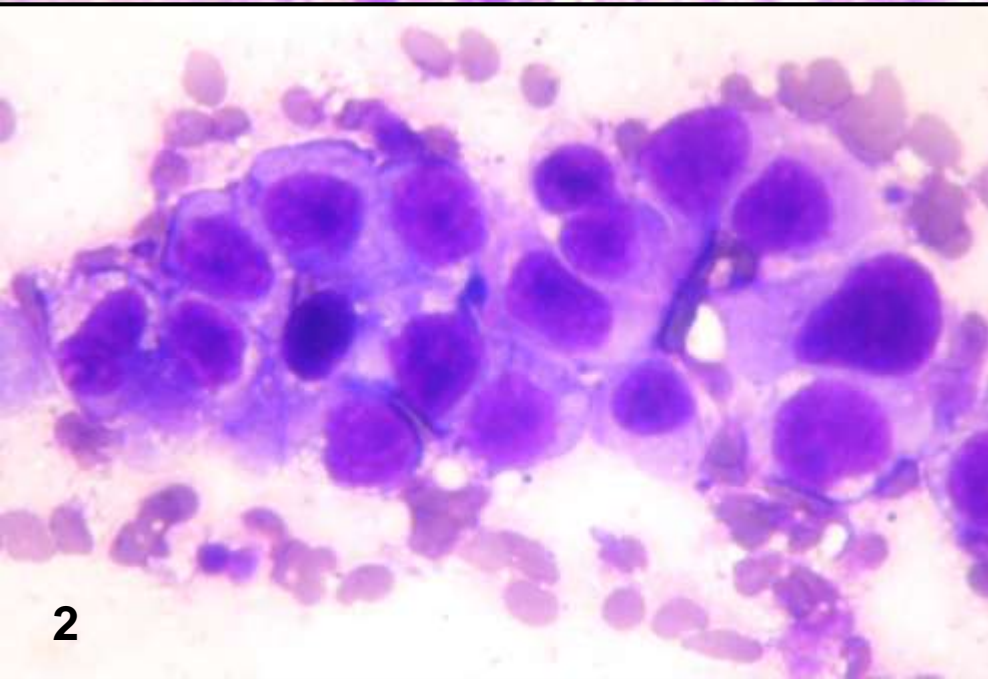
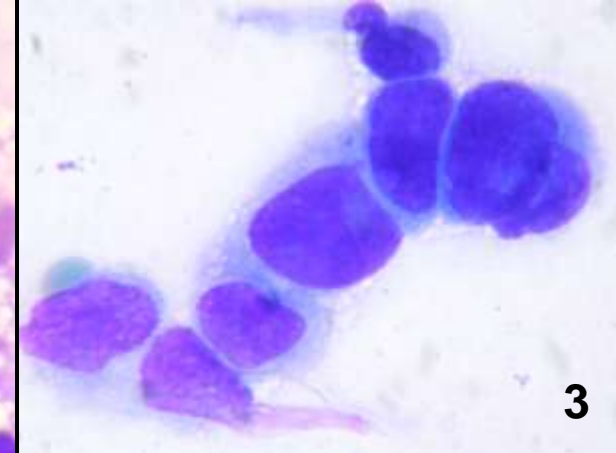
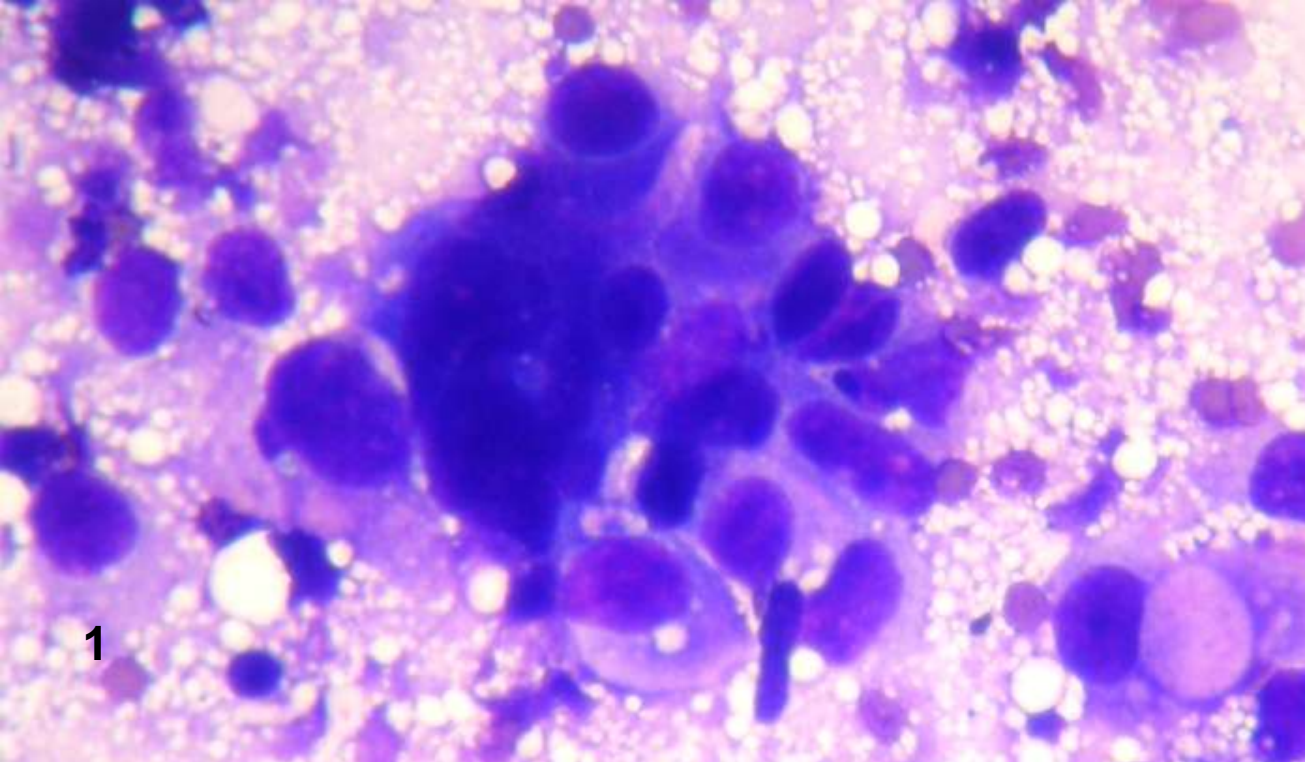


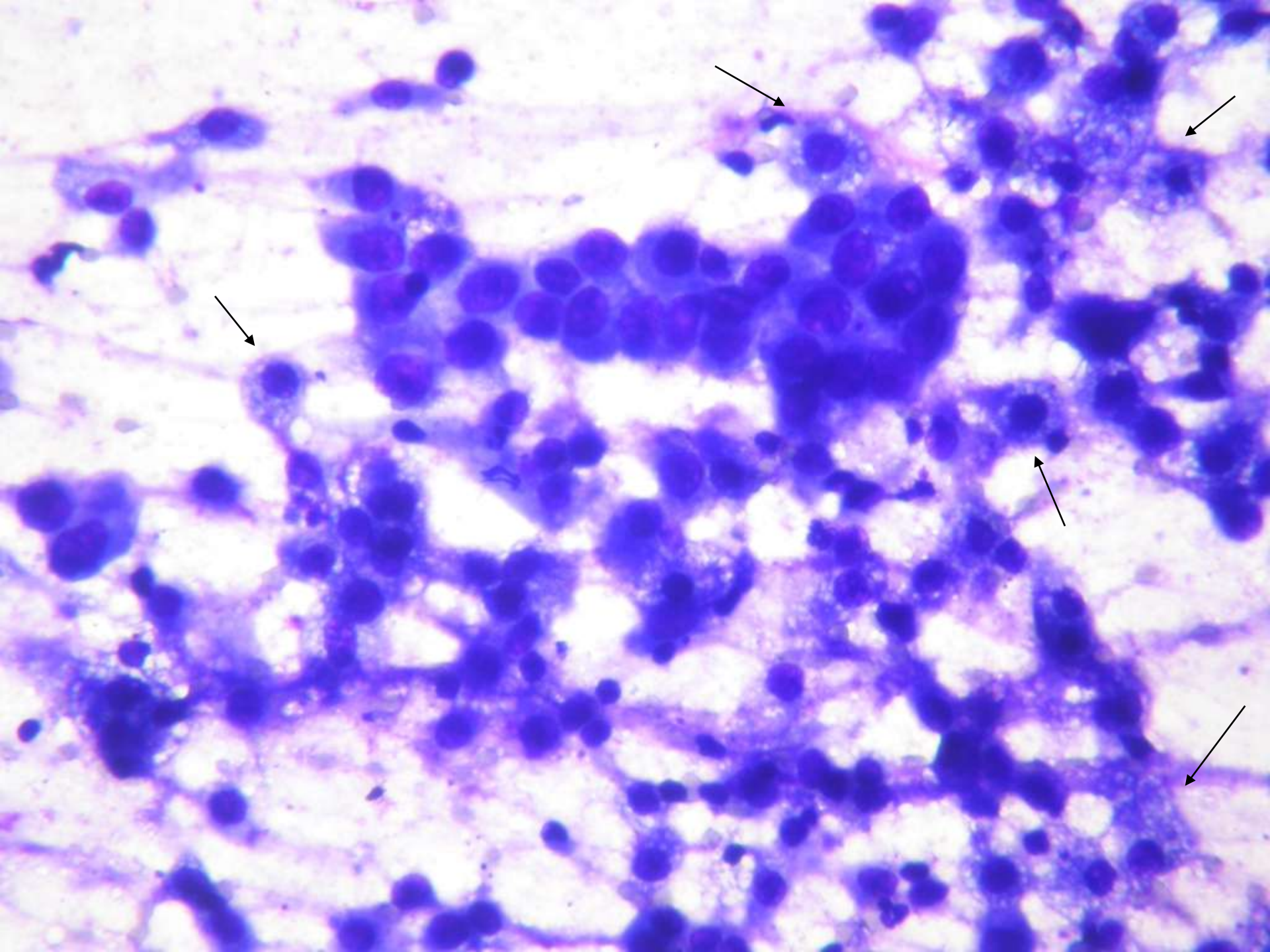


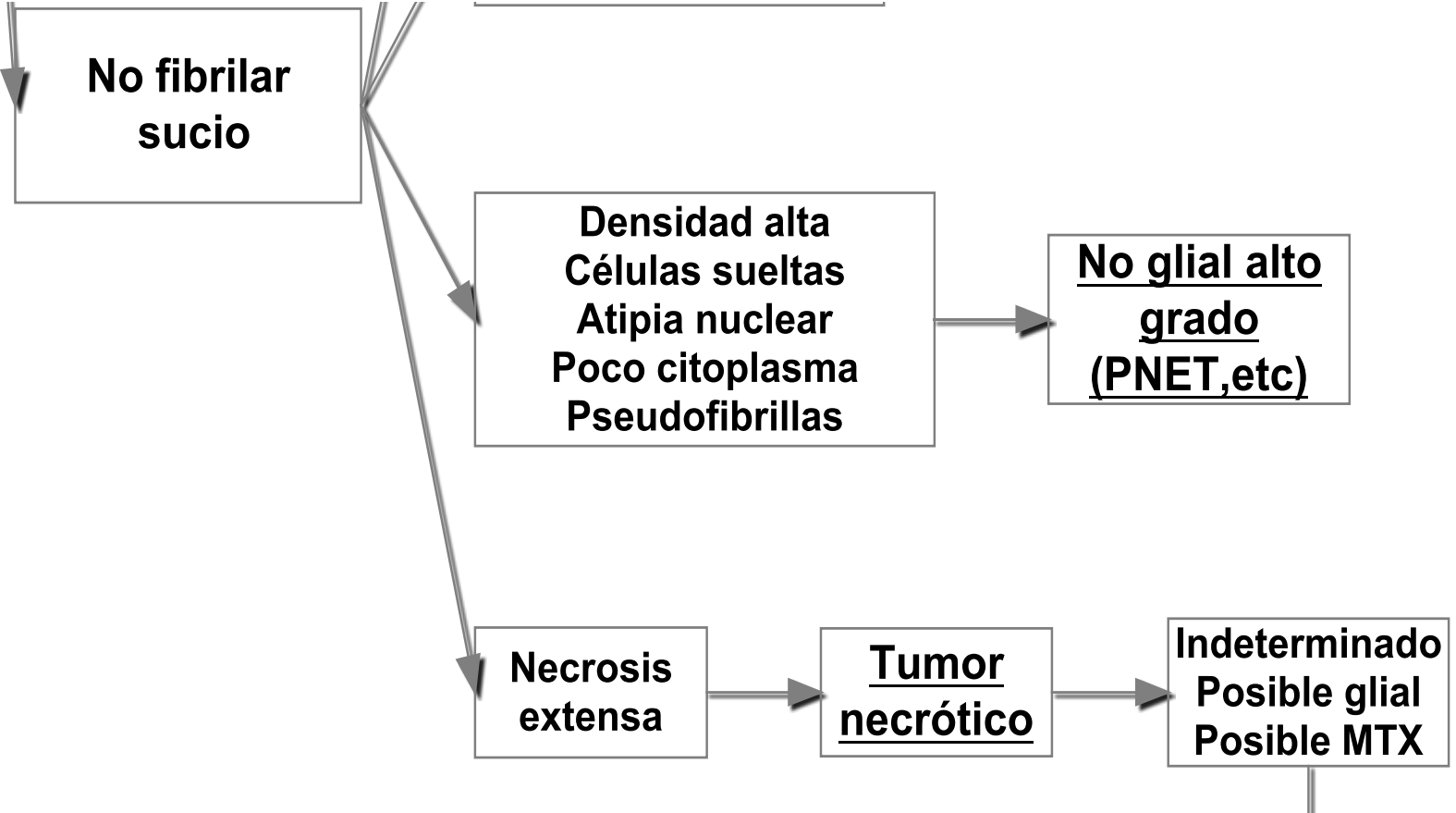


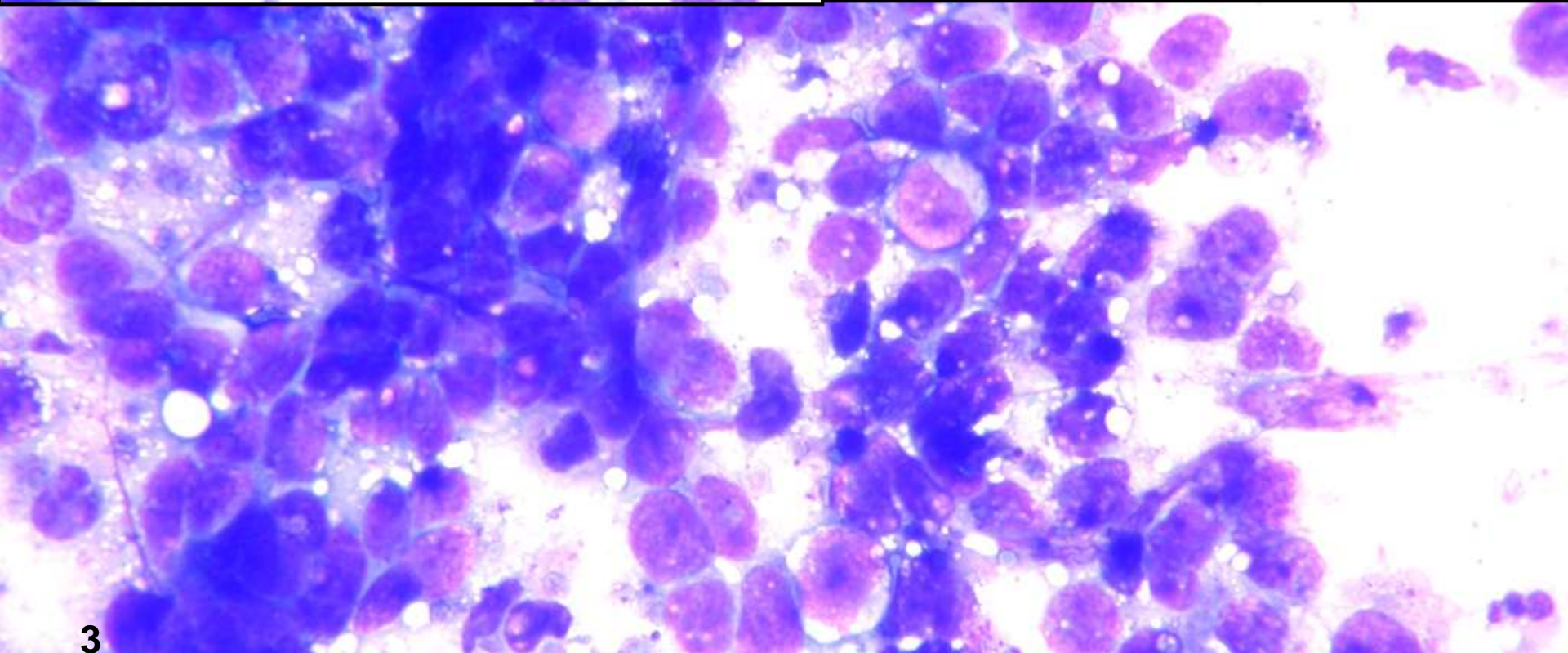
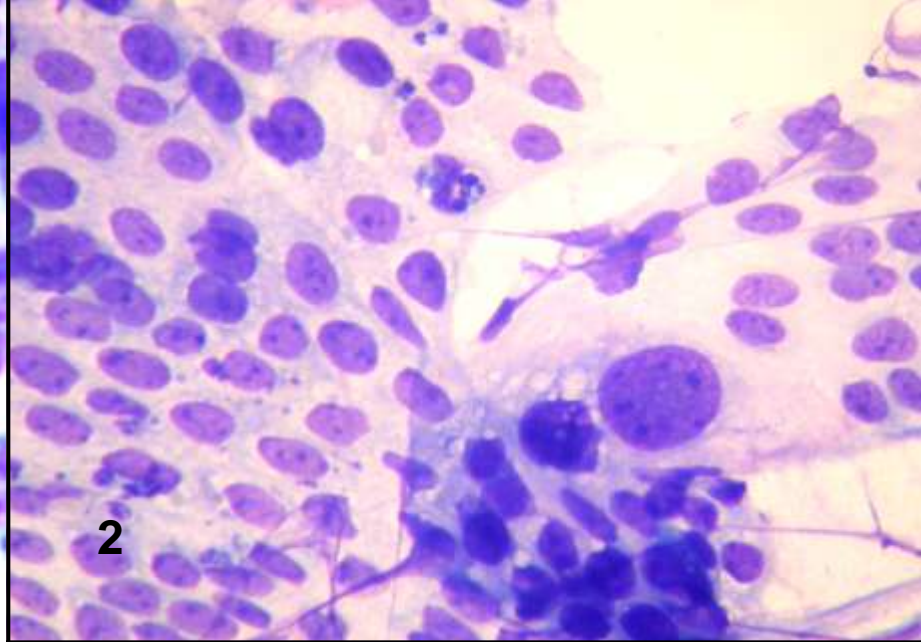
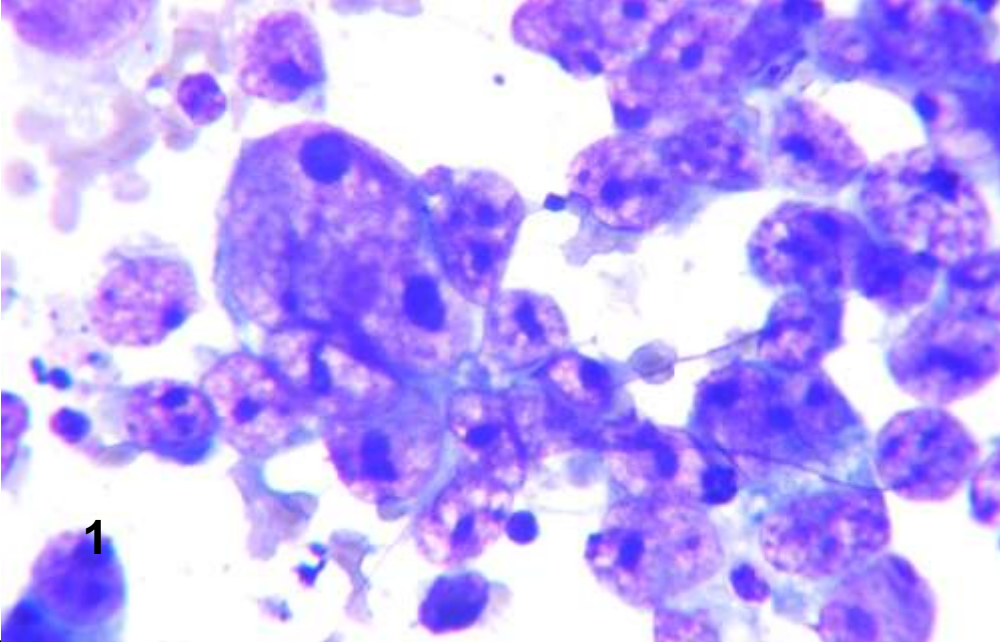


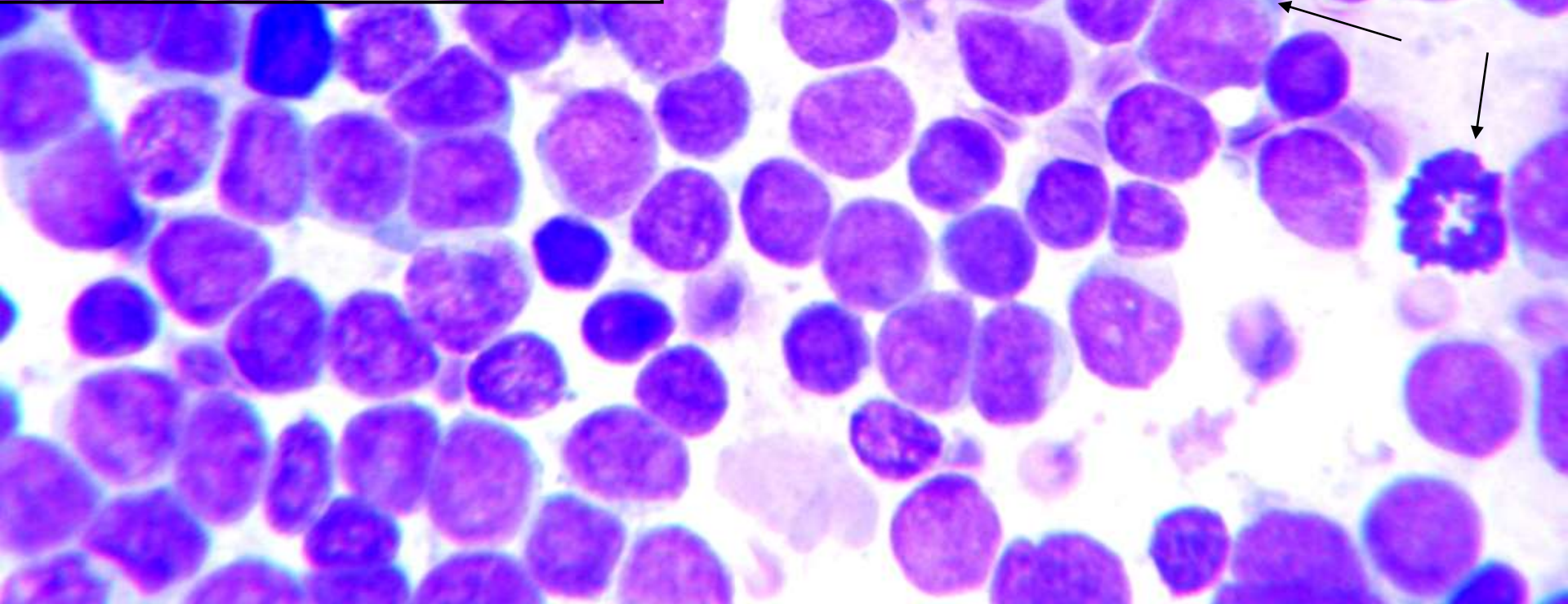
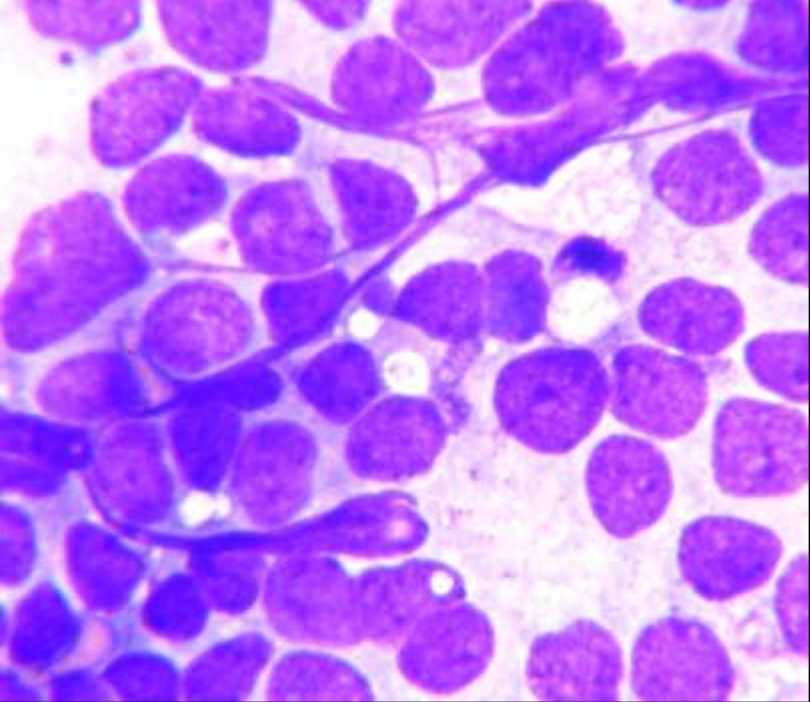


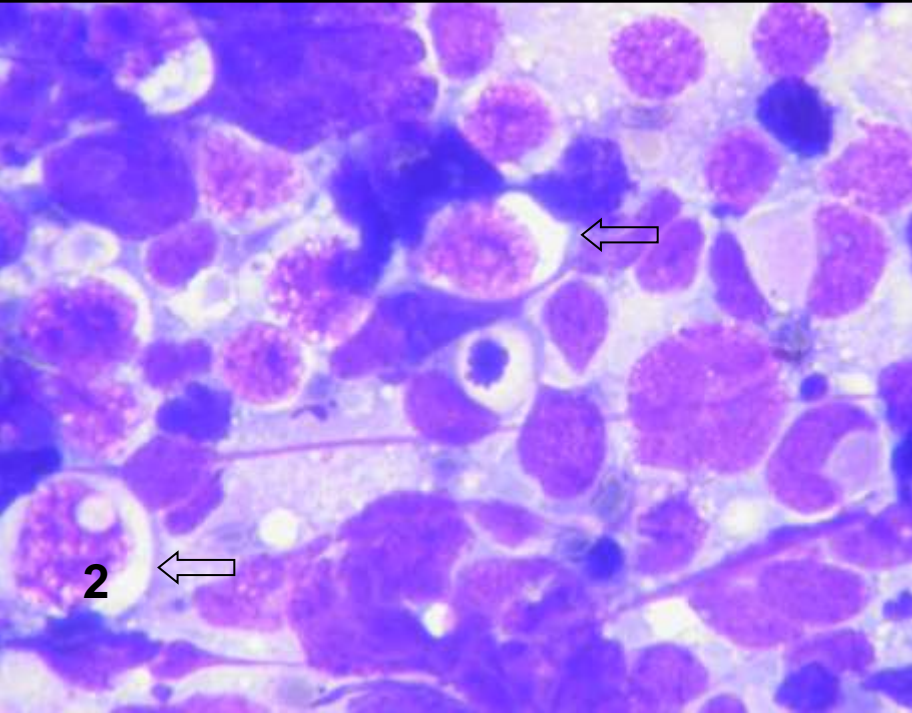
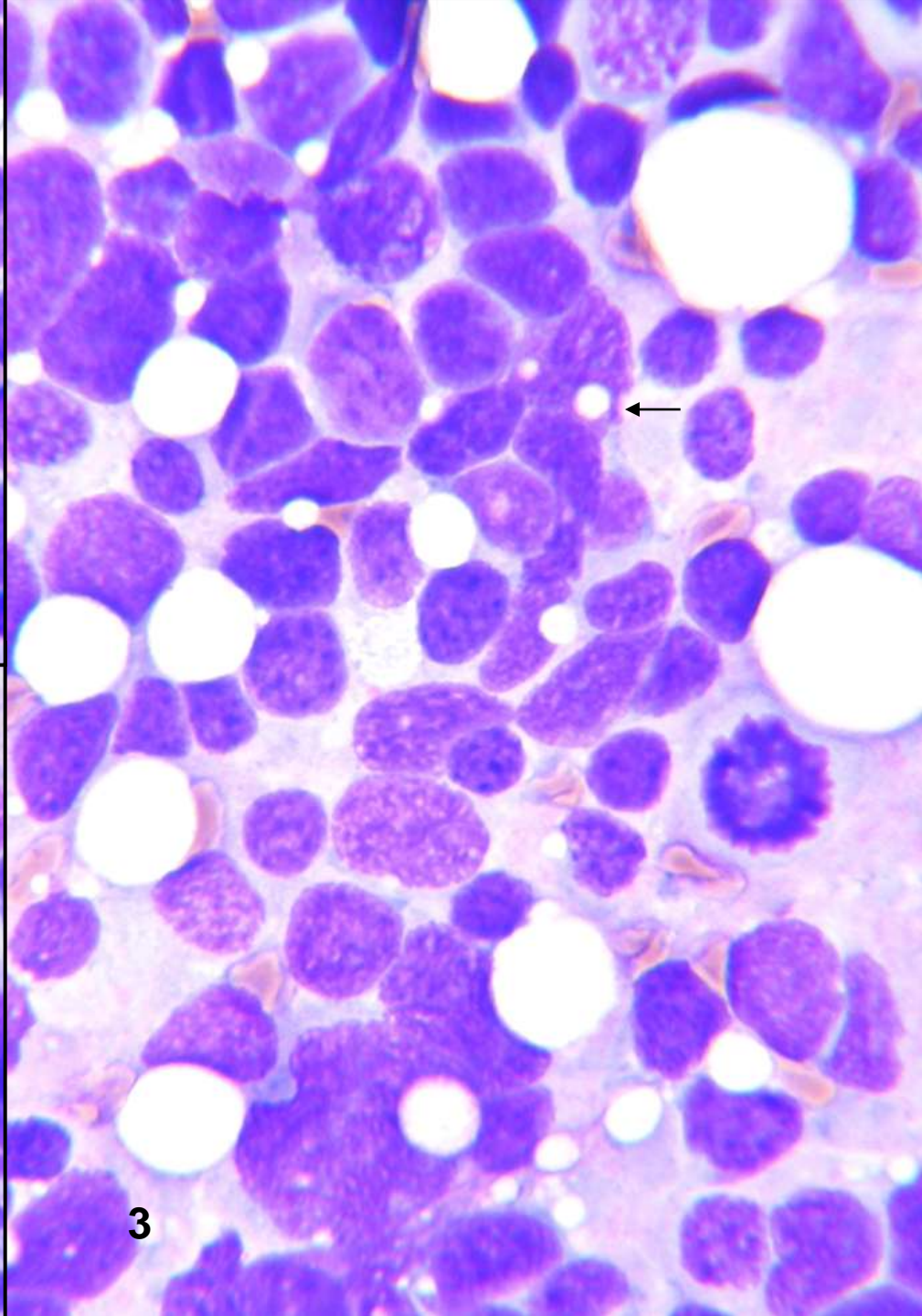
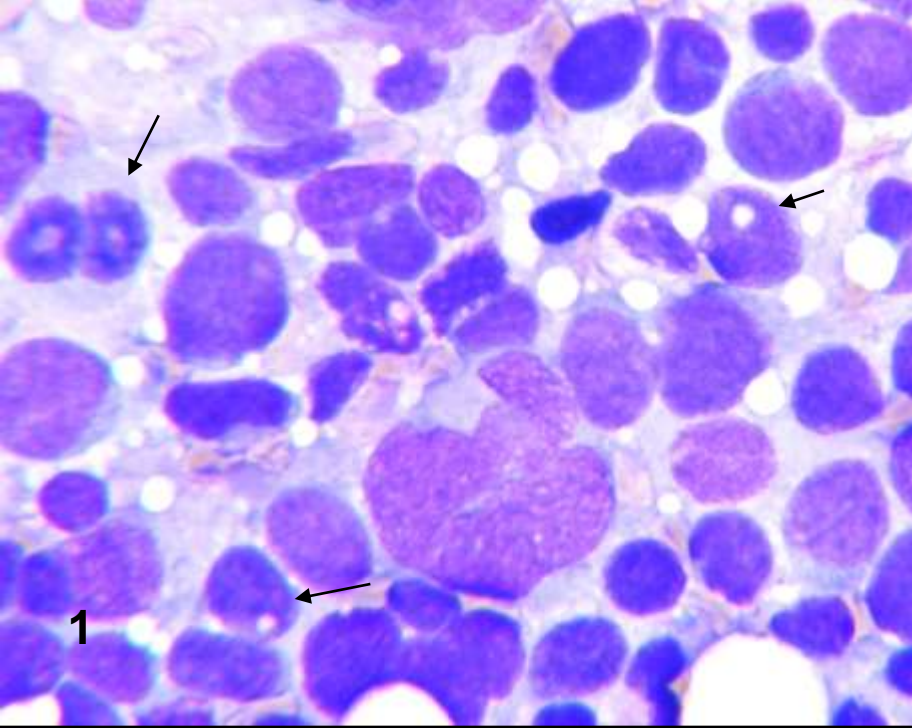


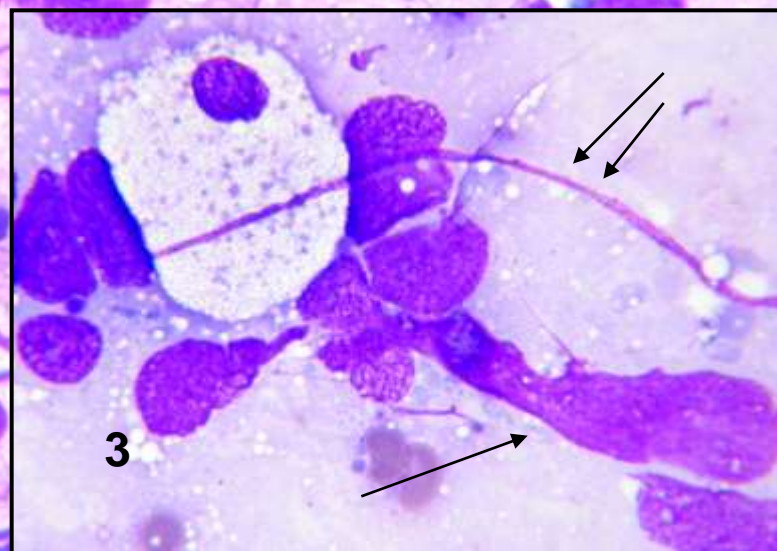
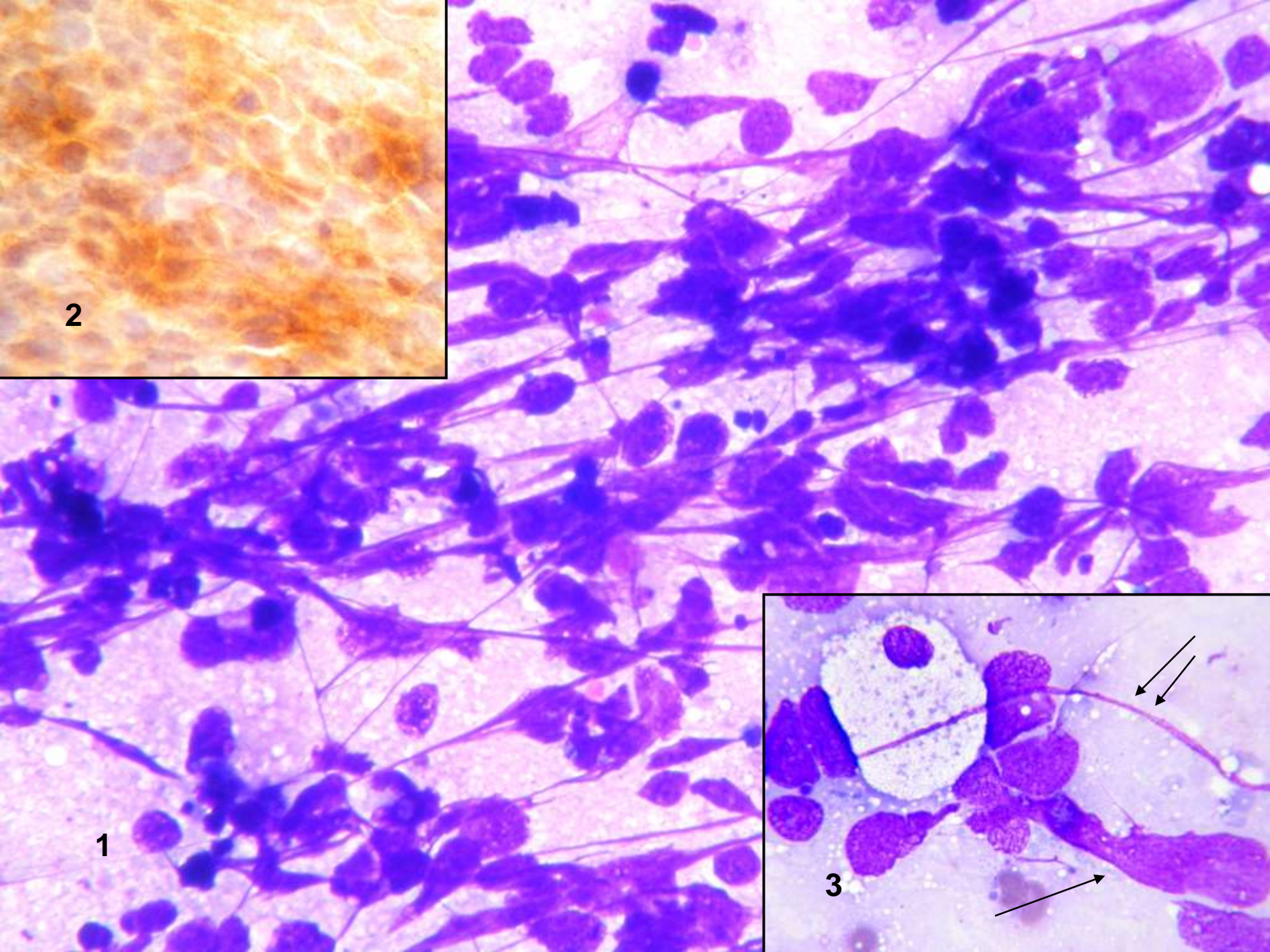
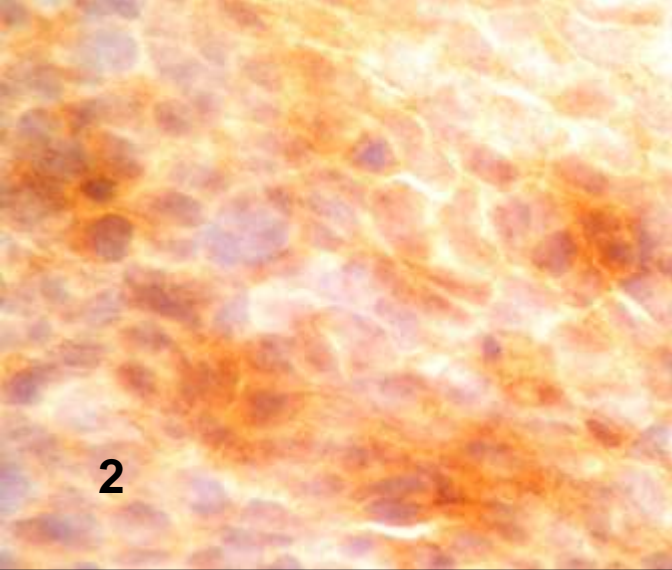


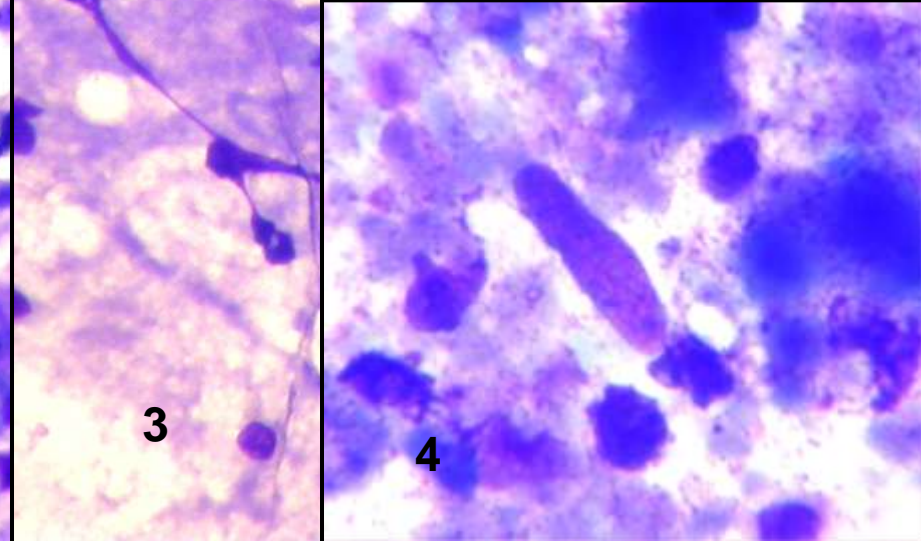
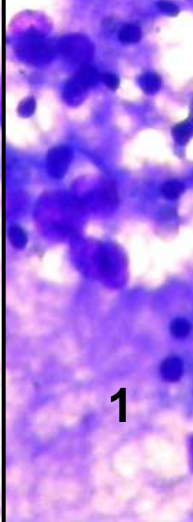
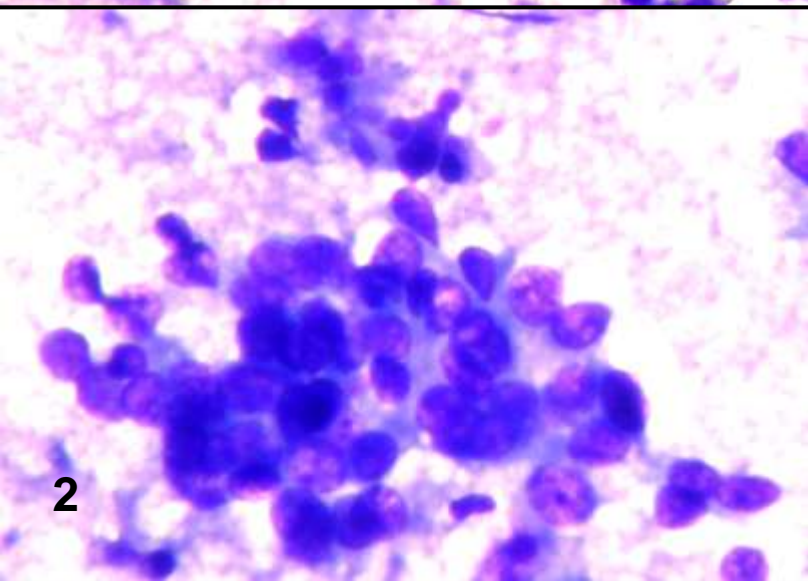
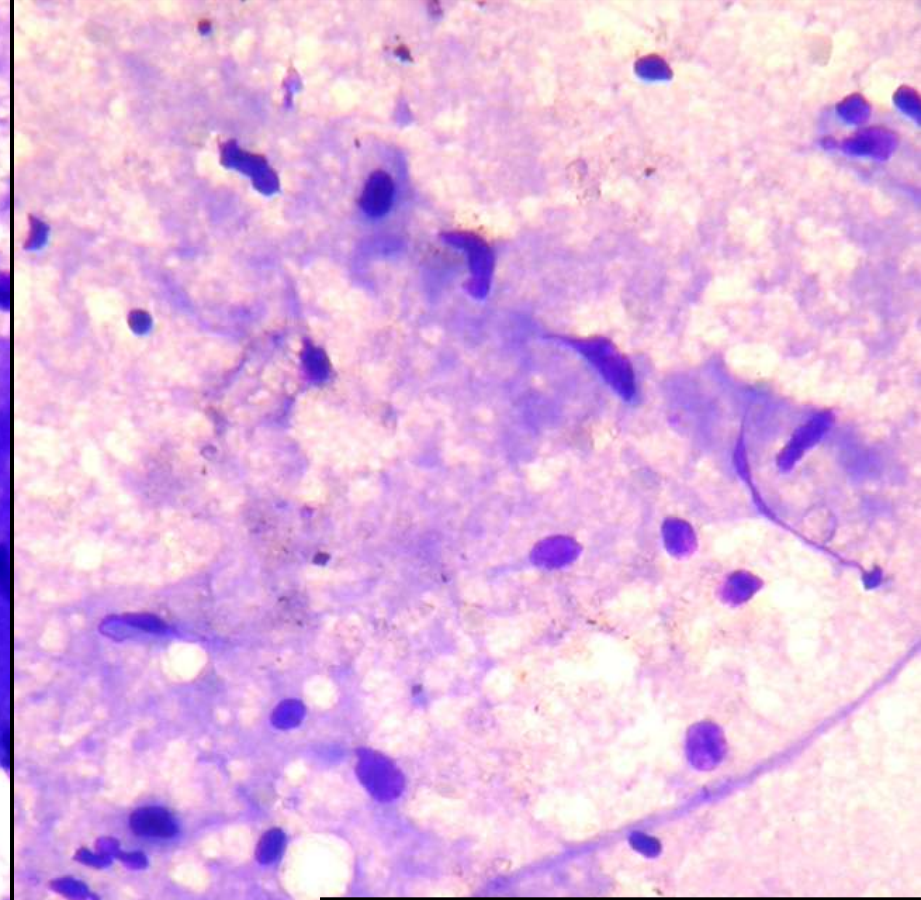
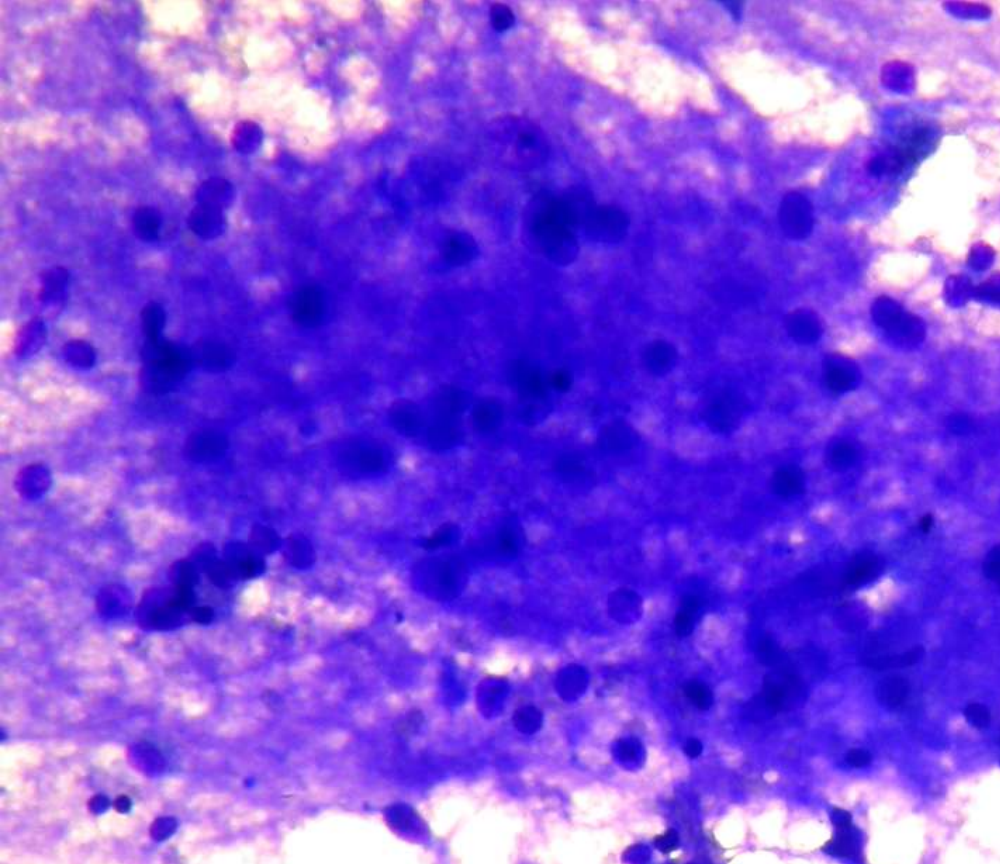












2

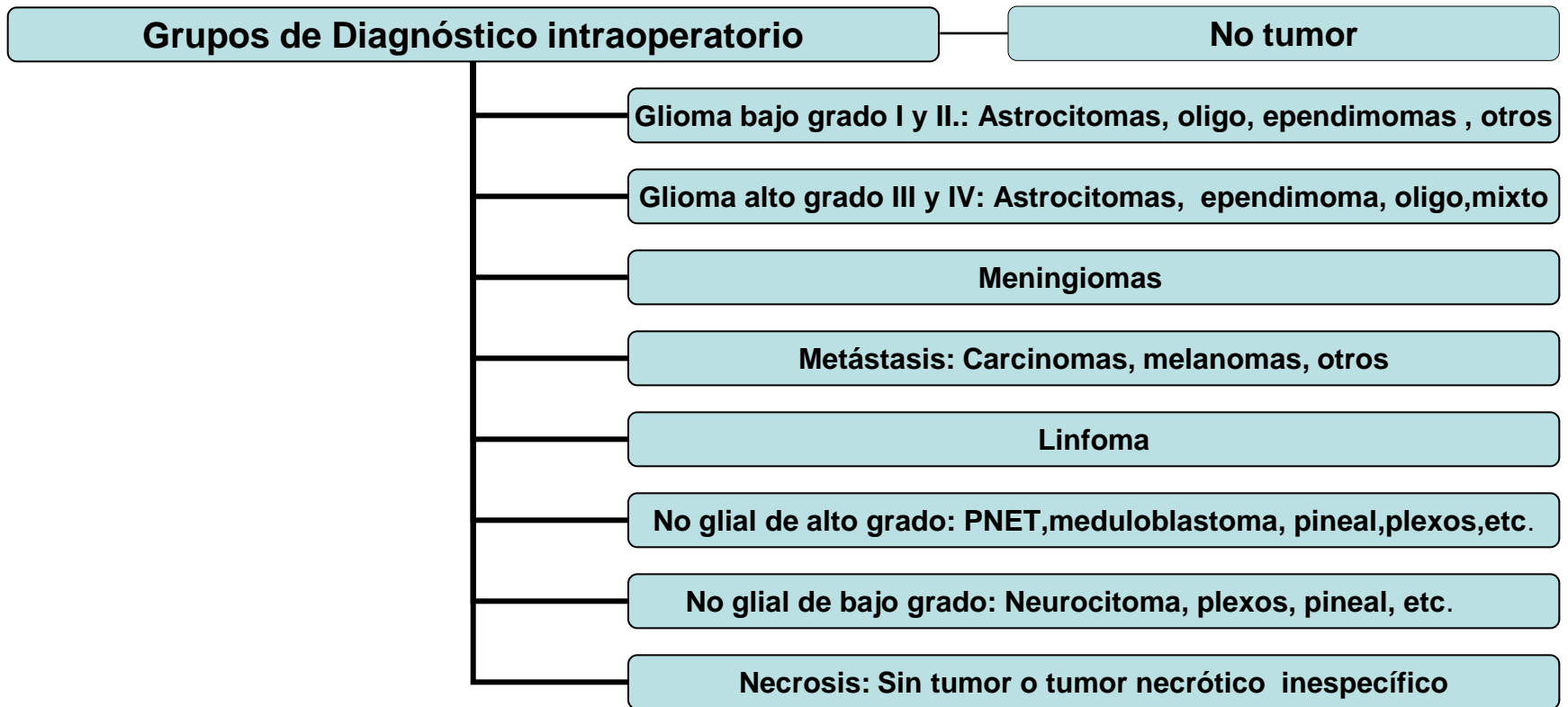
1

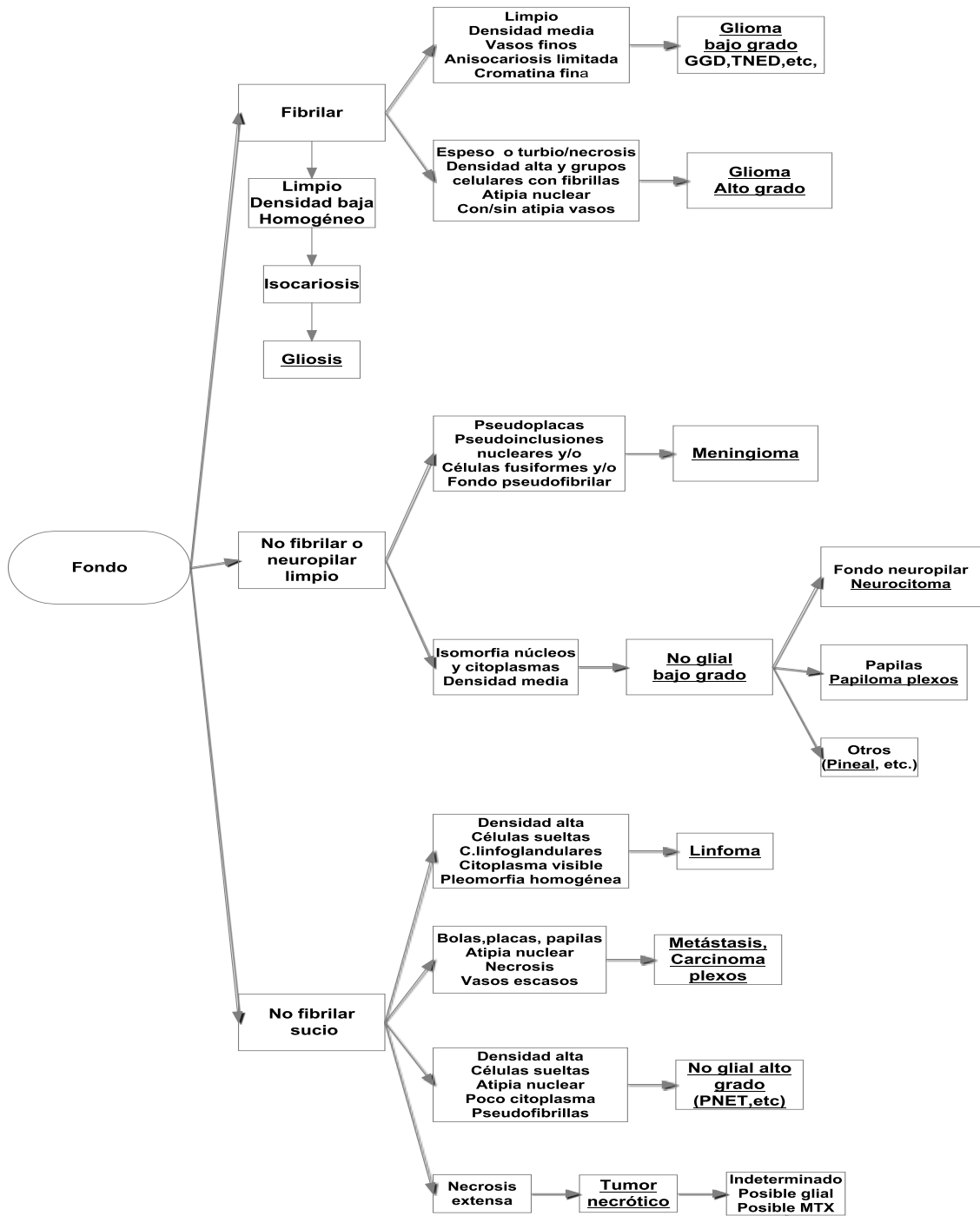
3

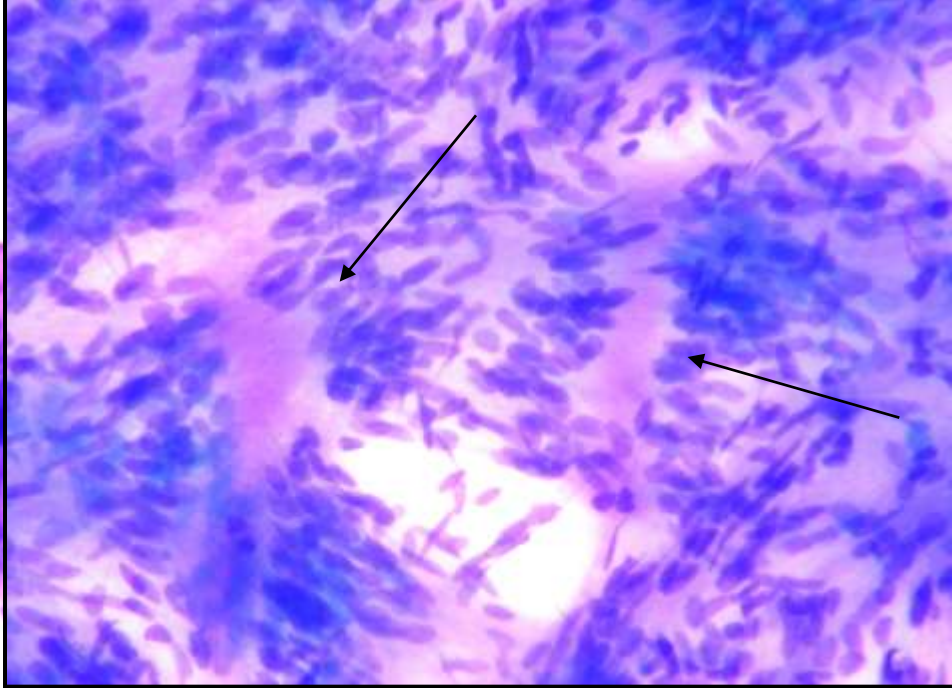
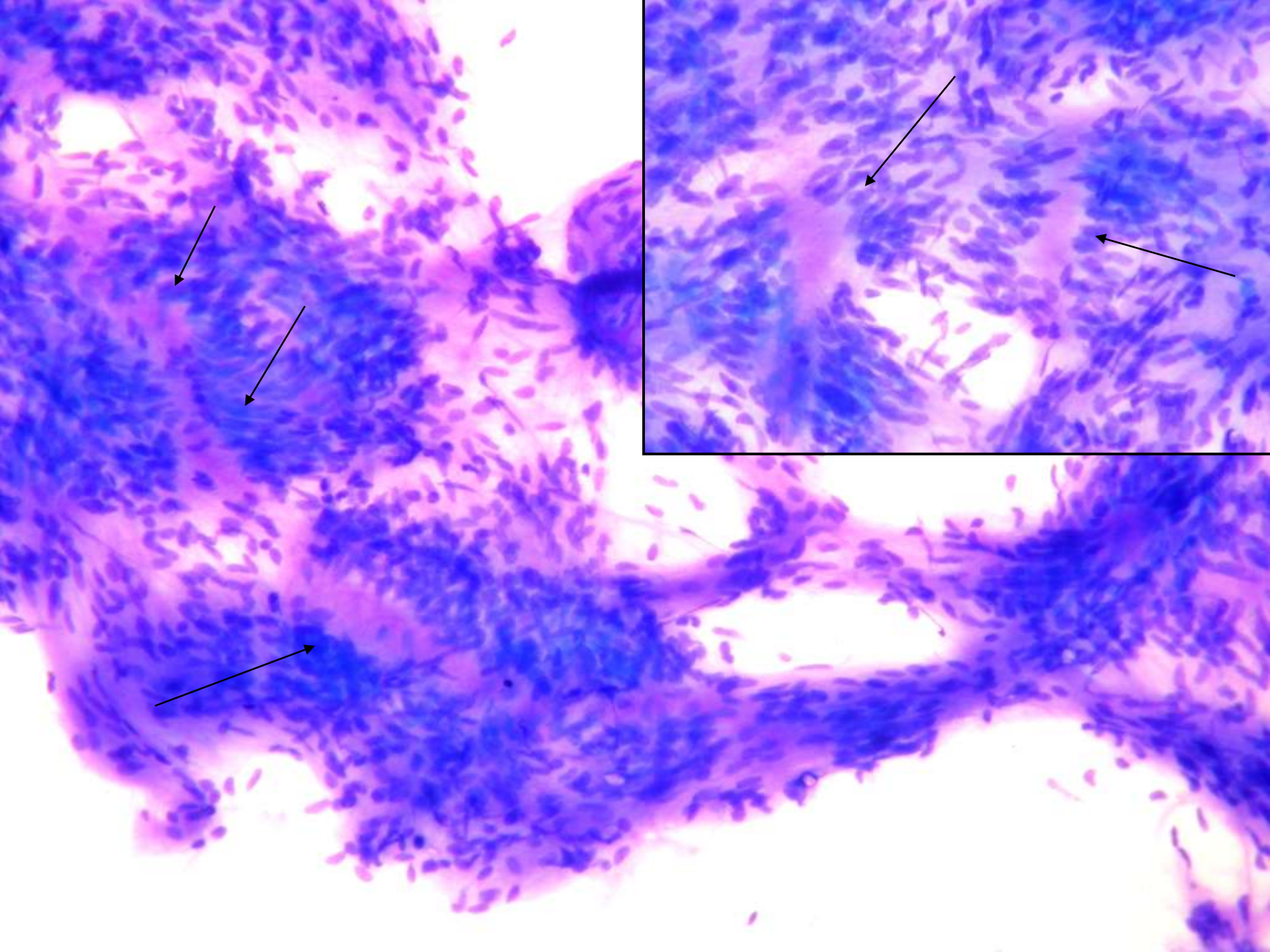
4

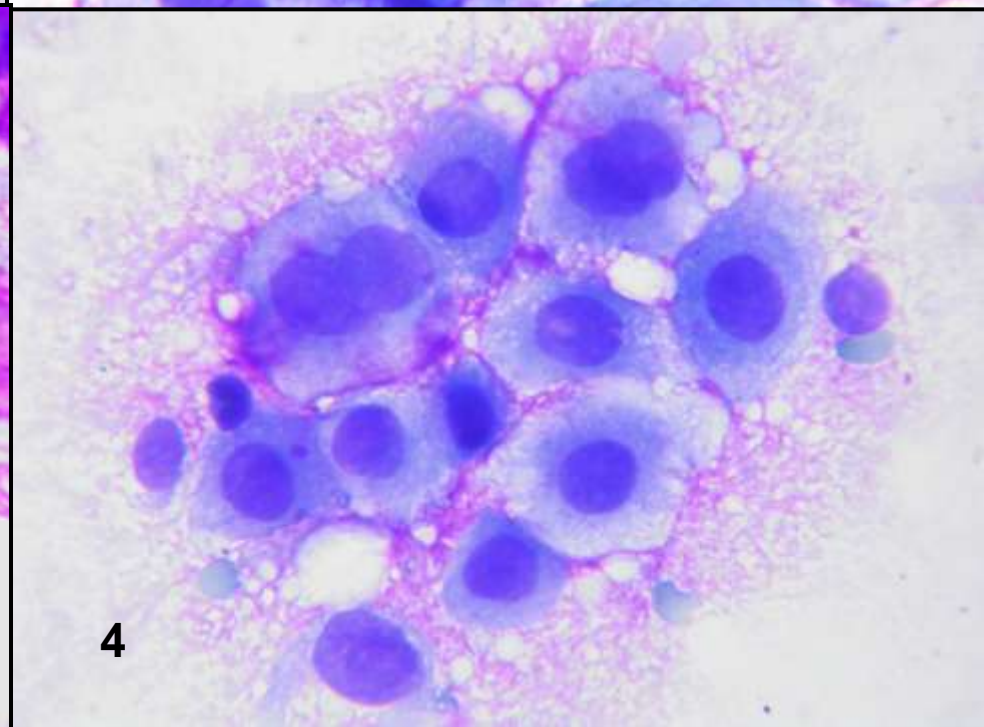
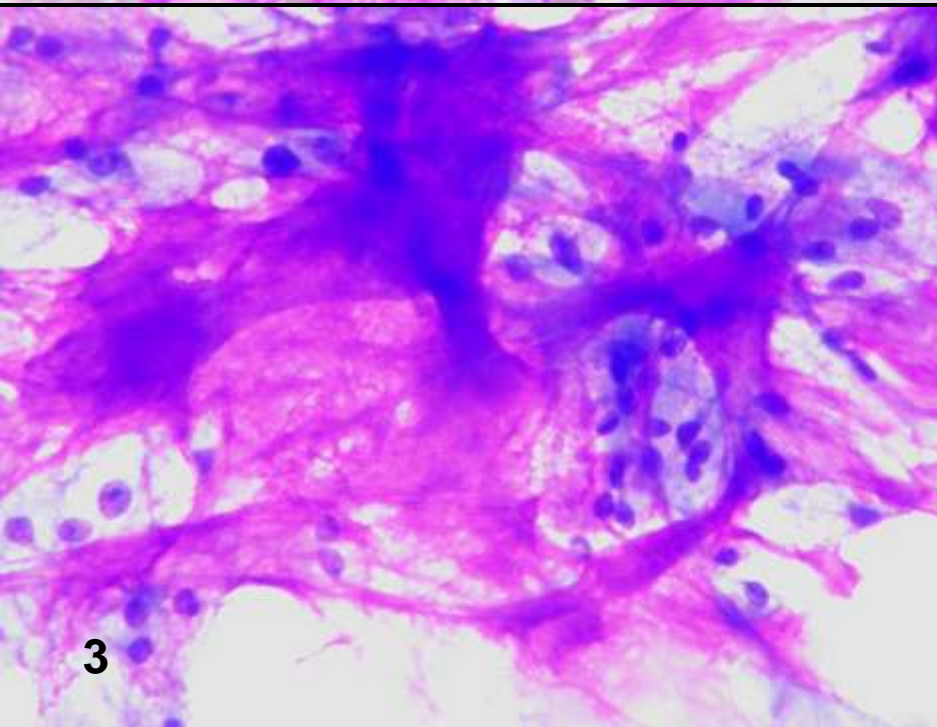
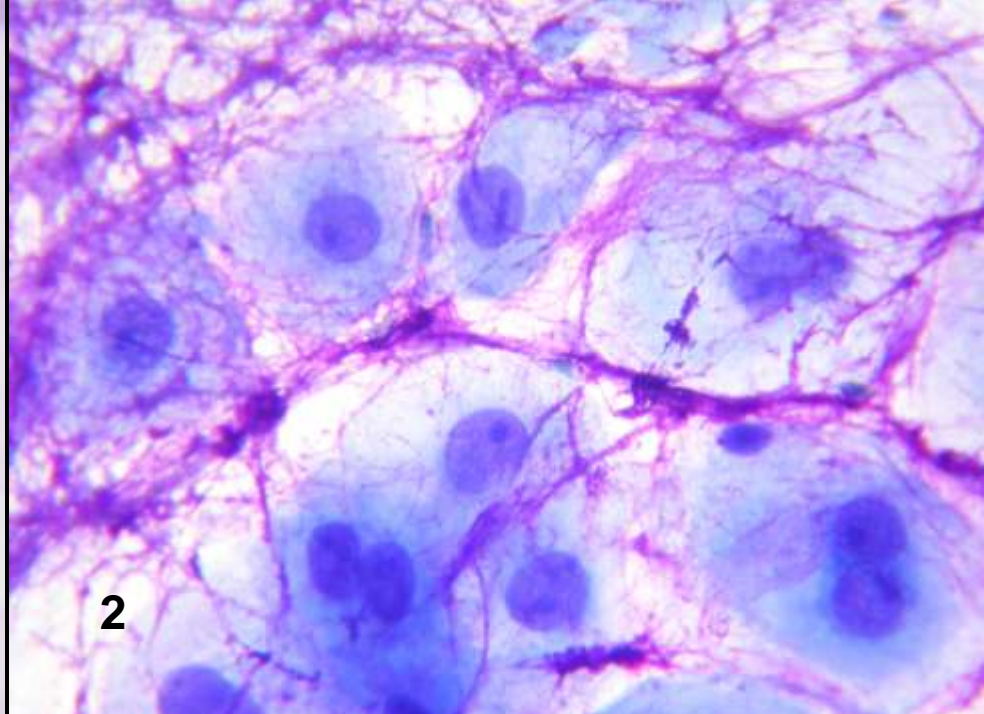
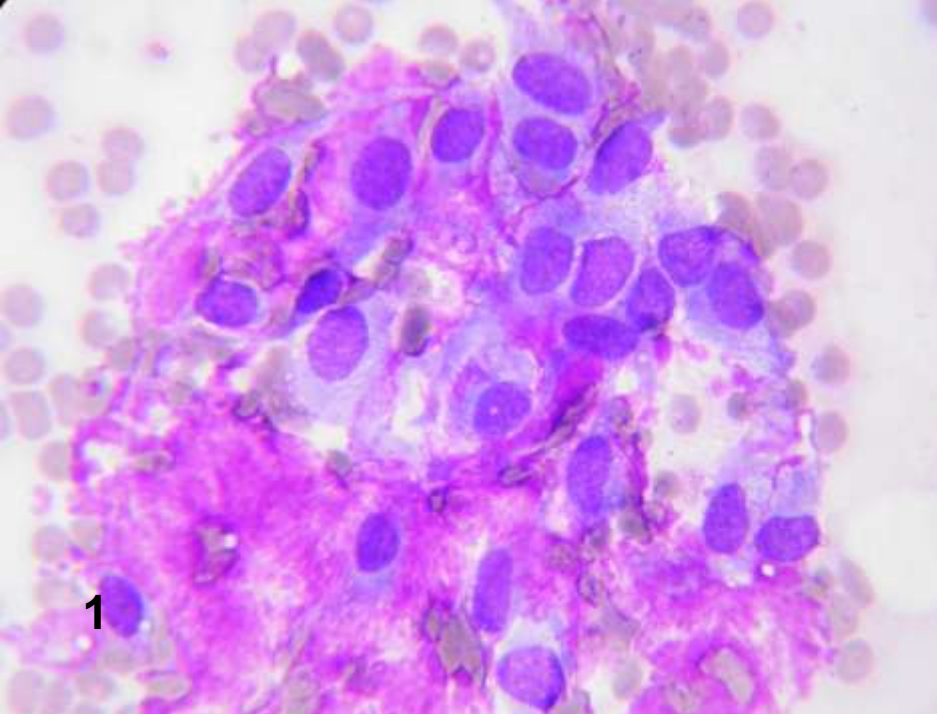


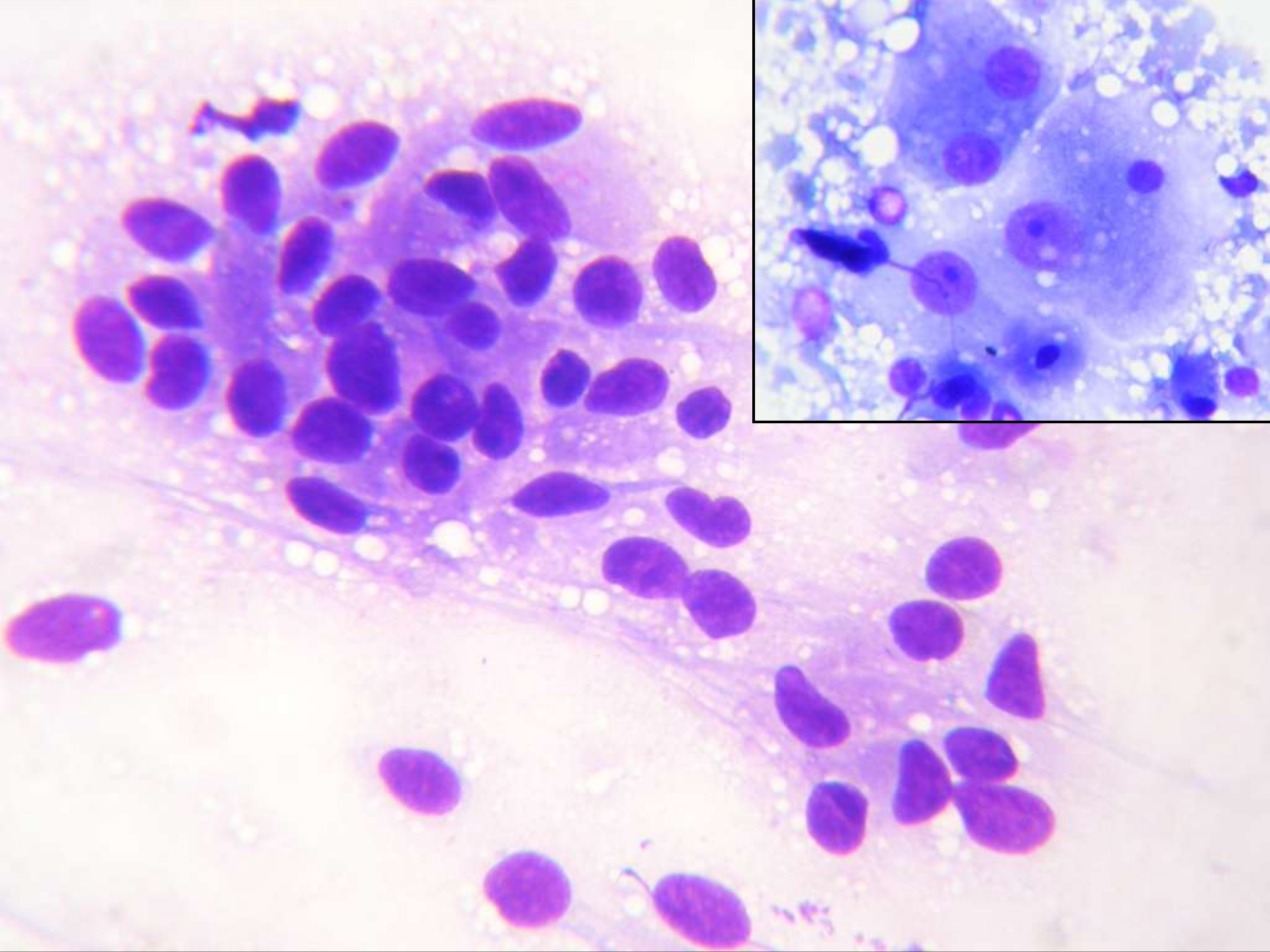
# Grupos diagnósticos intraoperatorios.











# CUADERNOS DE CITOPATOLOGÍA

J. Rodríguez Costa · D. De Agustín Vázquez  
Directores

## 9. Diagnóstico intraoperatorio citológico de los tumores del sistema nervioso

Emilio Salinero Paniagua  
Julio Rodríguez Costa  
Domingo de Agustín Vázquez

