



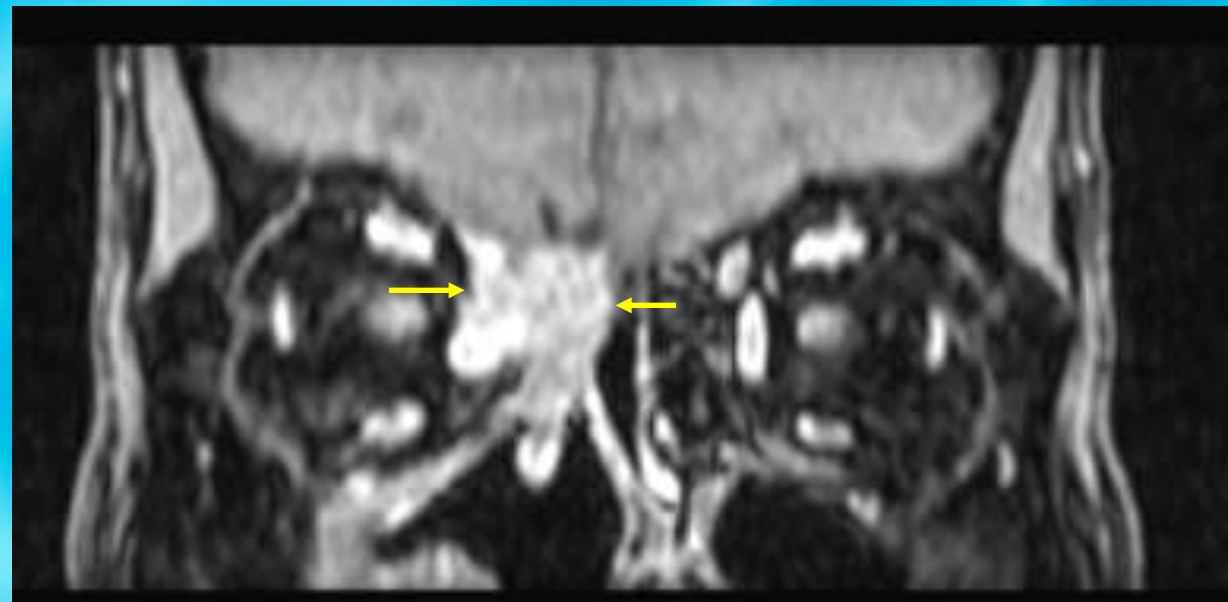
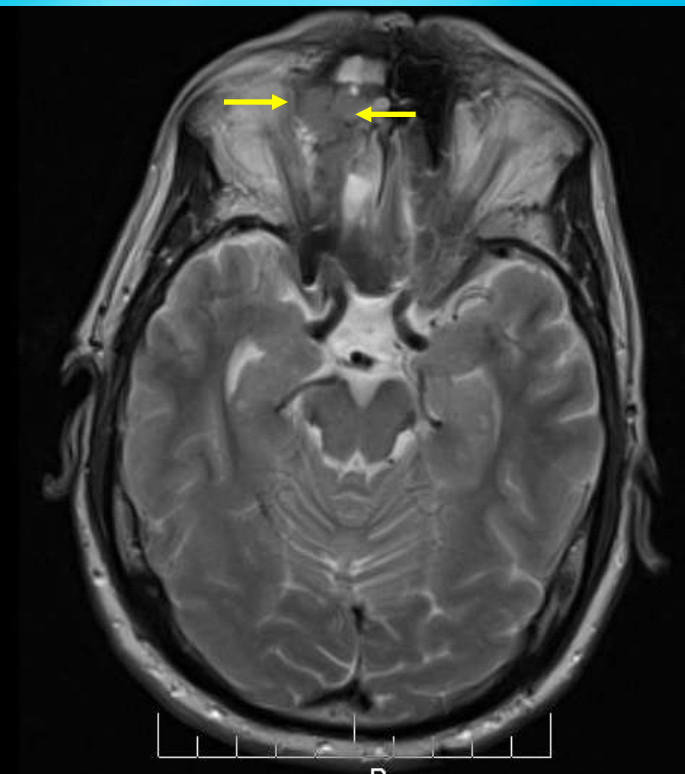
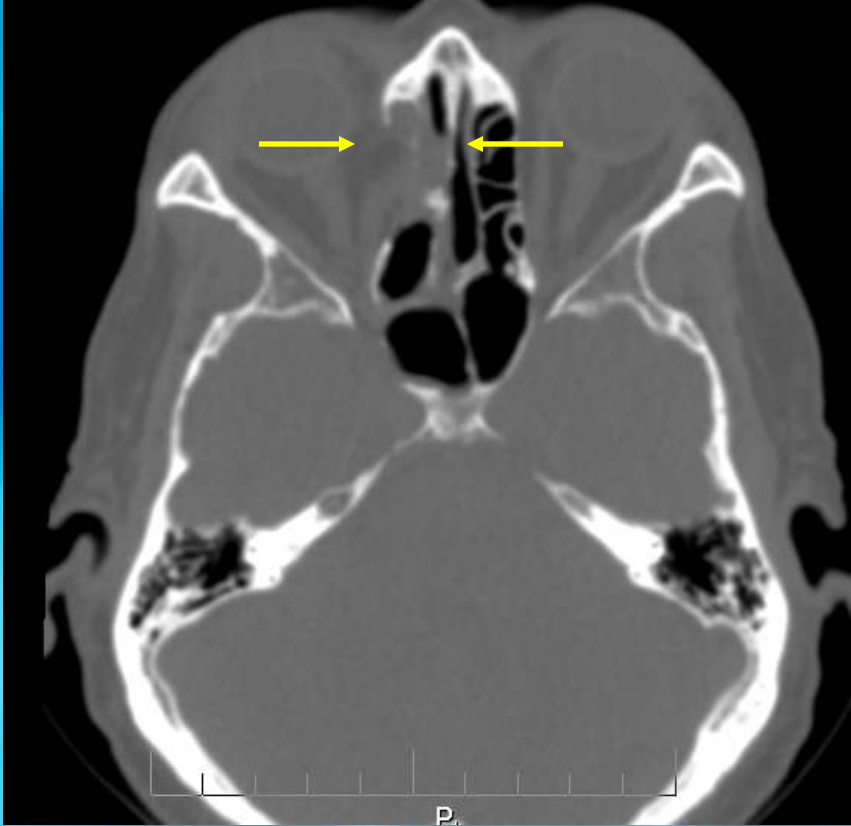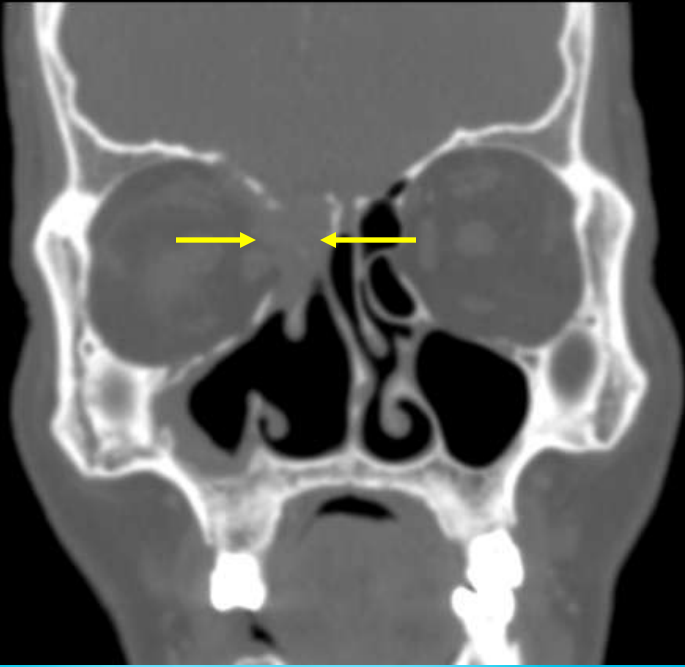
**XXV Congreso de la Sociedad Española de
Anatomía Patológica
y División Española de la International
Academy of Pathology
XX Congreso de la Sociedad Española de
Citología
I Congreso de la Sociedad Española de
Patología Forense**

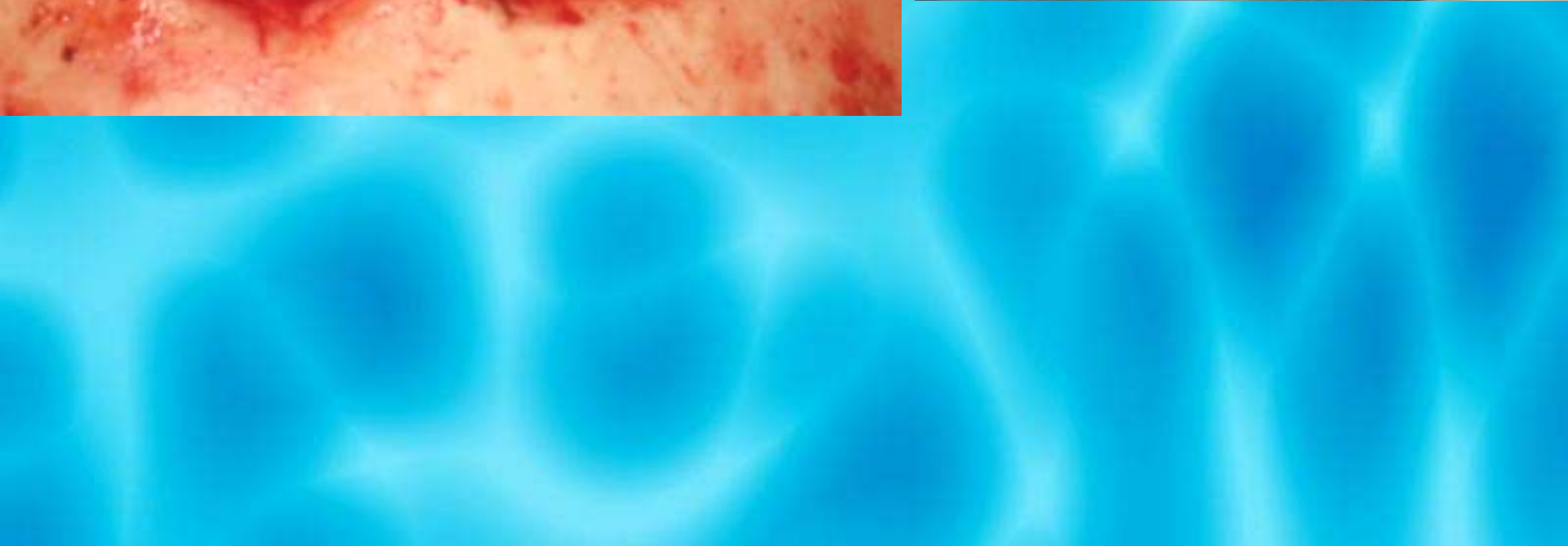
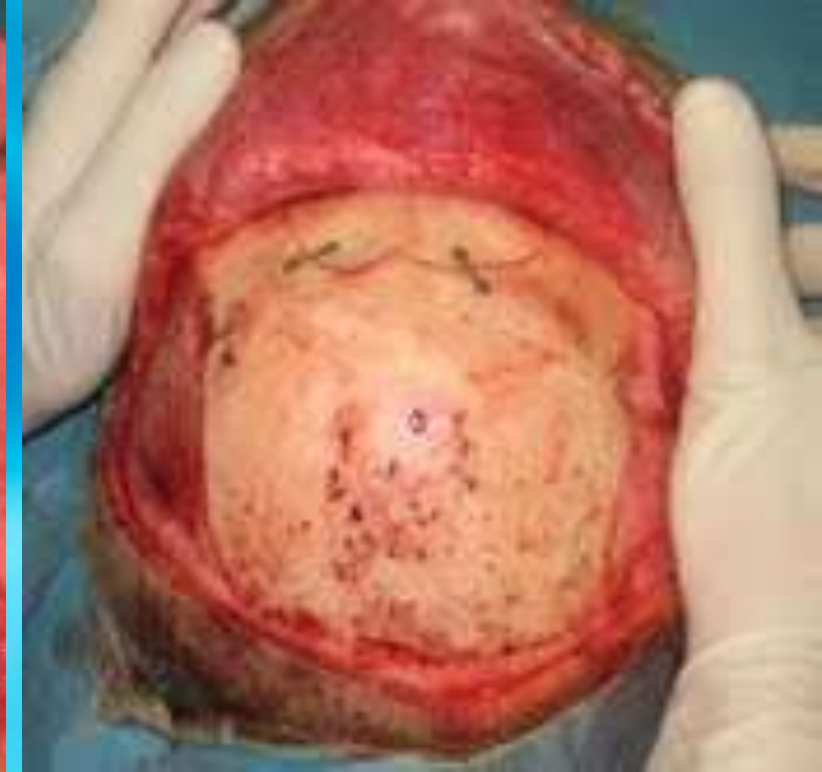
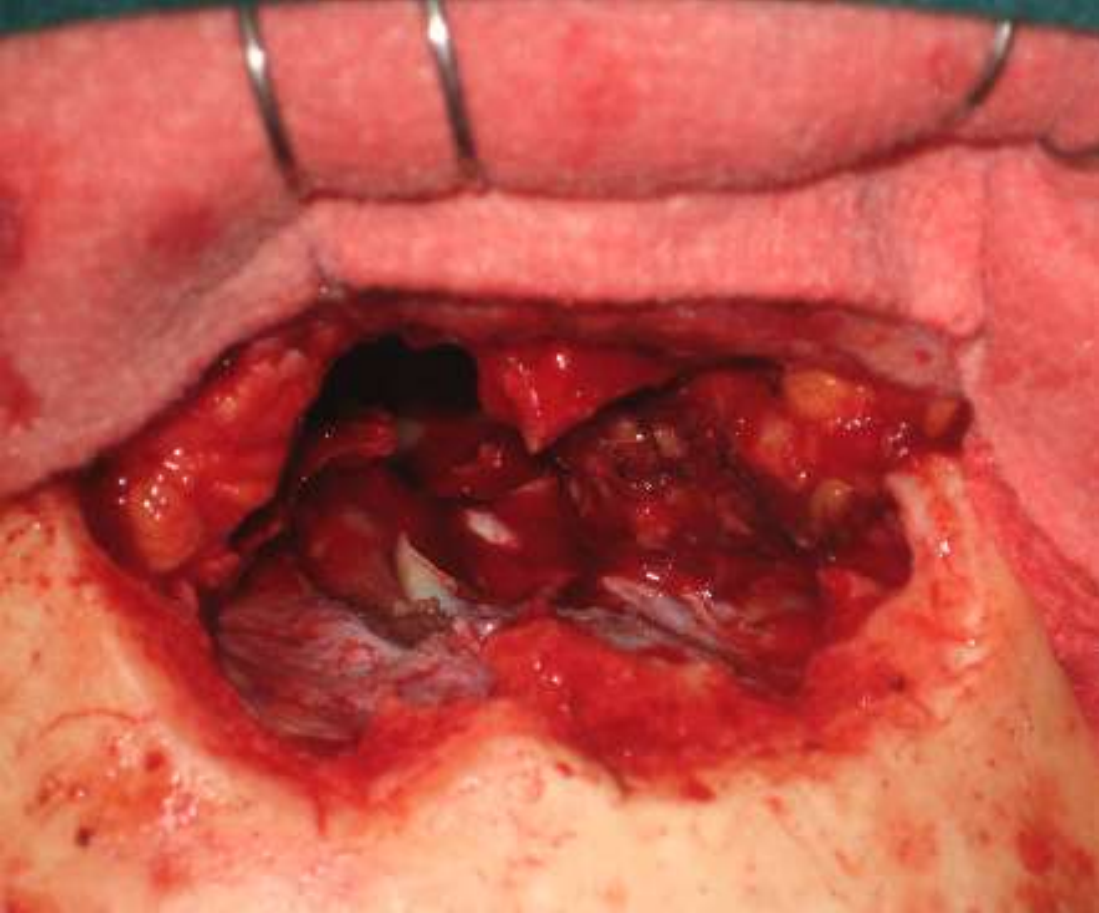
**SEMINARIO PARTES BLANDAS
Manuel F Fresno Forcelledo**

HISTORIA CLINICA

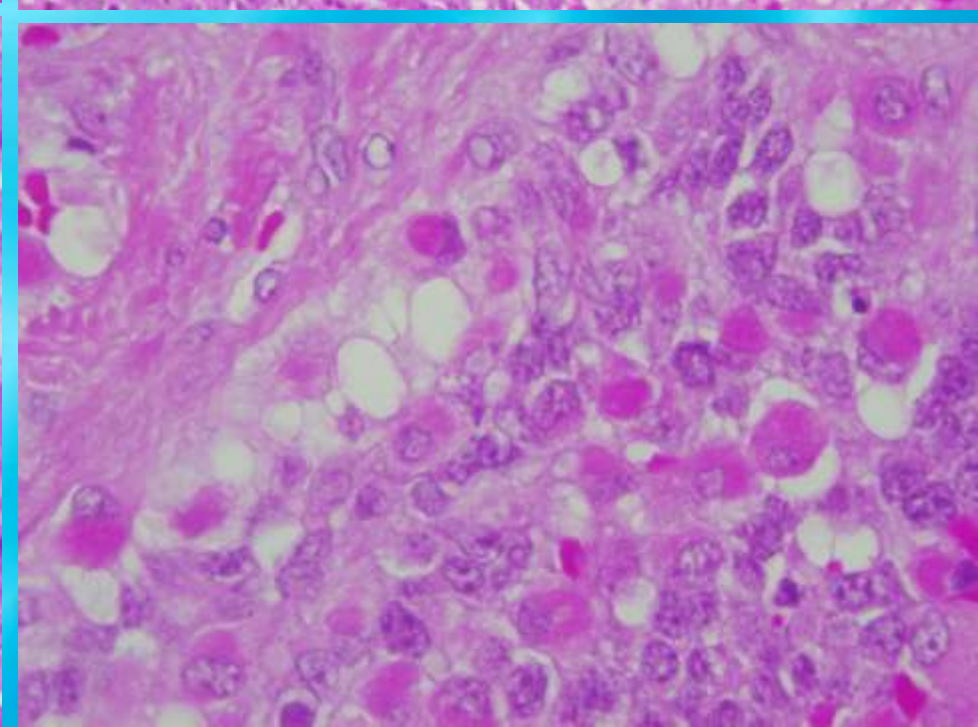
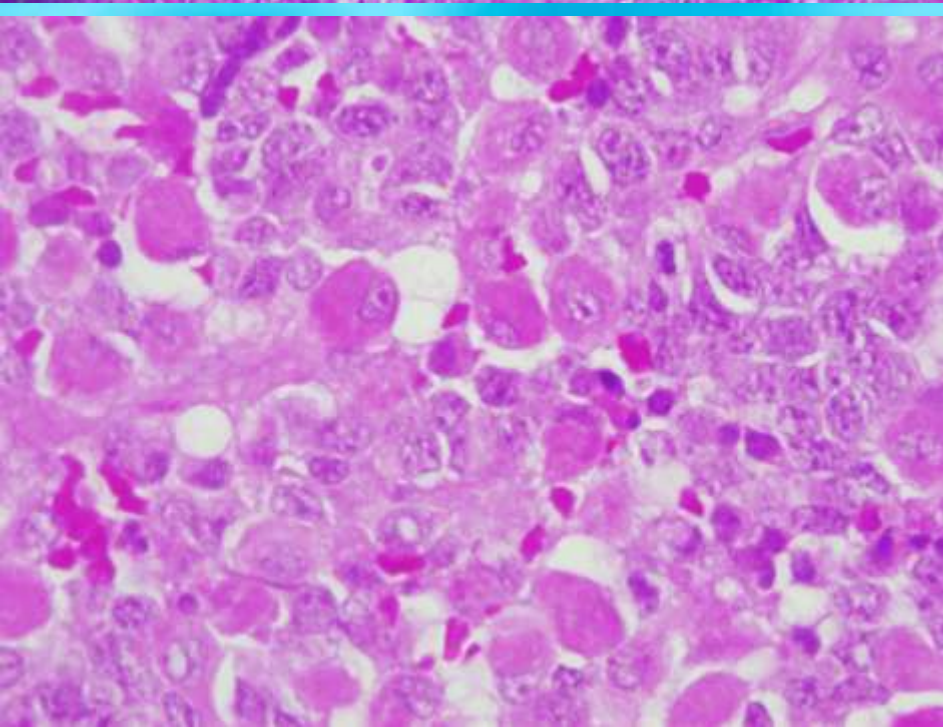
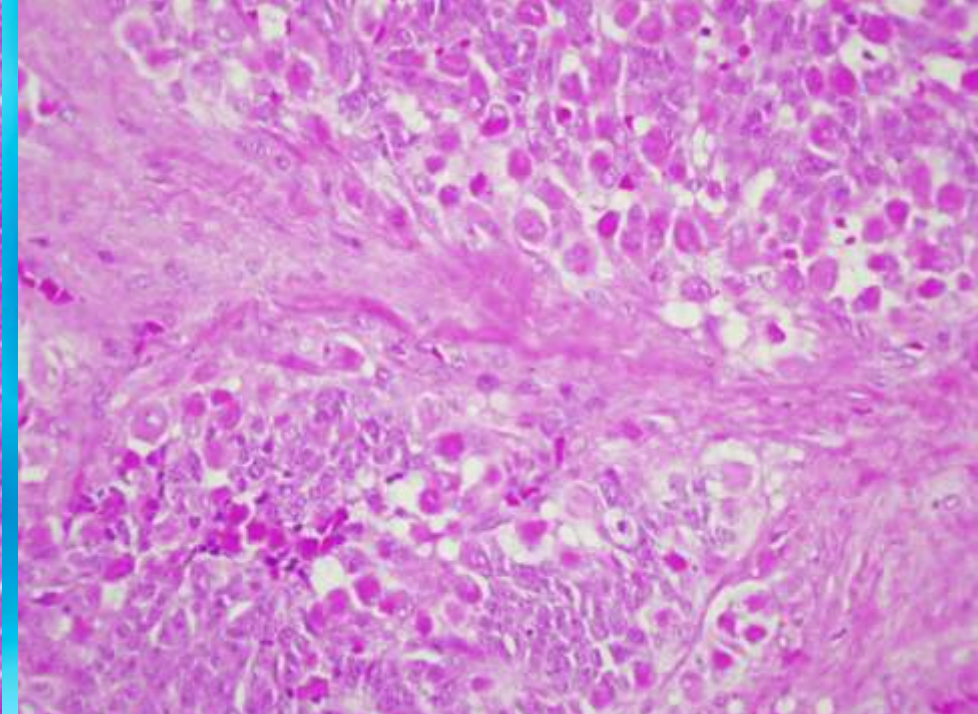
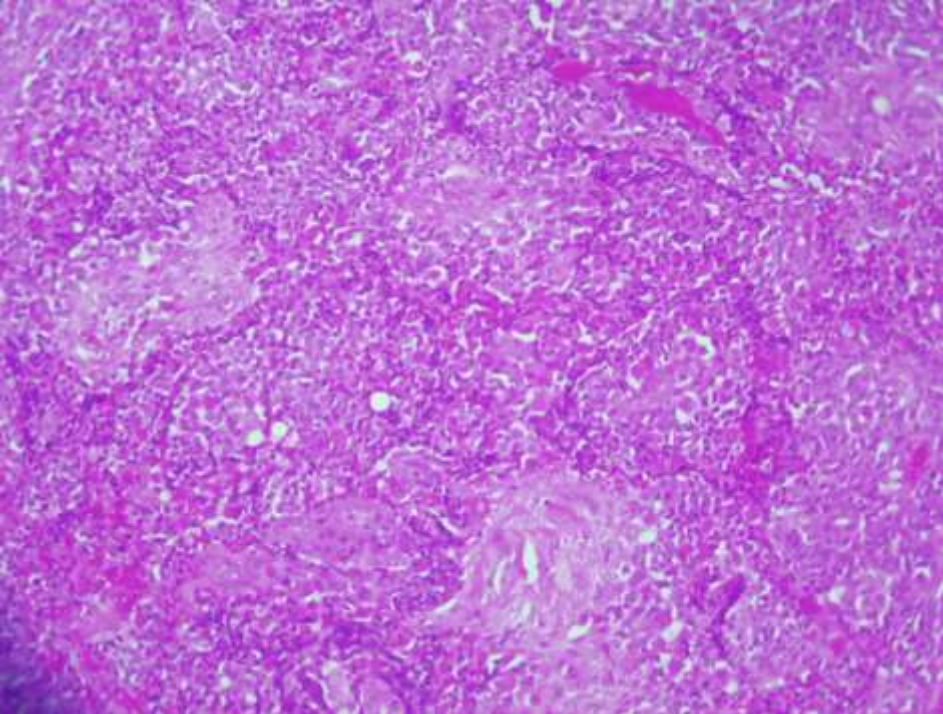
- Paciente varón de 63 años, que ingresa en nuestro servicio para intervención quirúrgica
- **Antecedentes personales:** diagnosticado de estesioneuroblastoma y tratado con quimio y radioterapia, con recidivas en 2008 y 2010
- **Historia actual:** remitido por recidiva de tumor de etmoides para ser intervenido quirúrgicamente
- **Intervención quirúrgica:** abordaje craneofacial derecho. Tumorción del techo del etmoides dcho. con afectación de duramadre y región periorbitaria

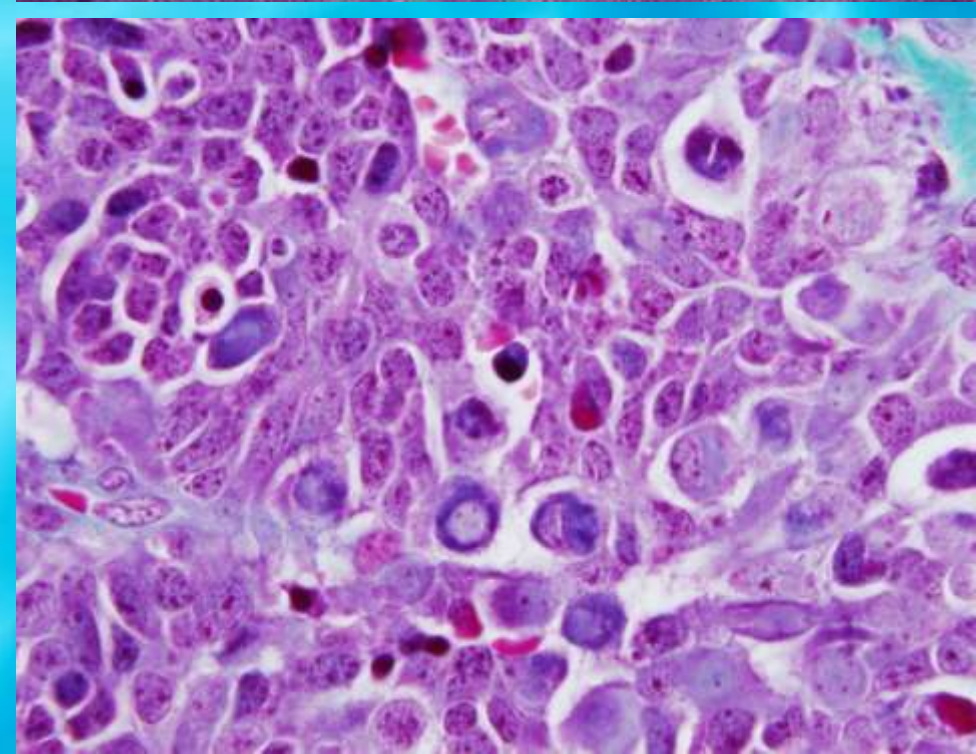
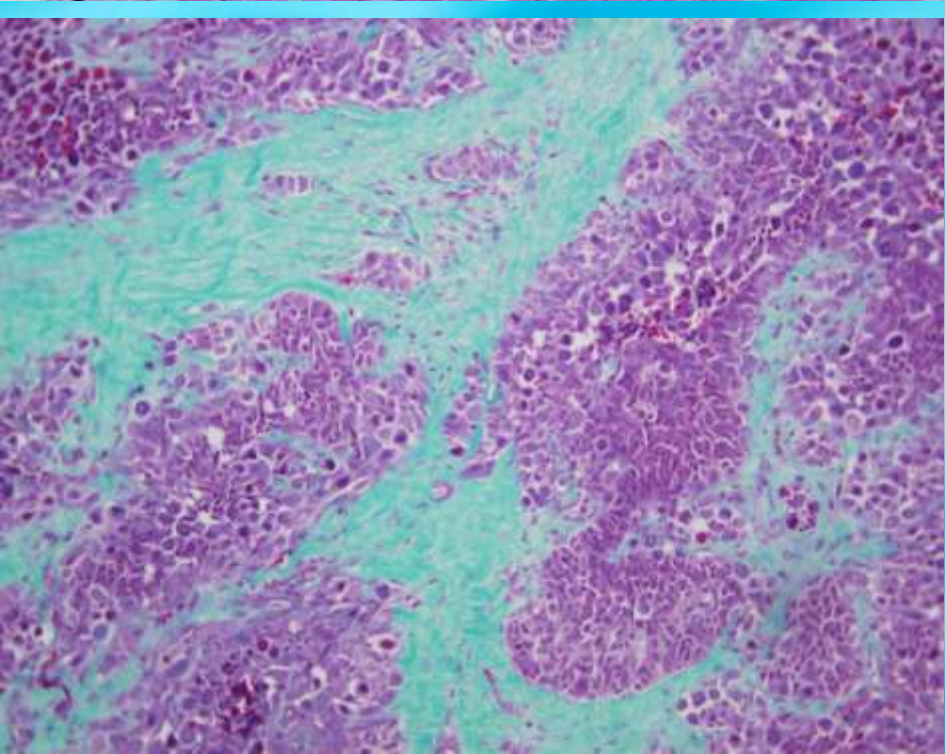
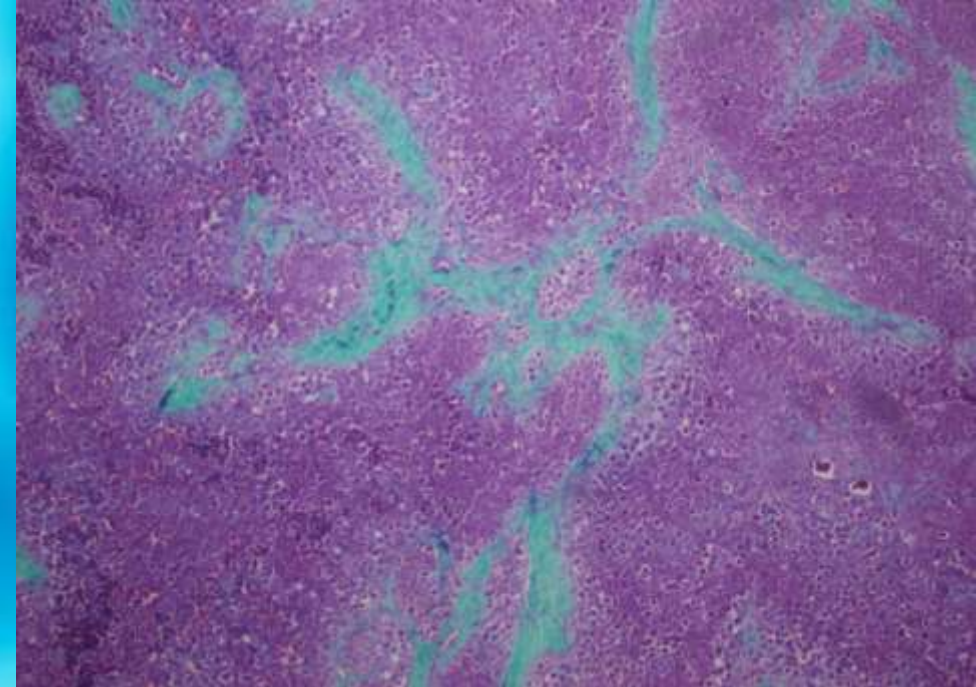
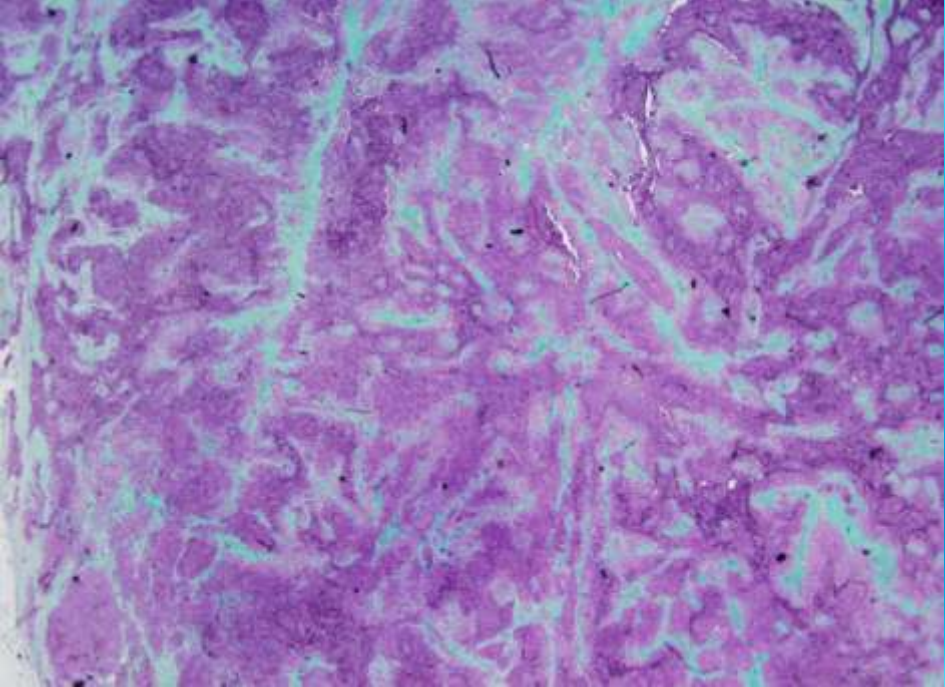


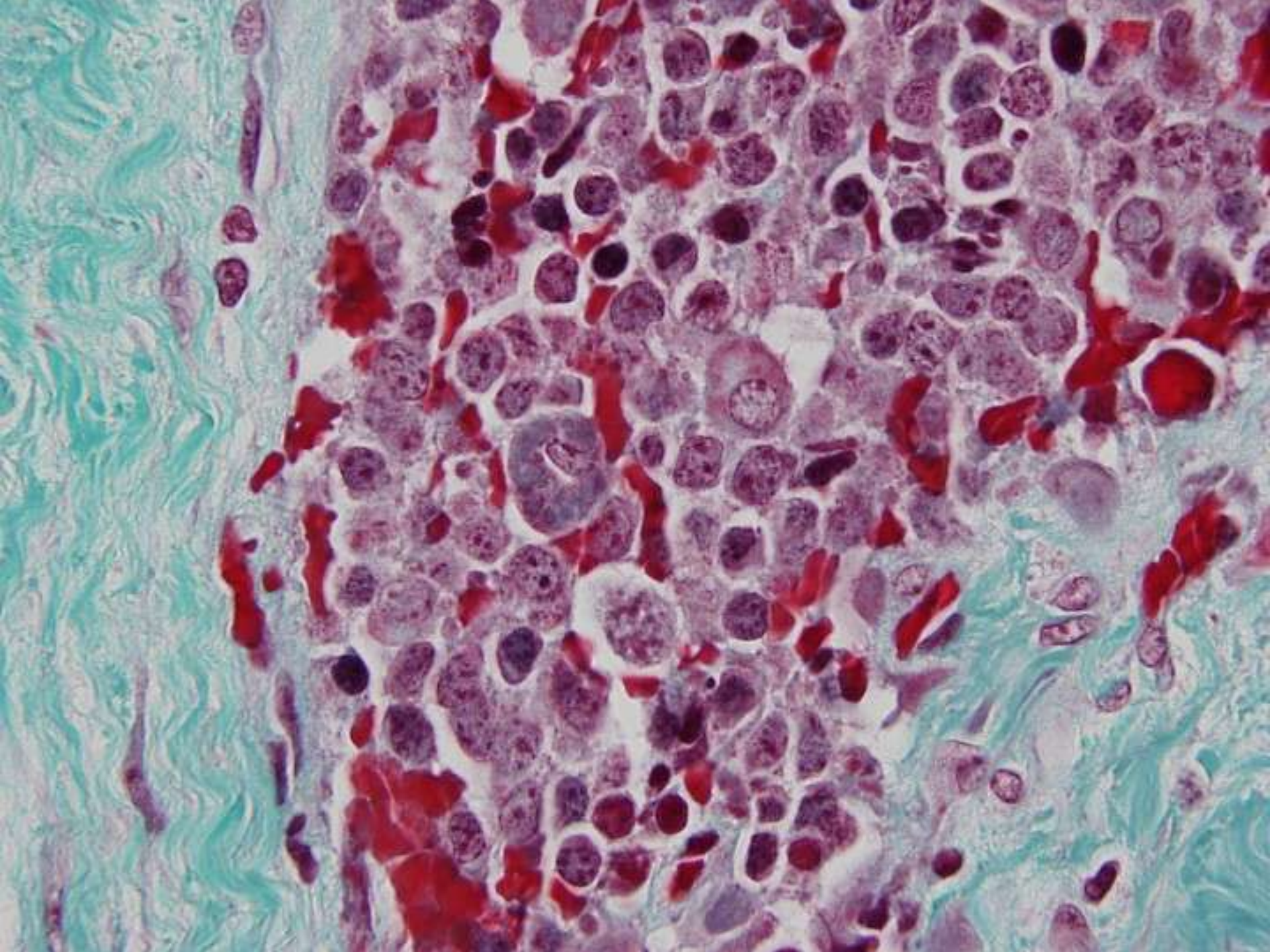


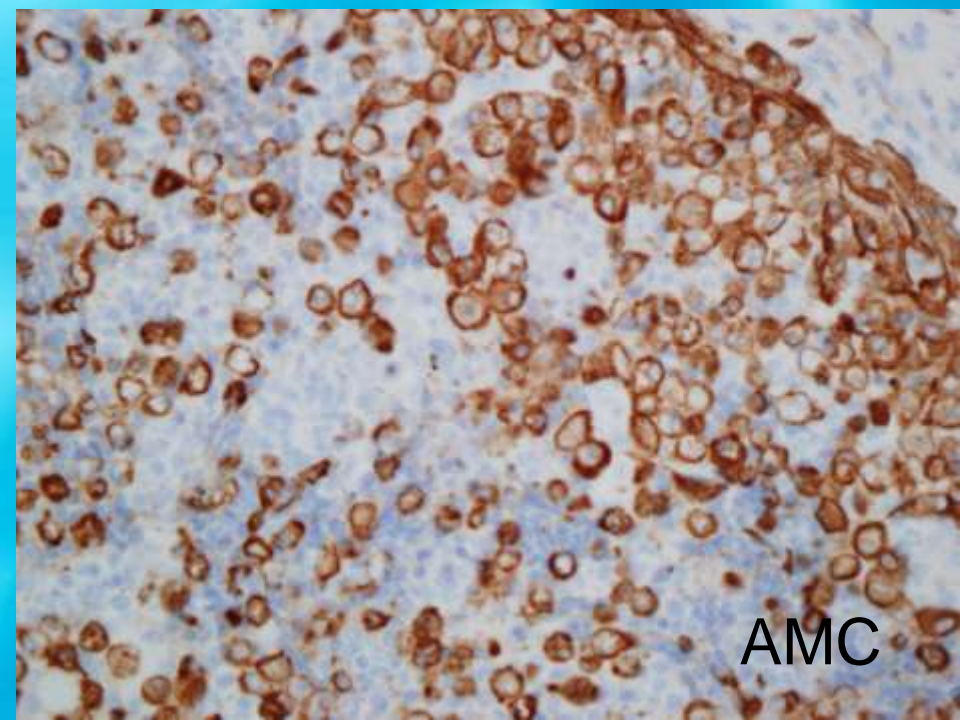
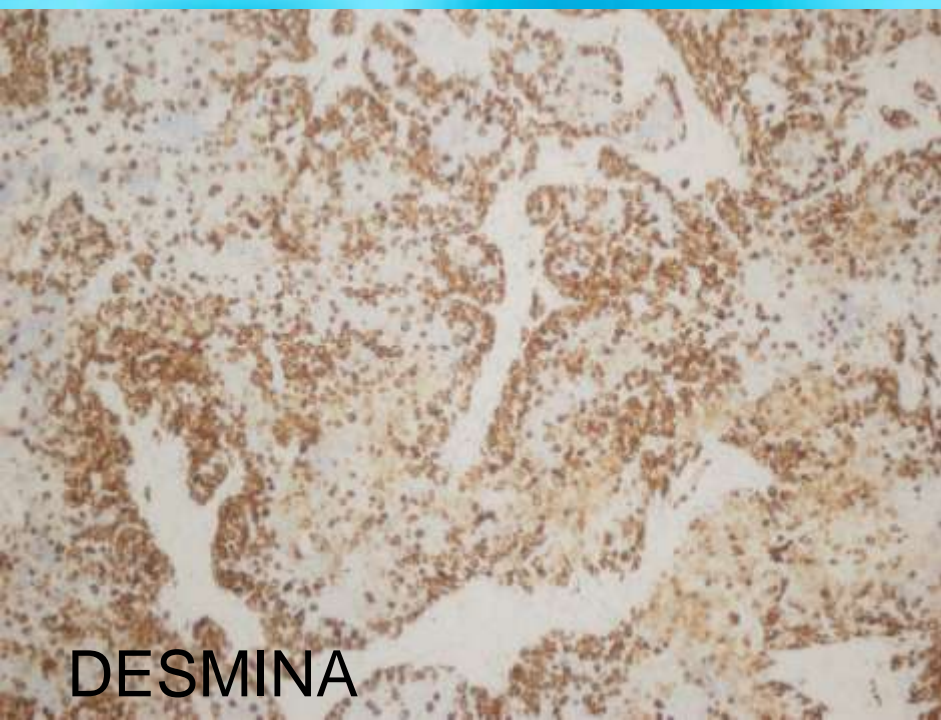
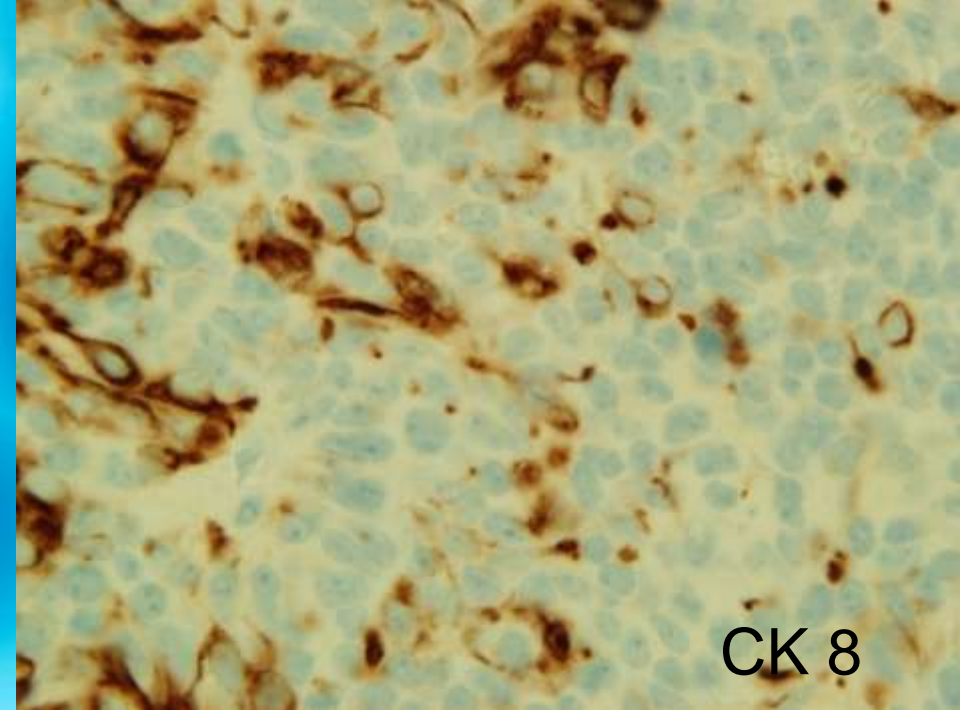
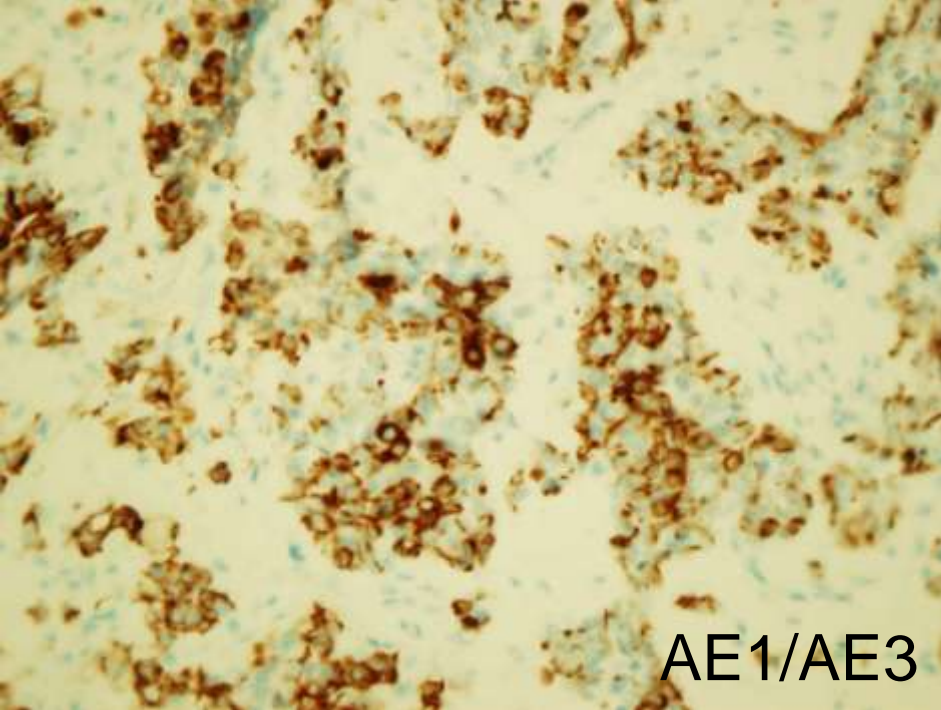
Material quirúrgico

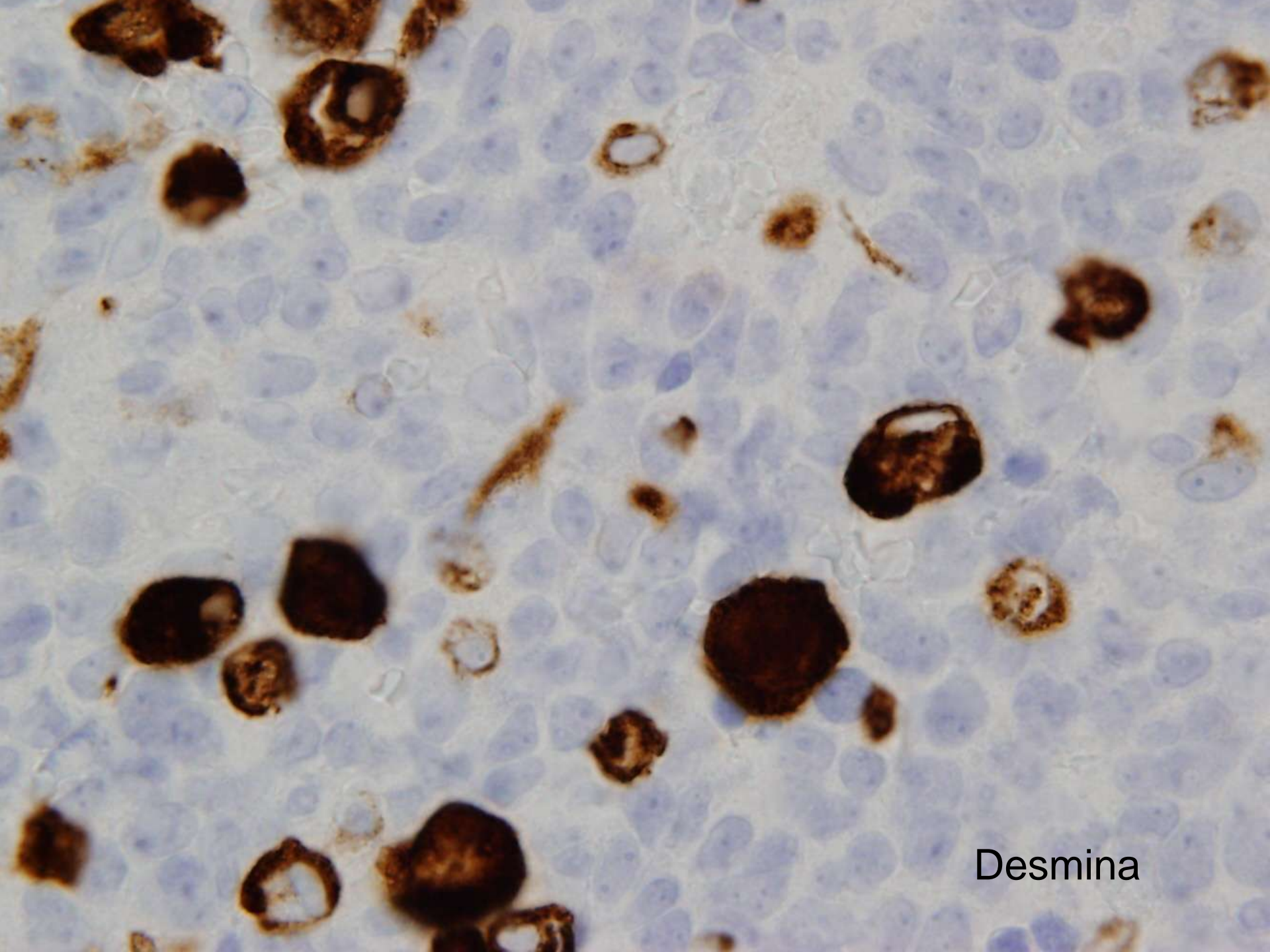
Múltiples fragmentos irregulares (6X4,5X1 cms), coloración grisáceo-granácea y consistencia media con abundantes áreas óseas



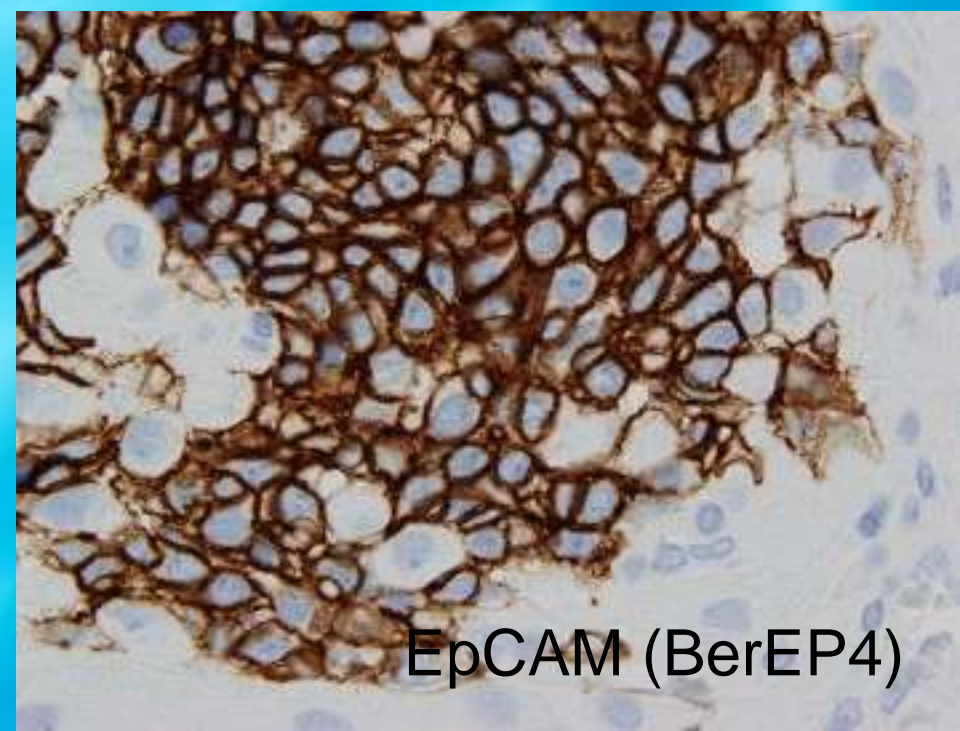
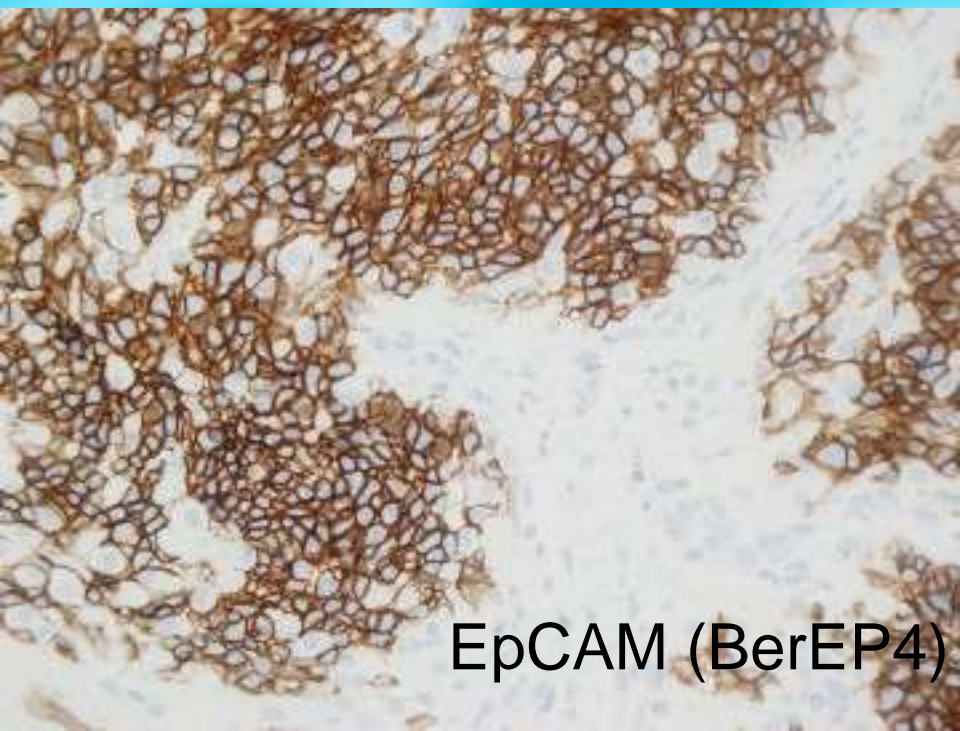
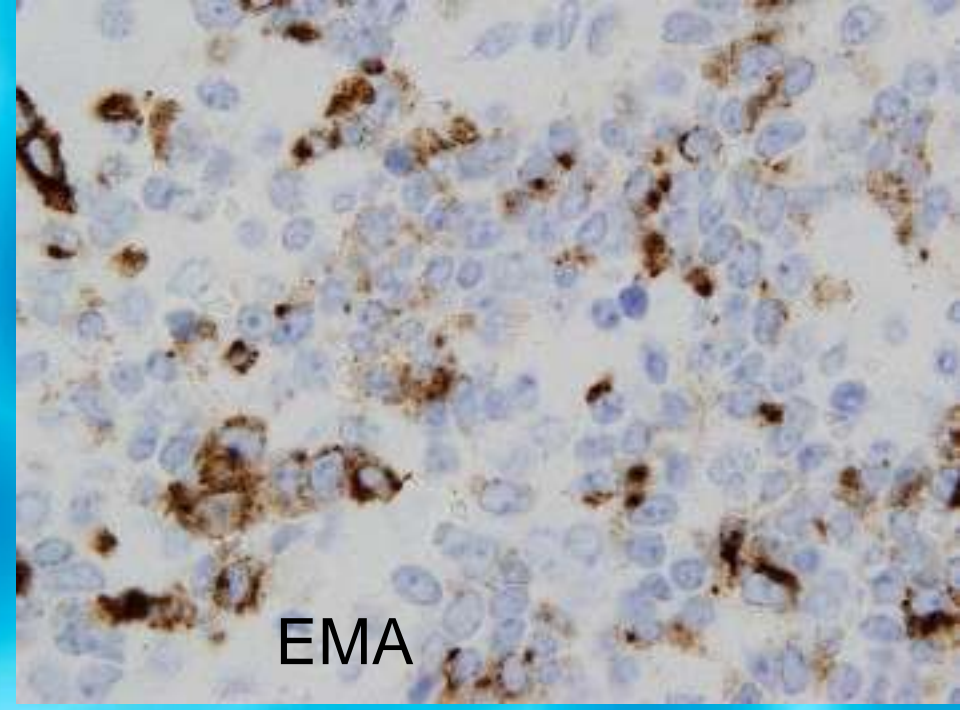
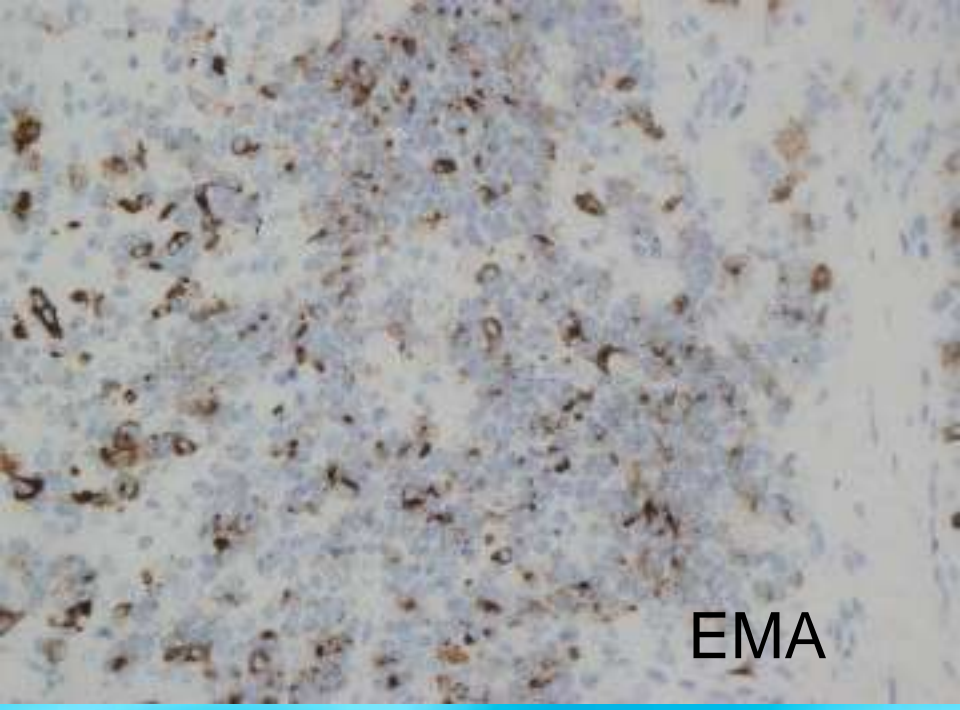


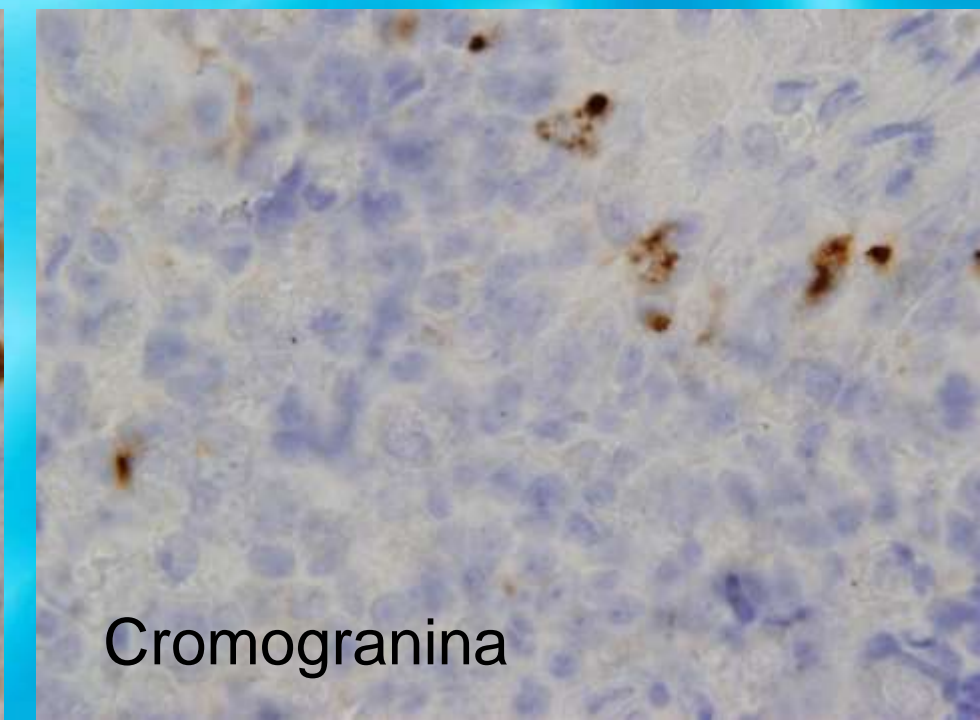
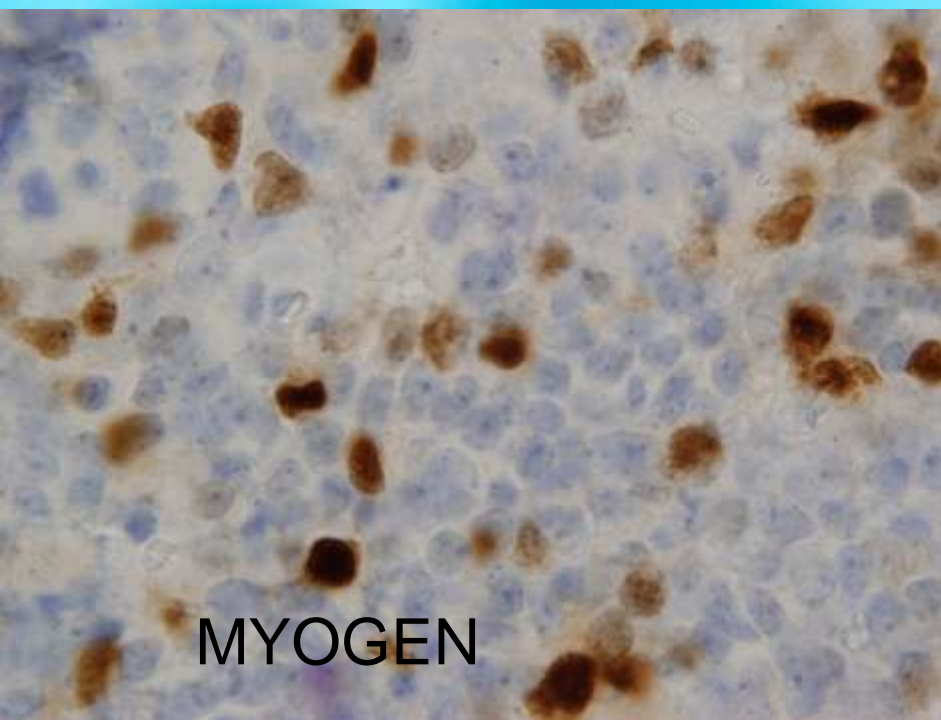
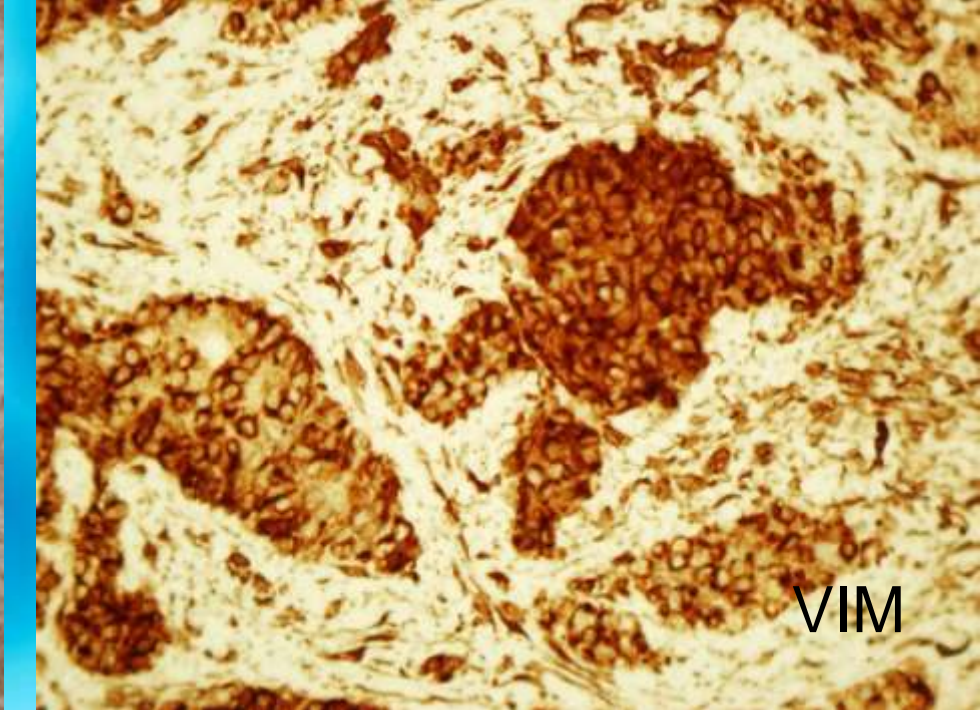
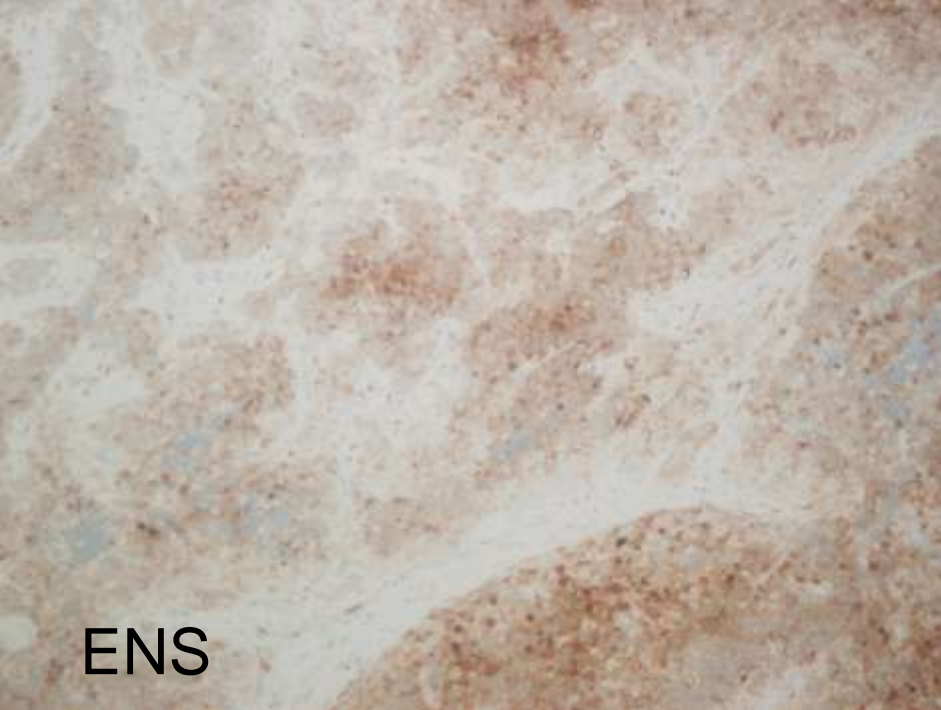


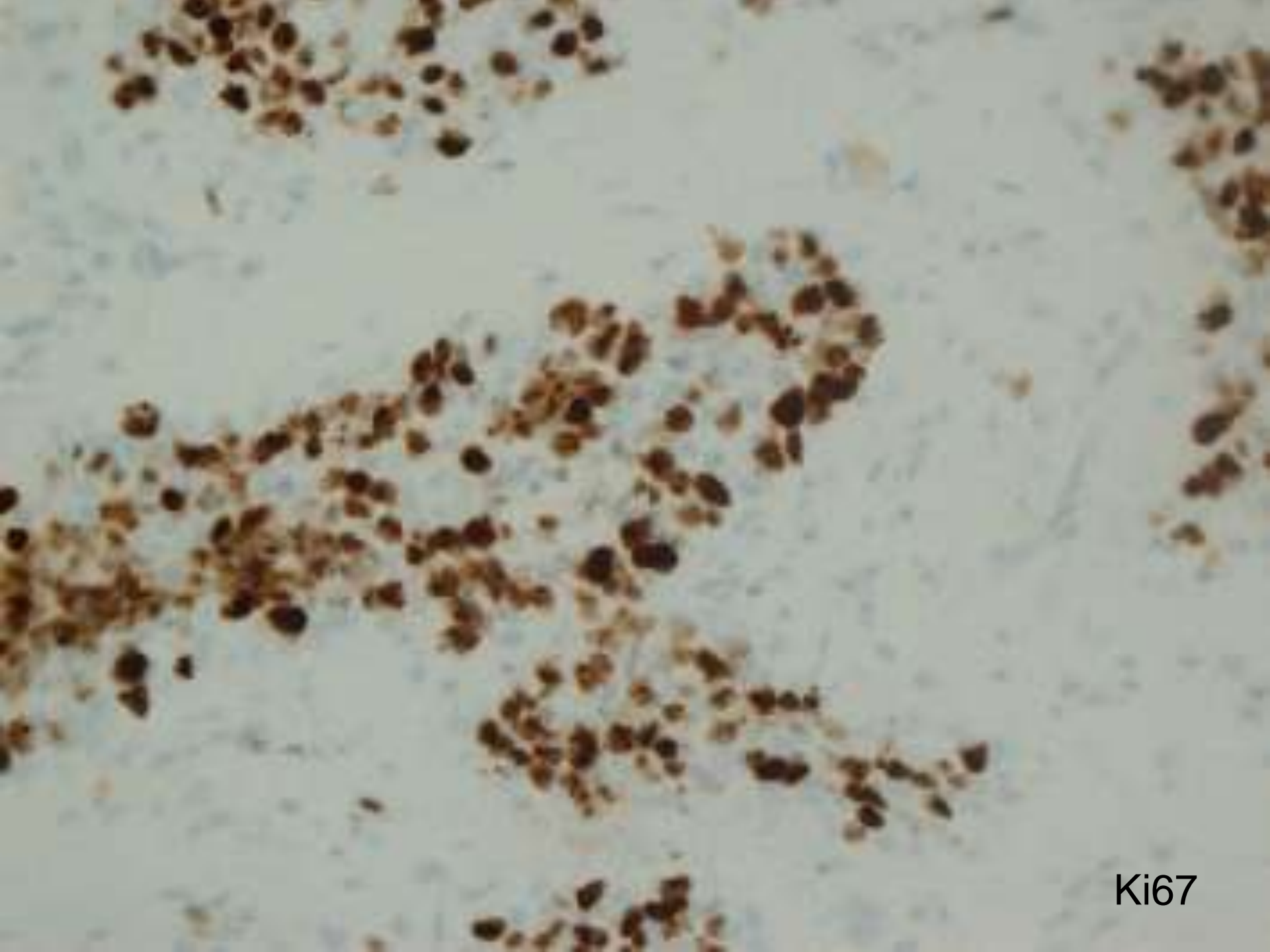




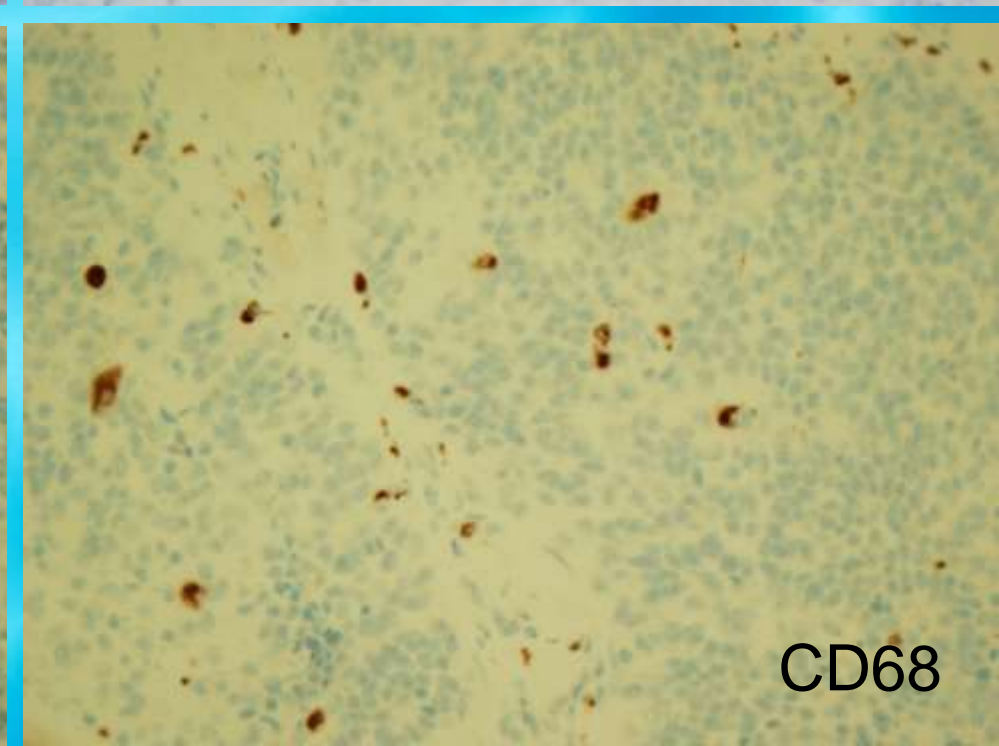
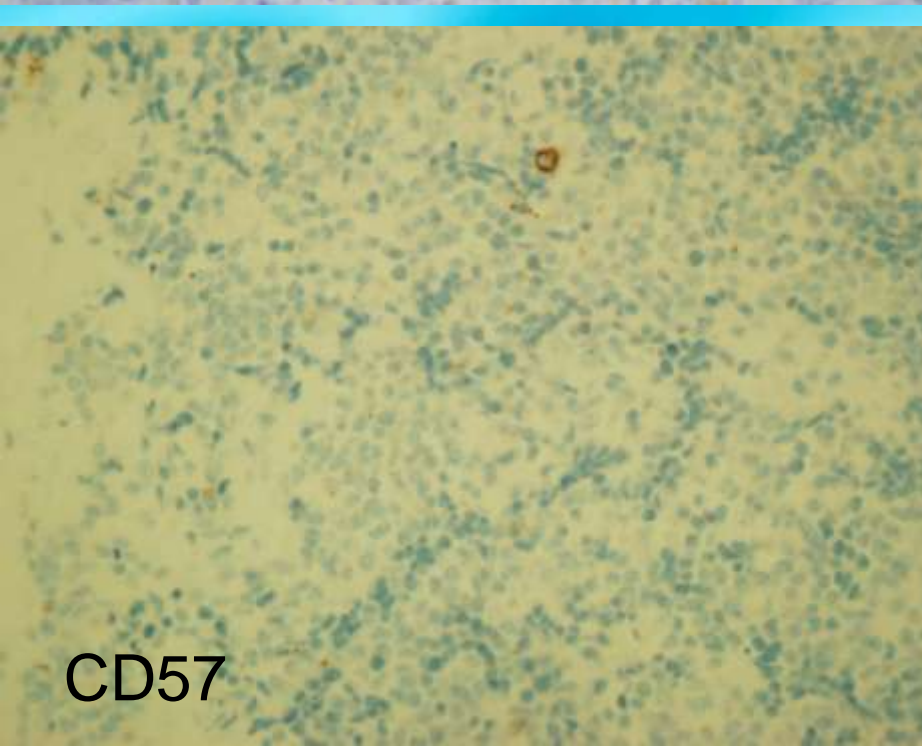
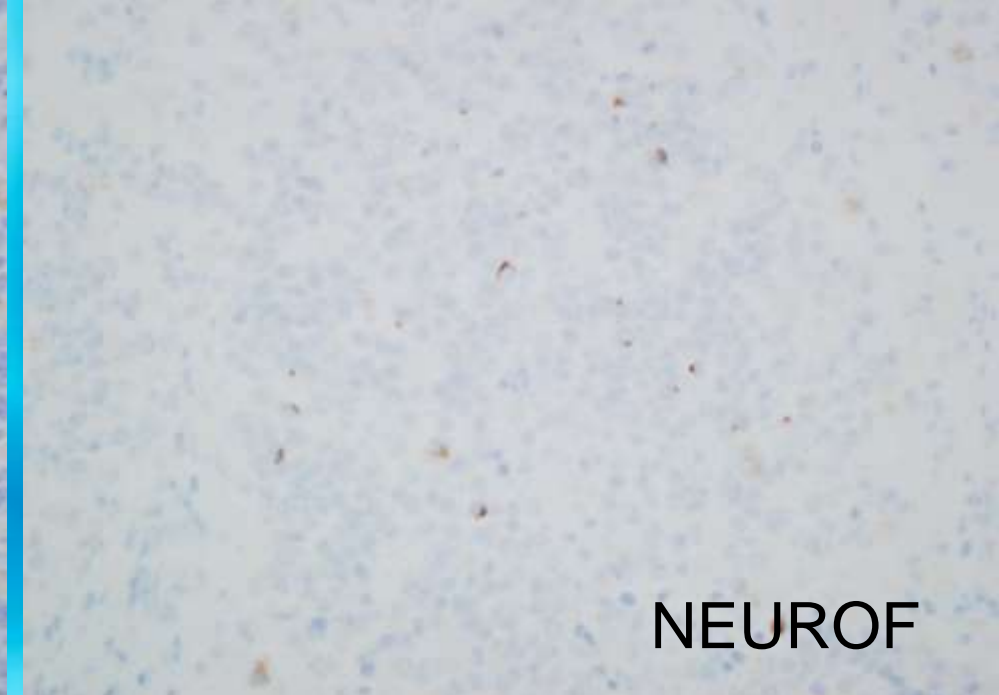
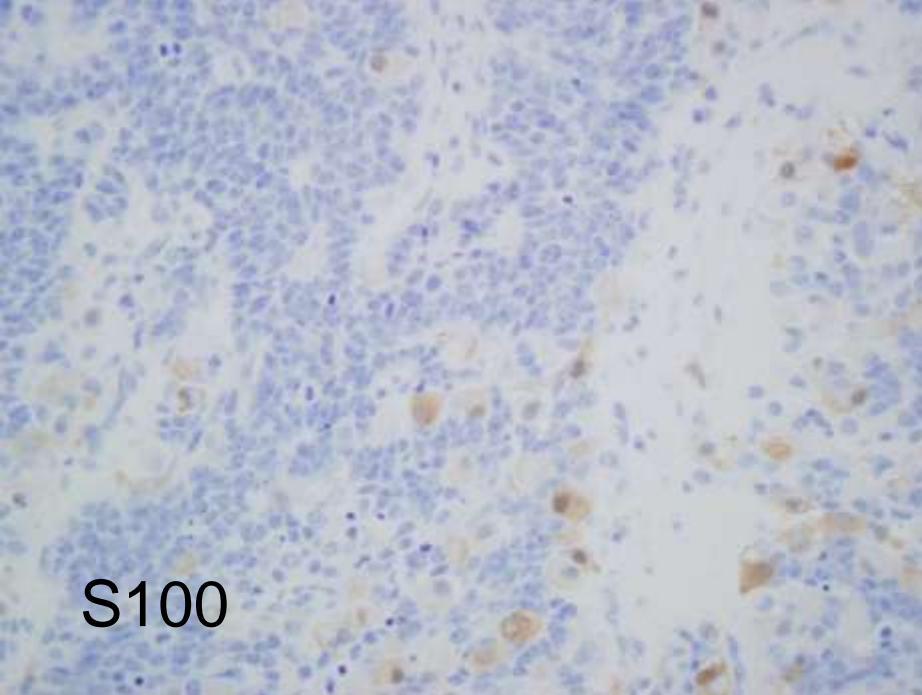
Desmina







Ki67



Perfil inmunohistoquímico

Positivo	Positivo/Negativo	Negativo
Vimentina	ENS	CD 99
Citoqueratinas: AE1/AE3	NEUROF.	<i>Sinaptofisina</i>
Ck 8		S-100
EMA		MyoD1
EpCAM (BerEP4)		PGFA
Desmina		<i>Cromogranina</i>
Miogenina		AML
AMC		CK 5/6
WT1 (citoplasm.)		ALC

Diagnóstico Anatomopatológico

Tumor desmoplásico de célula pequeña redonda nasosinusal con rasgos rhabdoides (DSRCT)

TUMOR DESMOPLASICO DE CELULA PEQUEÑA REDONDA (DSRCT)

- Posible origen mesotelial.
- Adolescentes y adultos jóvenes (media=22 años). Varones 4:1.
- Localización mas frecuente intrabdominal. **Raro en región nasosinusal**. Otros: túnica vaginal testicular, serosa uterina, ovario, pleura, SNC, etc.
- Diferenciación mesenquimal, epitelial y neural.
- Gran tamaño. Alta agresividad. Diseminación por continuidad.

American Journal of Surgical Pathology:
June 2002 - Volume 26 - Issue 6 - pp 799-803

Case Reports

Sinonasal Desmoplastic Small Round Cell Tumor: A Case Report

Finke, Nicole M. M.D.; Lae, Marick E. M.D.; Lloyd, Ricardo V. M.D.;
Gehani, Suresh K. M.D.; Nascimento, Antonio G. M.D.

Abstract

A case of sinonasal desmoplastic small round cell tumor in a 21-year-old woman is presented. The tumor possessed the diagnostic histologic, immunohistochemical, and genetic characteristics of desmoplastic small round cell tumor. Histologically, the tumor was composed of nests of tumor cells surrounded by a desmoplastic stroma. **Immunohistochemical staining was positive for keratin, vimentin, desmin, and, focally, neuron-specific enolase.** The desmin immunopositivity was of a classic dot-like perinuclear pattern. RT-PCR analysis showed the fusion transcript resulting from the t(11;22)(p13;q12) reciprocal translocation. This case of sinonasal desmoplastic small round cell tumor, the third reported case not associated with a serosal surface, further obscures the nature and histogenesis of this entity.

American Journal of Surgical Pathology:
November 1998 - Volume 22 - Issue 11 - pp 1303-1313

Original Articles

Desmoplastic Small Round Cell Tumor: I: A Histopathologic Study of 39 Cases with Emphasis on Unusual Histological Patterns

Ordóñez, Nelson G. M.D.

Abstract

The clinical and histological features of 39 cases of desmoplastic small round cell tumor (DSRCT) diagnosed at M.D. Anderson Cancer Center are presented. Thirty-two of the patients were men and seven were women ranging in age from 10 to 41 years (mean, 25 years). Twenty-five of the 35 patients for whom follow-up information was available died of widespread metastases 8 to 50 months (mean, 25.2 months) from the time of their diagnosis and the remaining 10 were alive with disease. With the exception of two cases that occurred in the liver and in the scrotum, respectively, all of the cases originated within the abdominal and/or pelvic peritoneum. Eight tumors also involved the retroperitoneum. Although the characteristic histologic pattern of "small, blue cells" embedded in a dense fibrous stroma was seen in most cases, about one third of the tumors exhibited a wide range of morphologic features. **The recognition of these uncommon morphologic variants of DSRCT is of paramount importance to avoid a misdiagnosis because these tumors could potentially be confused with other neoplastic conditions.**

© 1998 Lippincott Williams & Wilkins, Inc.

• Inmunohistoquímica:

Positivo	Positivo/Negativo	Negativo
<u>Queratina</u>	NSE	Actina antimúsculo específica
<u>Desmina</u>	Leu-7	Actina α de musculo liso
<u>Vimentina</u>	Sinaptofisina	Neurofilamento
EMA	Cromogranina	S-100

• Translocación t(11;22), (p13;q12), EWS/WT1

• **No se pudo demostrar la presencia de translocación EWS-WT1 (PCR)**

DIAGNOSTICO DIFERENCIAL

1. **PNET-Sarcoma de Ewing:** Diferenciación neural. CD99 positivo. t(11;22)(q24;q12).
2. **Linfoma no Hodgkin:** LCA positivo.
3. **Carcinoma de célula pequeña:** Desmina negativa.
4. **Osteosarcoma de célula pequeña:** Ck y desmina negativas.
5. **Rabdomiosarcoma:** MyoD1, HHF35 y miogenina positivas.
6. **Tumor rhabdoide extrarenal**

DIAGNOSTICO DIFERENCIAL

- Neuroblastoma olfatorio (estesioneuroblasoma)
 - Estroma desmoplásico
 - Positividad intensa para ENS y synaptofisina
 - 1/3 positivos para CK 8 y desmina
 - EMA negativo