



# NEUROPATHOLOGY CASE PRESENTATIONS

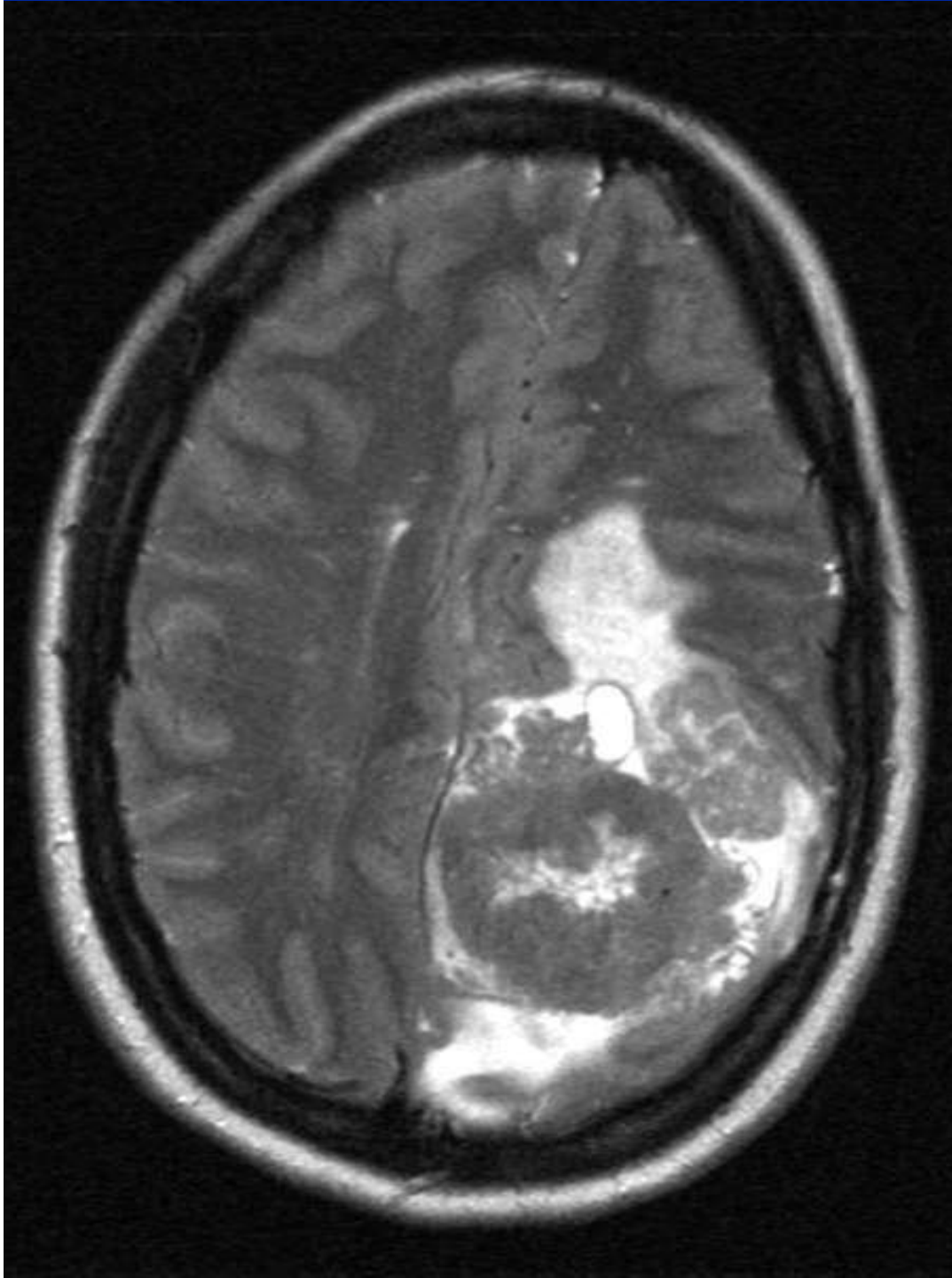
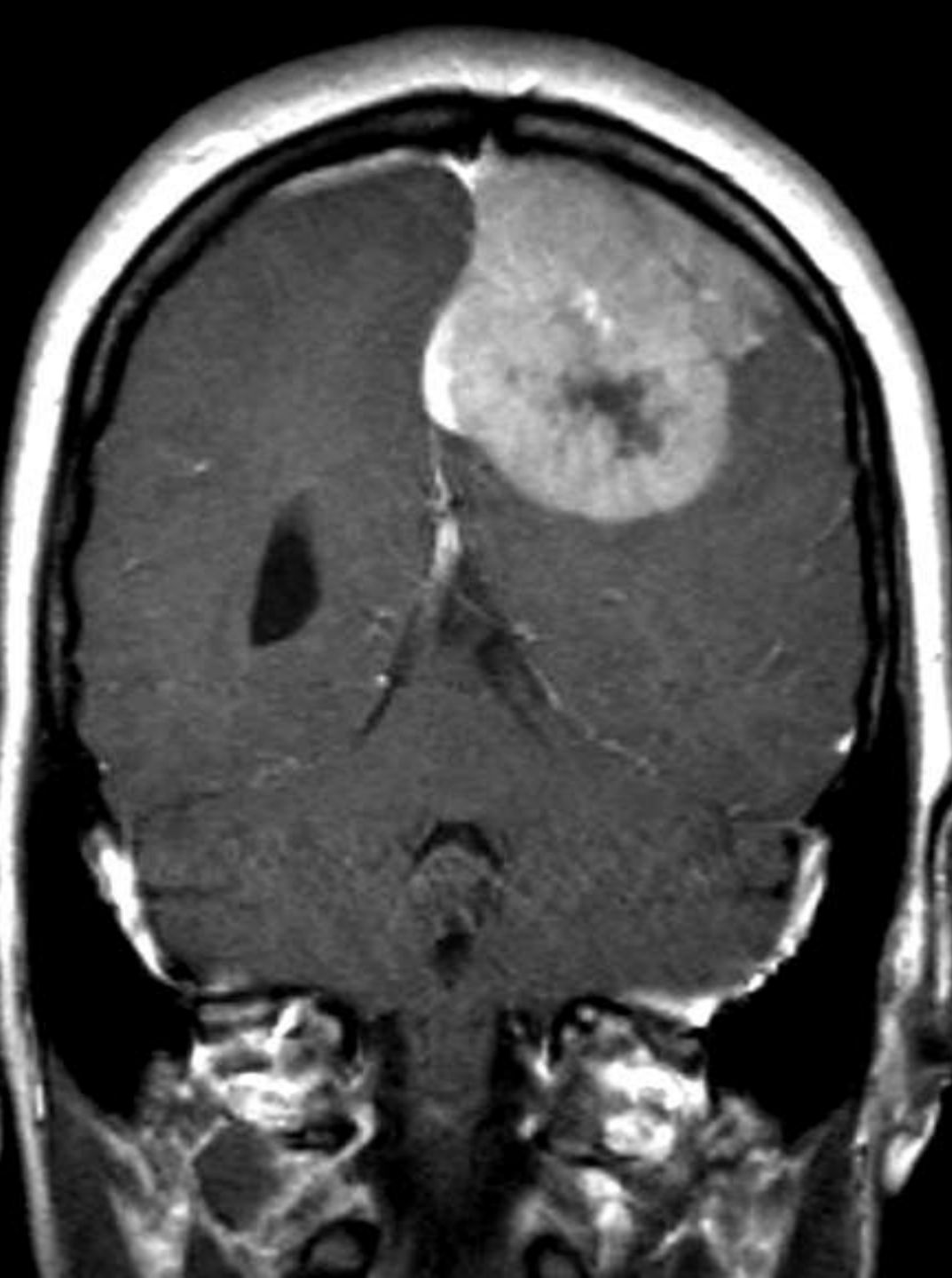Arie Perry, M.D.

Director, Neuropathology Division

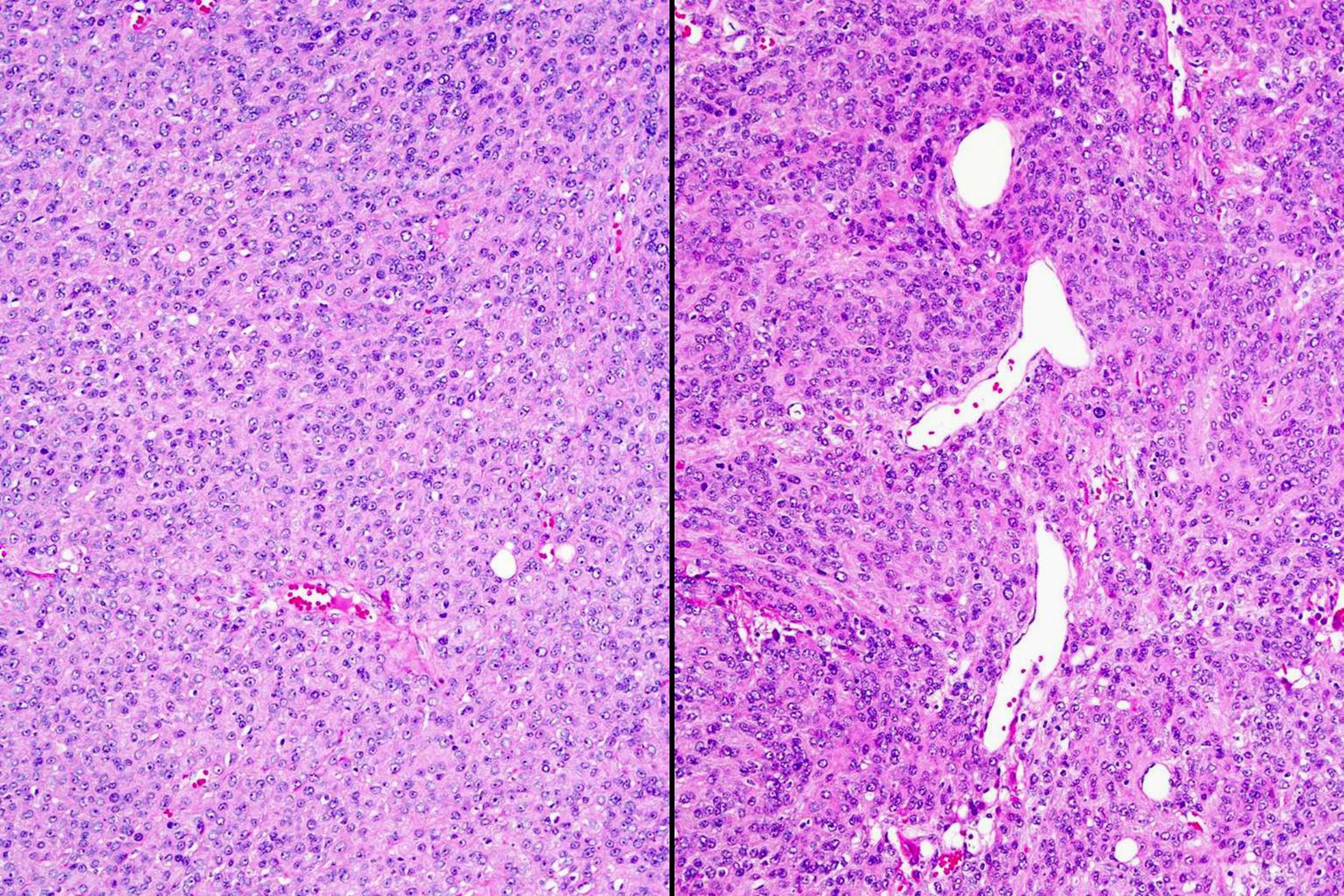


## NP CASE 3

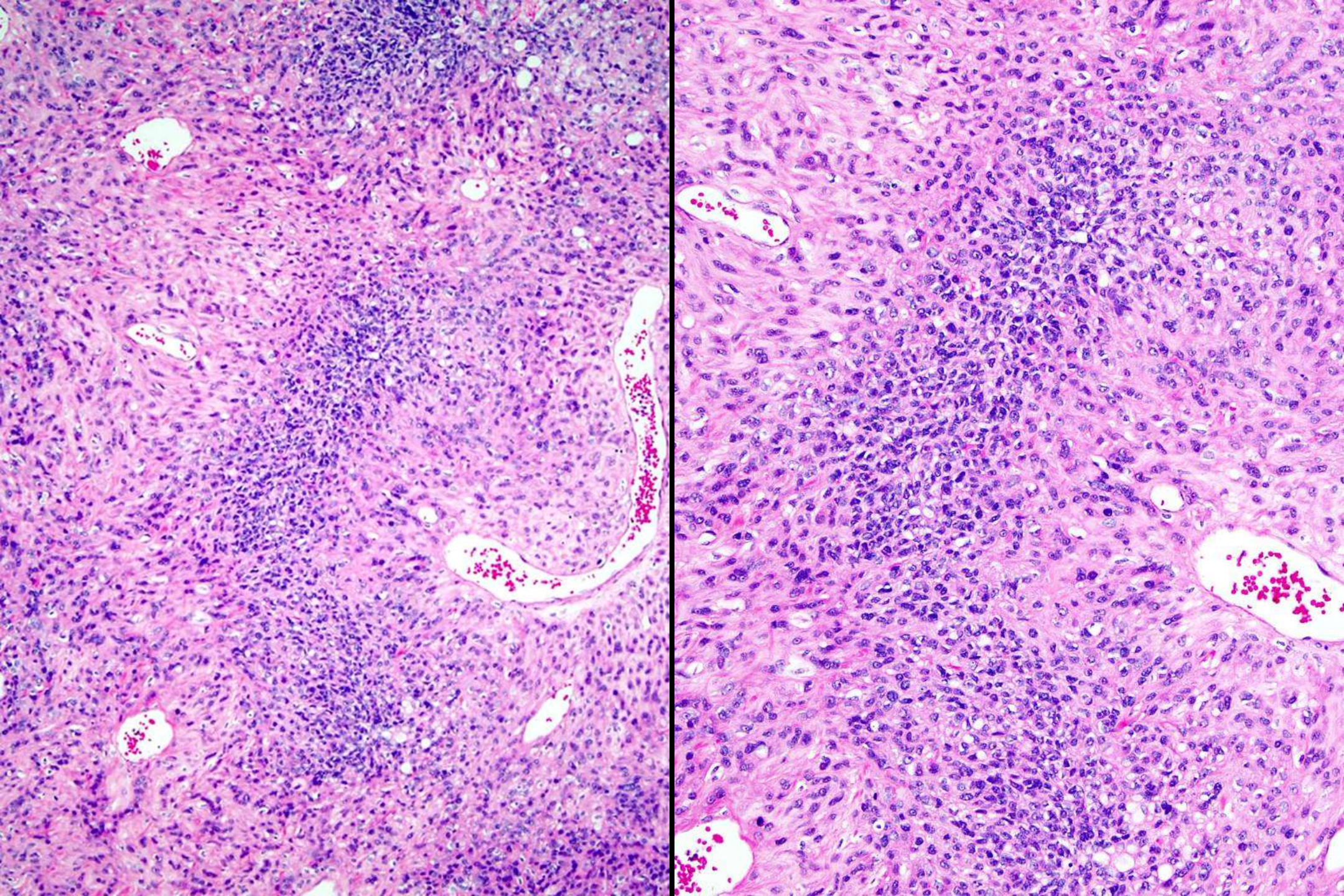
- 33-yo F with HA, N/V, and blurred vision x 5-6 months
- MRI revealed an enhancing L parietal dural-based mass



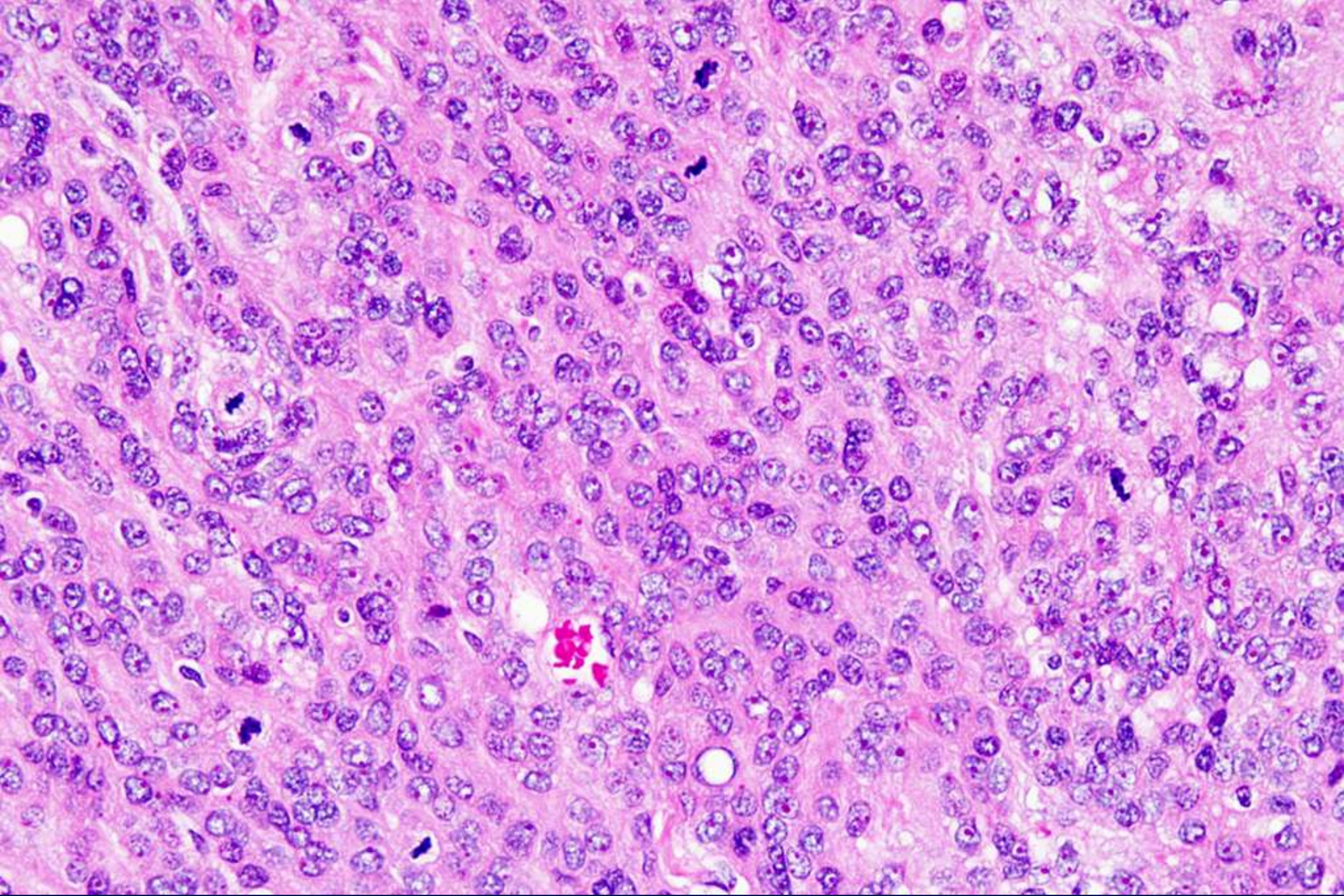




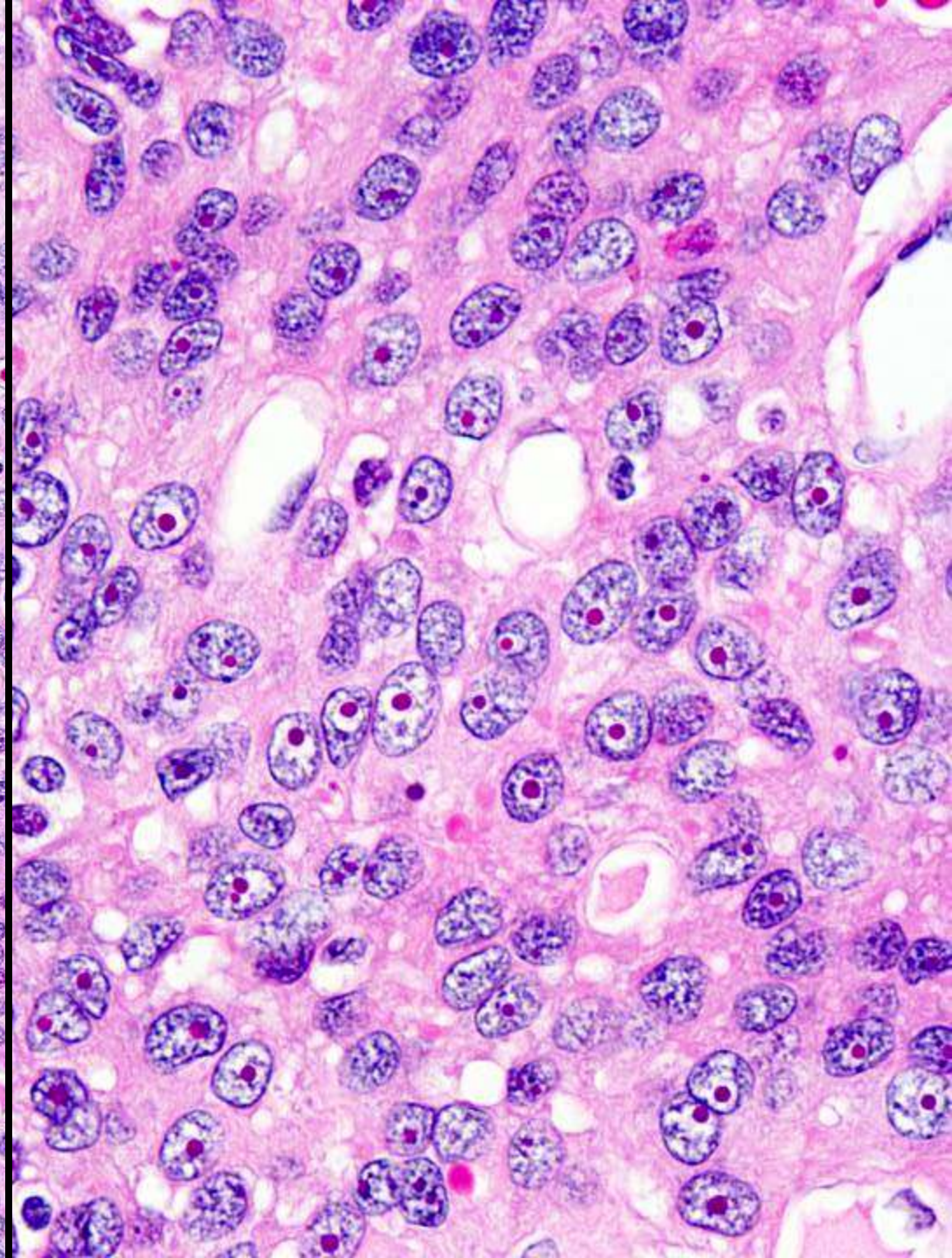
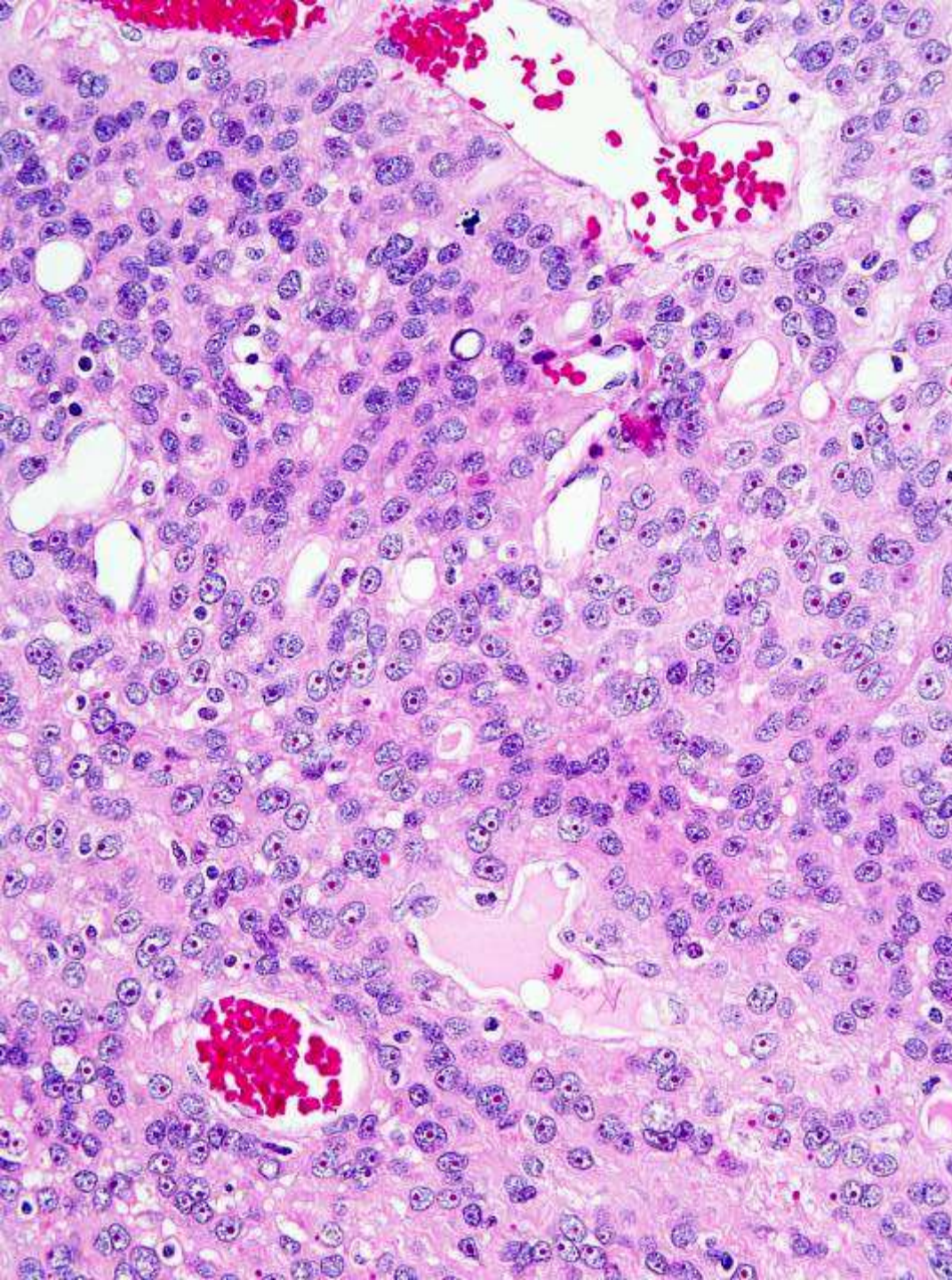




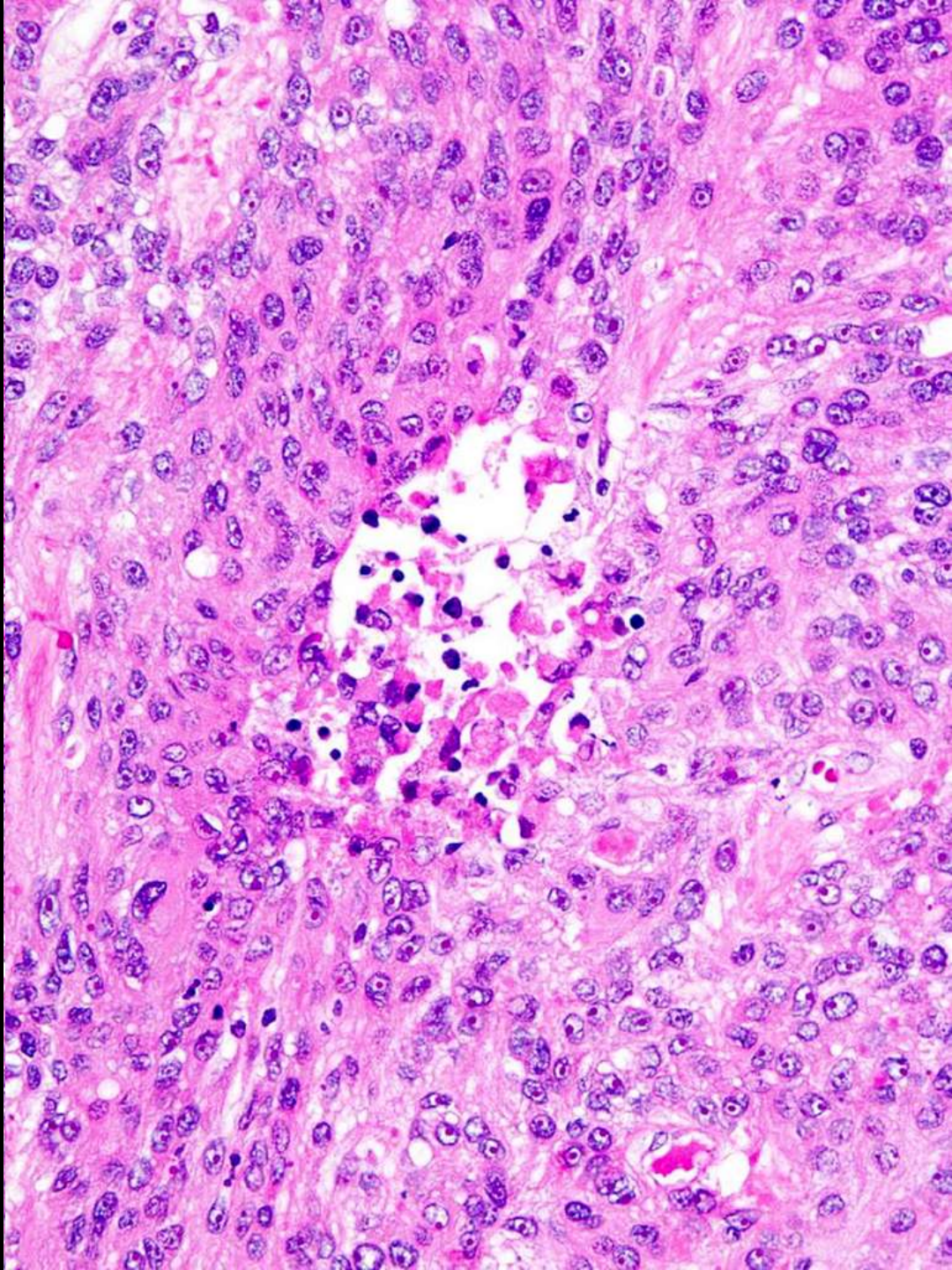
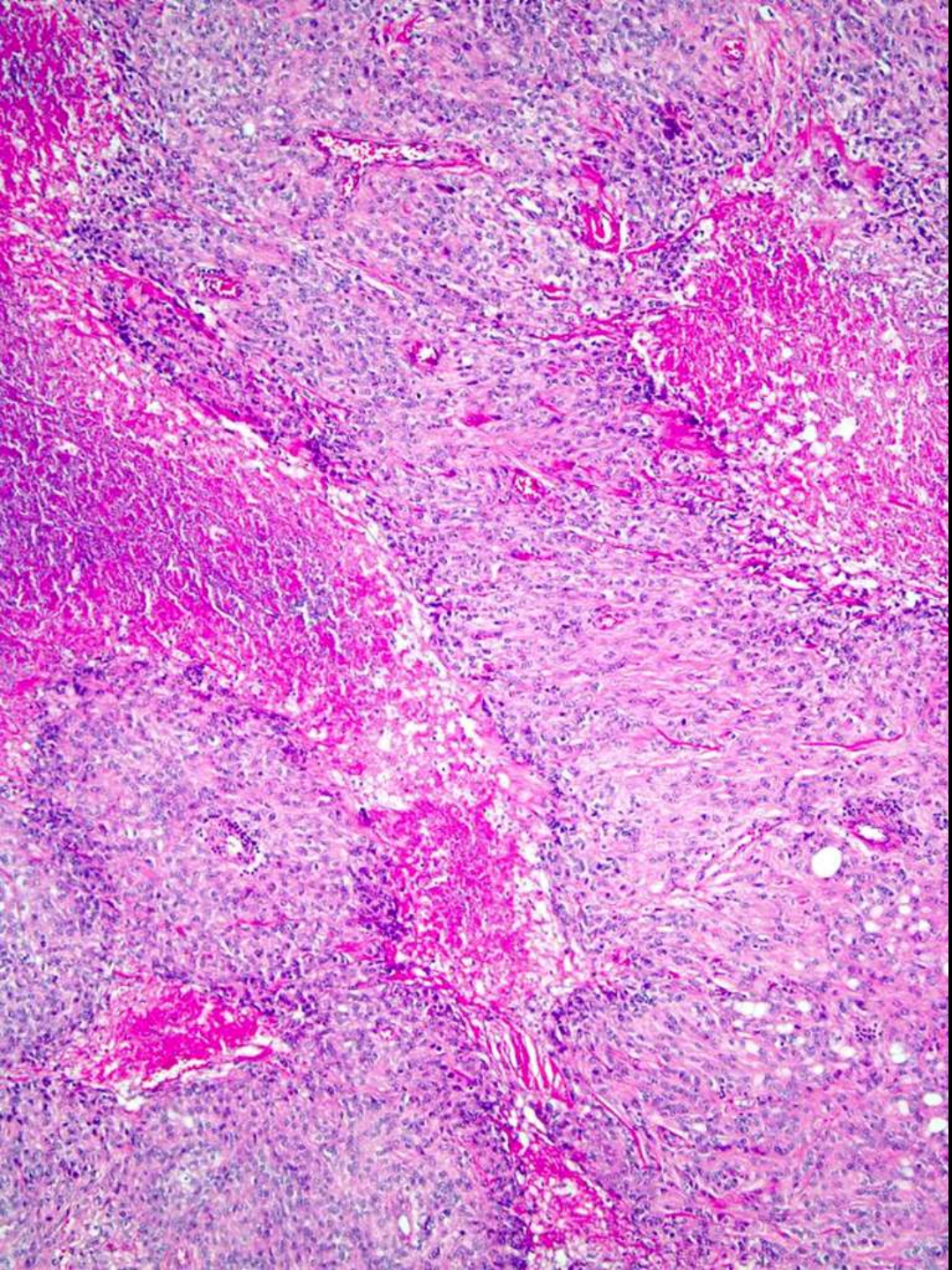




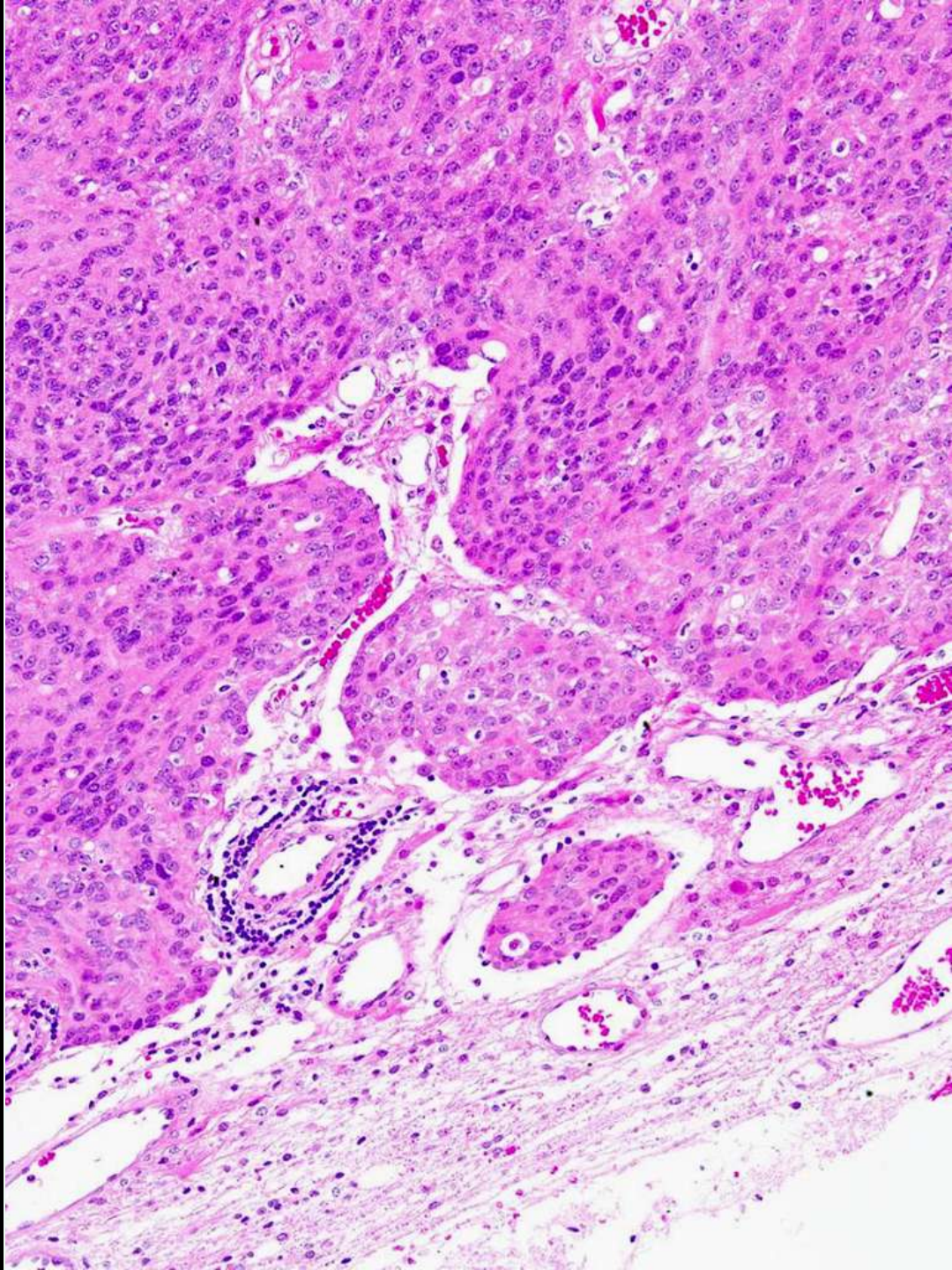
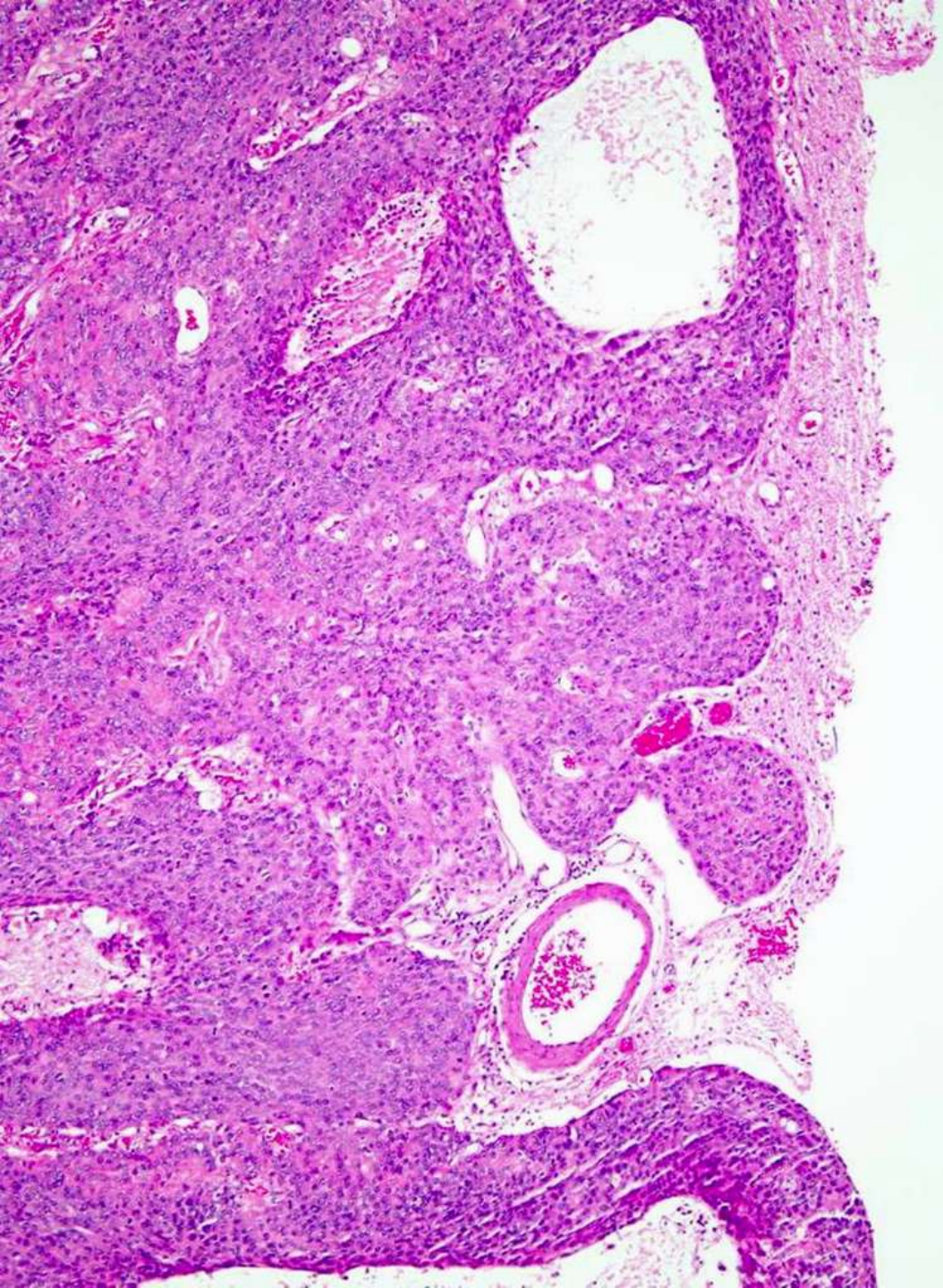


















# WHICH PATTERN(S)?

- Parenchymal Infiltrate with Hypercellularity
  - Solid Mass (Pure)
  - Solid and Infiltrative Process
  - Vasculocentric Process
  - Extra-axial Mass
  - Meningeal Infiltrate
  - Destructive/Necrotic Process
  - Subtle Pathology or Near Normal Biopsy
- 





# WHICH PATTERN(S)?

- Parenchymal Infiltrate with Hypercellularity
  - Solid Mass (Pure)
  - Solid and Infiltrative Process
  - Vasculocentric Process
  - **Extra-axial Mass**
  - Meningeal Infiltrate
  - Destructive/Necrotic Process
  - Subtle Pathology or Near Normal Biopsy
- 



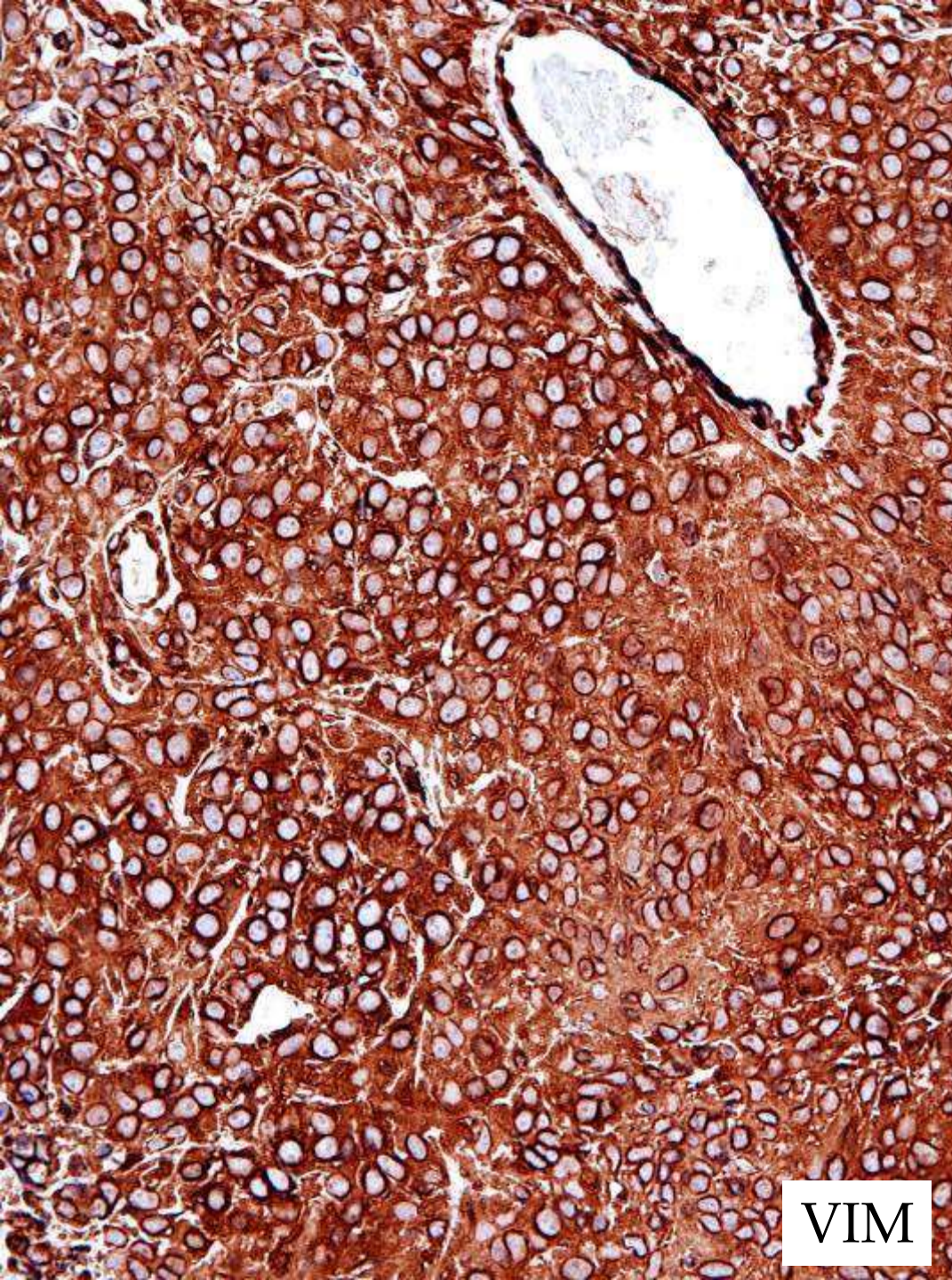


# WHAT IS YOUR FAVORED DIAGNOSIS?

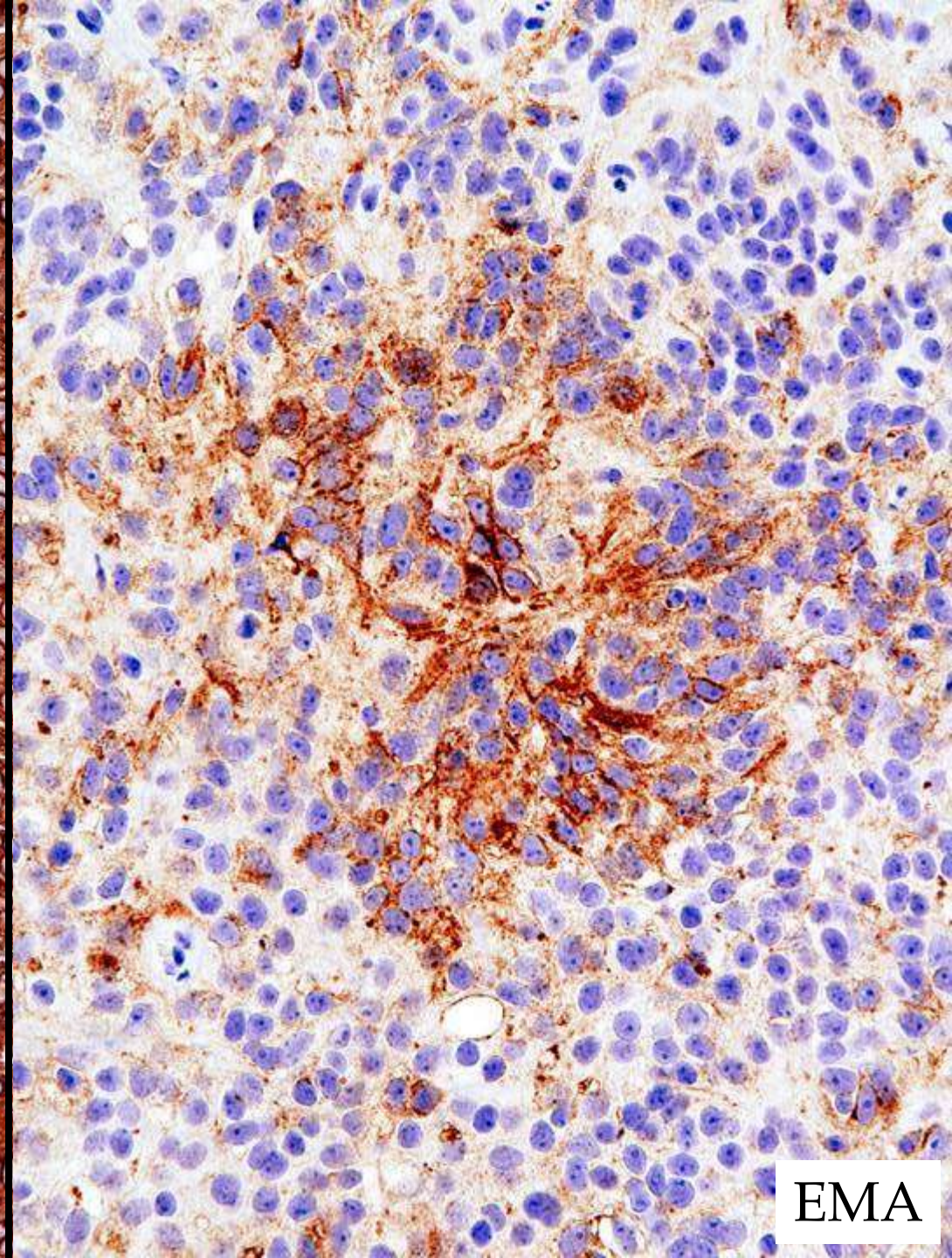
- Anaplastic meningioma, WHO grade III
- Metastatic carcinoma or melanoma





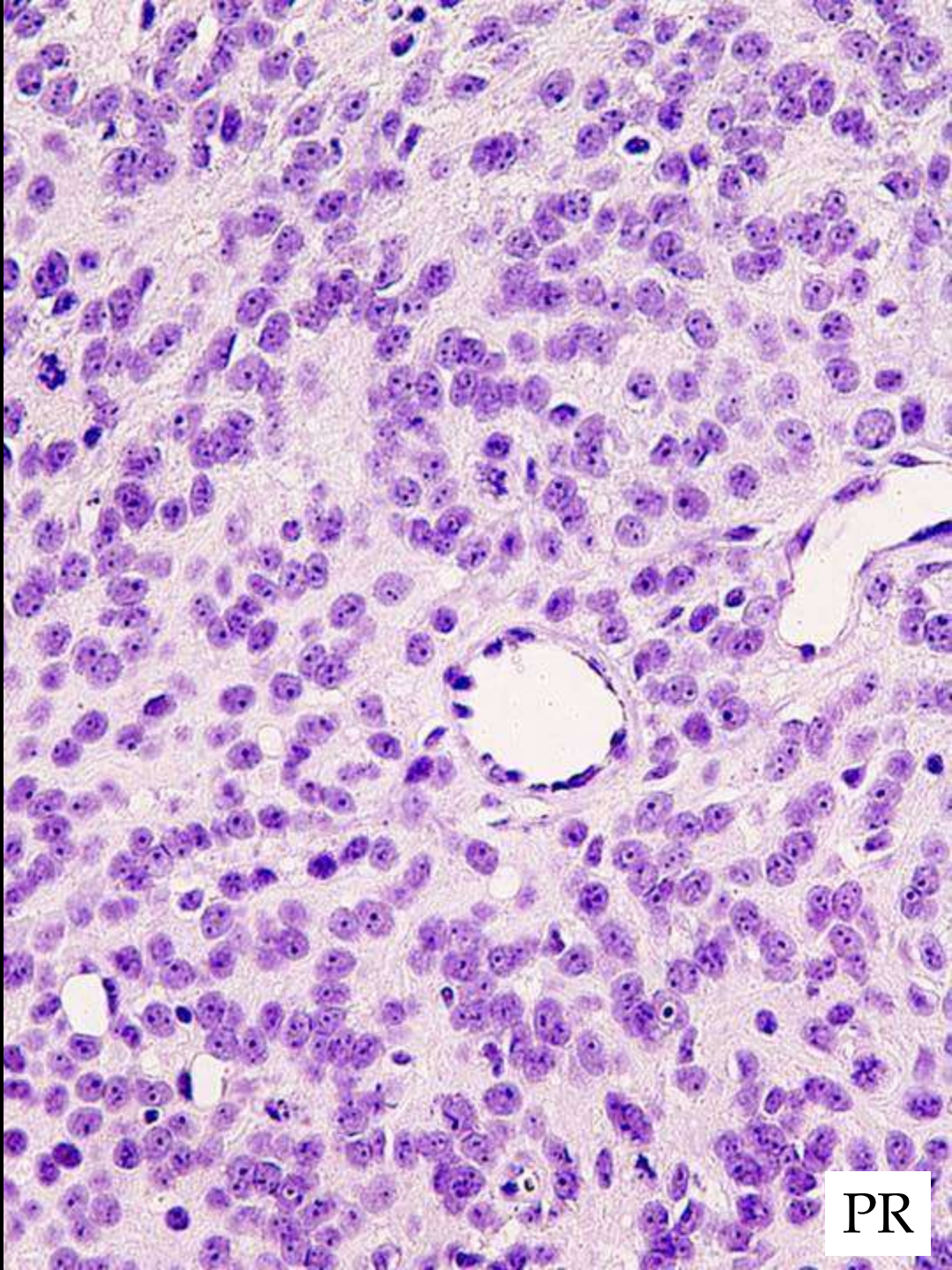
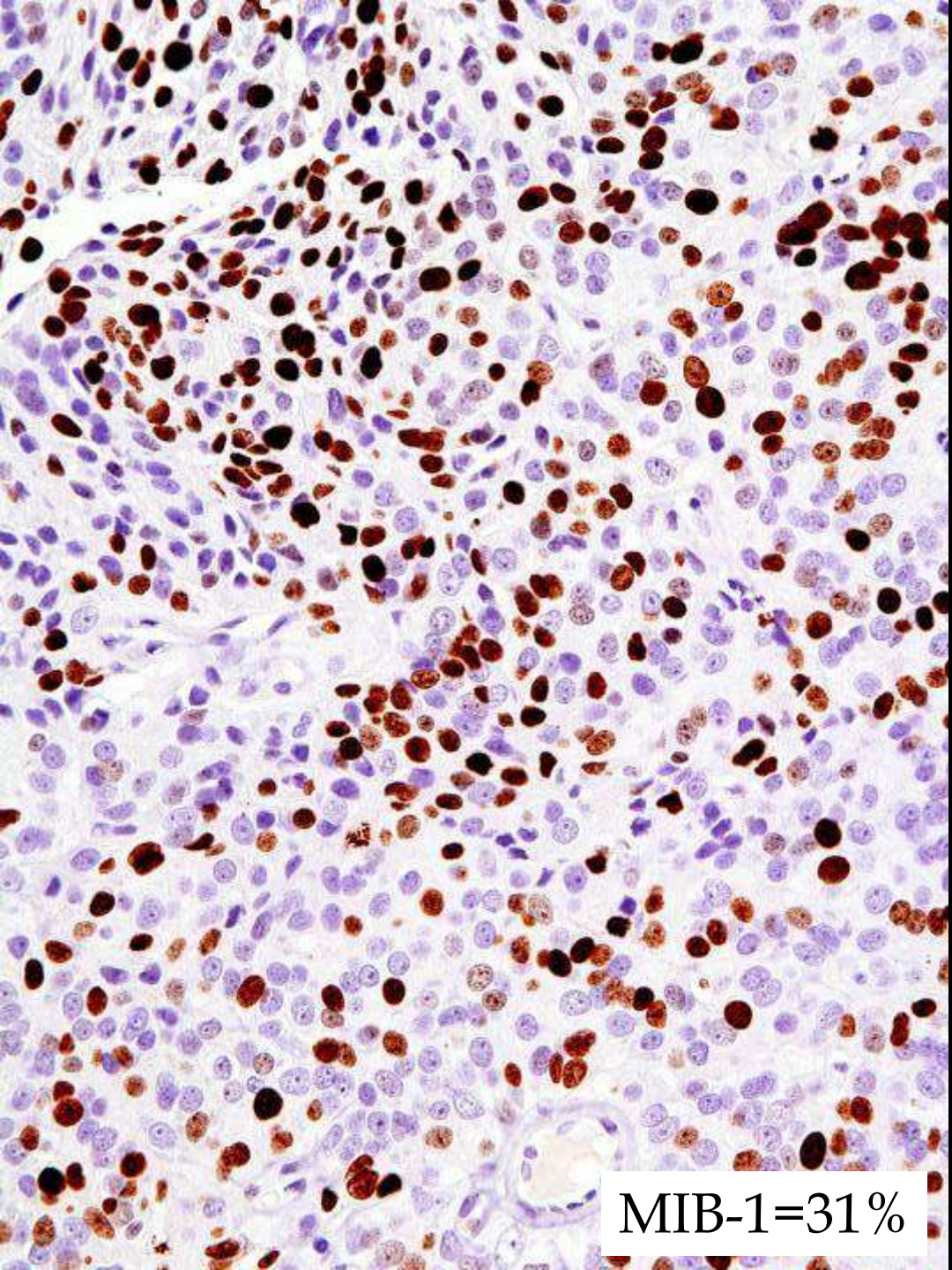


VIM




EMA








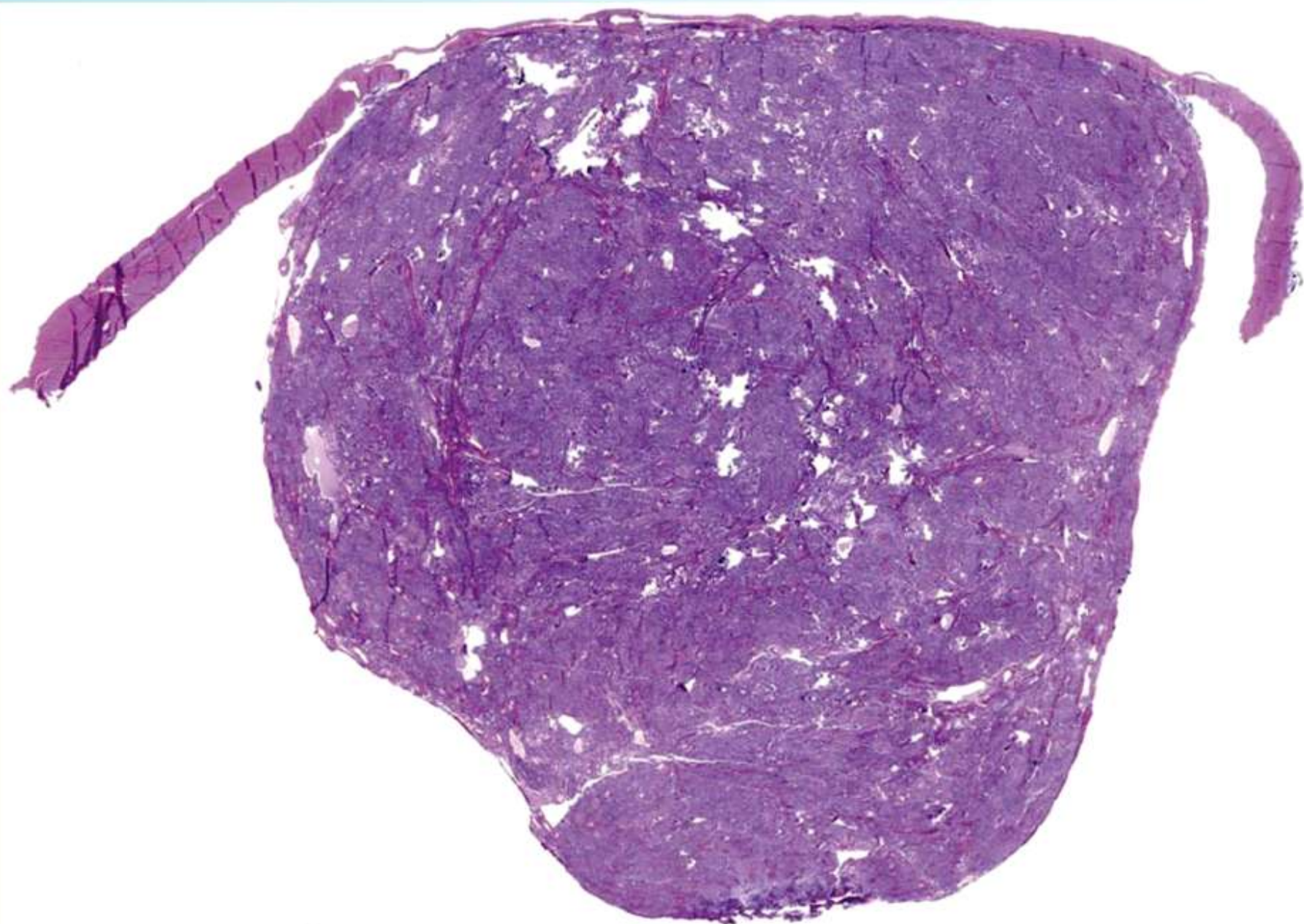


DX: ANAPLASTIC MENINGIOMA,  
WHO GRADE III





## Pattern 5: Extra-axial Mass





Additional Findings	Diagnostic Considerations	Chapter/page
Small primitive cells	<ul style="list-style-type: none"> <li>Hemangiopericytoma</li> <li>Other sarcomas (EWS/pPNET)</li> <li>Metastatic carcinoma (small cell)</li> <li>Secondary lymphomas/leukemias</li> </ul>	<ul style="list-style-type: none"> <li>(Ch. 11)</li> <li>(Ch. 11)</li> <li>(Ch. 13)</li> <li>(Ch. 14)</li> </ul>
Large anaplastic cells	<ul style="list-style-type: none"> <li>→ Anaplastic meningioma</li> <li>Metastatic carcinoma</li> <li>Anaplastic large cell lymphoma</li> <li>Myeloid sarcoma</li> <li>Melanoma</li> </ul>	<ul style="list-style-type: none"> <li>(Ch. 10)</li> <li>(Ch. 13)</li> <li>(Ch. 14)</li> <li>(Ch. 14)</li> <li>(Ch. 16)</li> </ul>
Epithelioid cells	<ul style="list-style-type: none"> <li>→ Meningioma</li> <li>Metastatic carcinoma</li> <li>Paraganglioma</li> <li>Melanoma</li> <li>Pituitary adenoma</li> </ul>	<ul style="list-style-type: none"> <li>(Ch. 10)</li> <li>(Ch. 13)</li> <li>(Ch. 13)</li> <li>(Ch. 16)</li> <li>(Ch. 18)</li> </ul>
Clear cells	<ul style="list-style-type: none"> <li>Hemangioblastoma</li> <li>Clear cell meningioma</li> <li>Hemangiopericytoma</li> <li>Other sarcomas (leiomyosarcoma)</li> <li>Metastatic carcinoma</li> <li>Paraganglioma</li> <li>Histiocytic disorders</li> </ul>	<ul style="list-style-type: none"> <li>(Ch. 20)</li> <li>(Ch. 10)</li> <li>(Ch. 11)</li> <li>(Ch. 11)</li> <li>(Ch. 13)</li> <li>(Ch. 13)</li> <li>(Ch. 14)</li> </ul>
Foamy cells	<ul style="list-style-type: none"> <li>Hemangioblastoma</li> <li>Angiomatous meningioma</li> </ul>	<ul style="list-style-type: none"> <li>(Ch. 20)</li> <li>(Ch. 10)</li> </ul>



# PROGNOSTIC VARIABLES

- Extent of surgical resection
- Histologic grade
- Patient Age
- Patient Gender
- Tumor location  
(e.g. AVP)

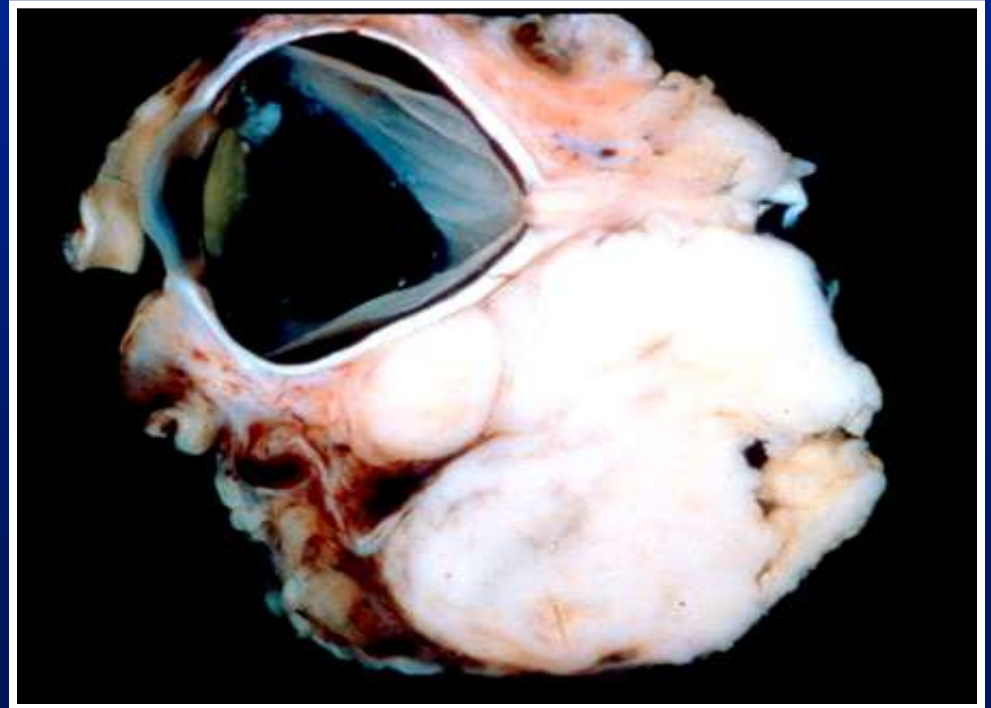




Table 10.01 Meningiomas grouped by likelihood of recurrence and grade

(WHO 2007)

Meningiomas with low risk of recurrence and aggressive growth:		
		ICD-O
Meningothelial meningioma	WHO grade I	9531/0
Fibrous (fibroblastic) meningioma	WHO grade I	9532/0
Transitional (mixed) meningioma	WHO grade I	9537/0
Psammomatous meningioma	WHO grade I	9533/0
Angiomatous meningioma	WHO grade I	9534/0
Microcystic meningioma	WHO grade I	9530/0
Secretory meningioma	WHO grade I	9530/0
Lymphoplasmacyte-rich meningioma	WHO grade I	9530/0
Metaplastic meningioma	WHO grade I	9530/0
Meningiomas with greater likelihood of recurrence and/or aggressive behavior:		
Chordoid meningioma	WHO grade II	9538/1
Clear cell meningioma (intracranial)	WHO grade II	9538/1
Atypical meningioma	WHO grade II	9539/1
Papillary meningioma	WHO grade III	9538/3
Rhabdoid meningioma	WHO grade III	9538/3
Anaplastic (malignant) meningioma	WHO grade III	9530/3
Meningiomas of any subtype or grade with high proliferation index and/or brain invasion		



# MENINGIOMA GRADING

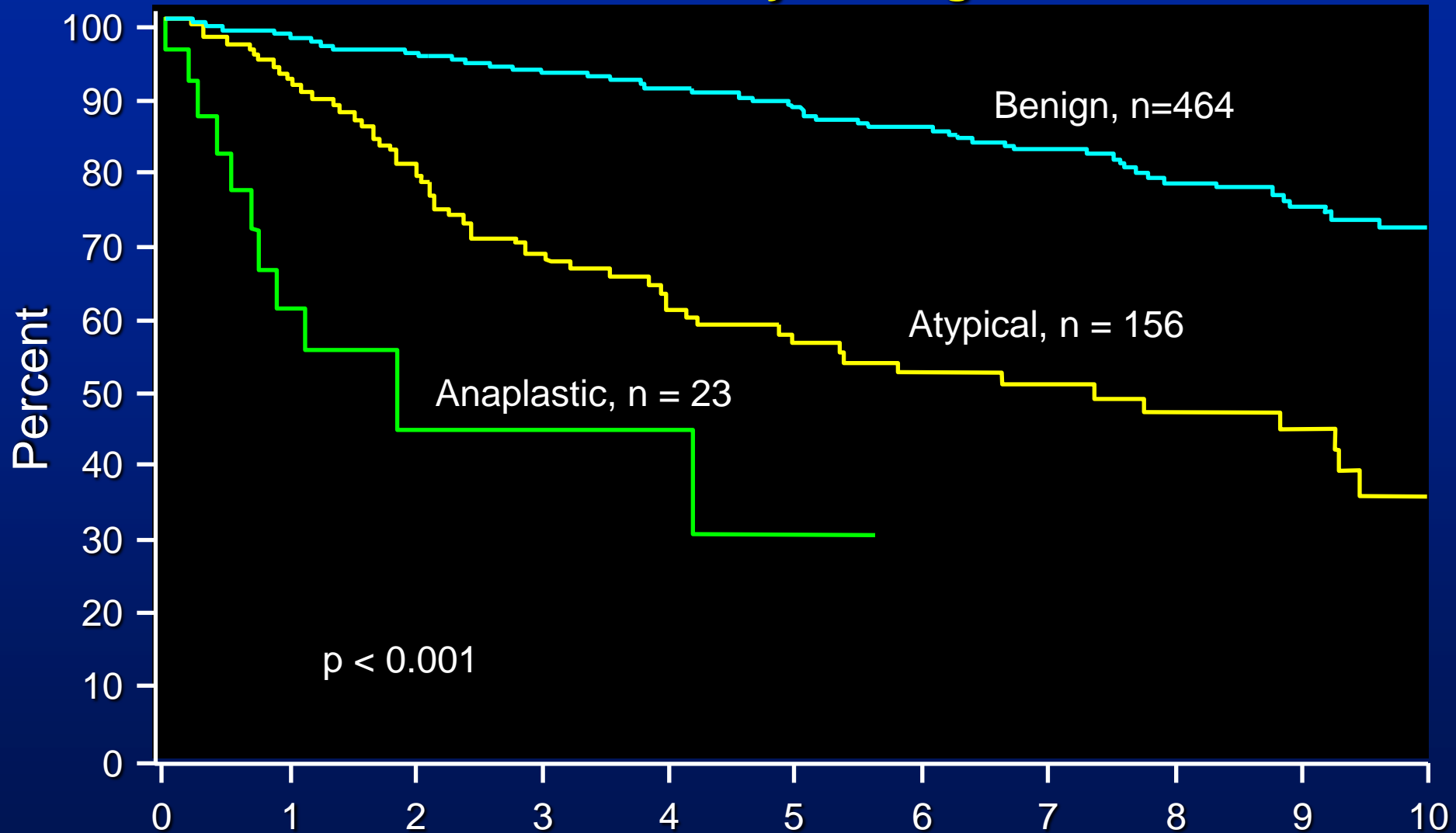
- Atypical (WHO II)
  - High mitotic index ( $\geq 4/10$  HPF)
  - Presence of at least 3 of 5 variables: sheeting, macronucleoli, small cells, hypercellularity, necrosis
- Anaplastic (Malignant) (WHO III)
  - Excessive mitotic index ( $\geq 20/10$  HPF)
  - Sarcoma, carcinoma, or melanoma-like histology

Perry A et al., Am J Surg Pathol 21: 1455, 1997

Perry A et al., Cancer 85:2046, 1999

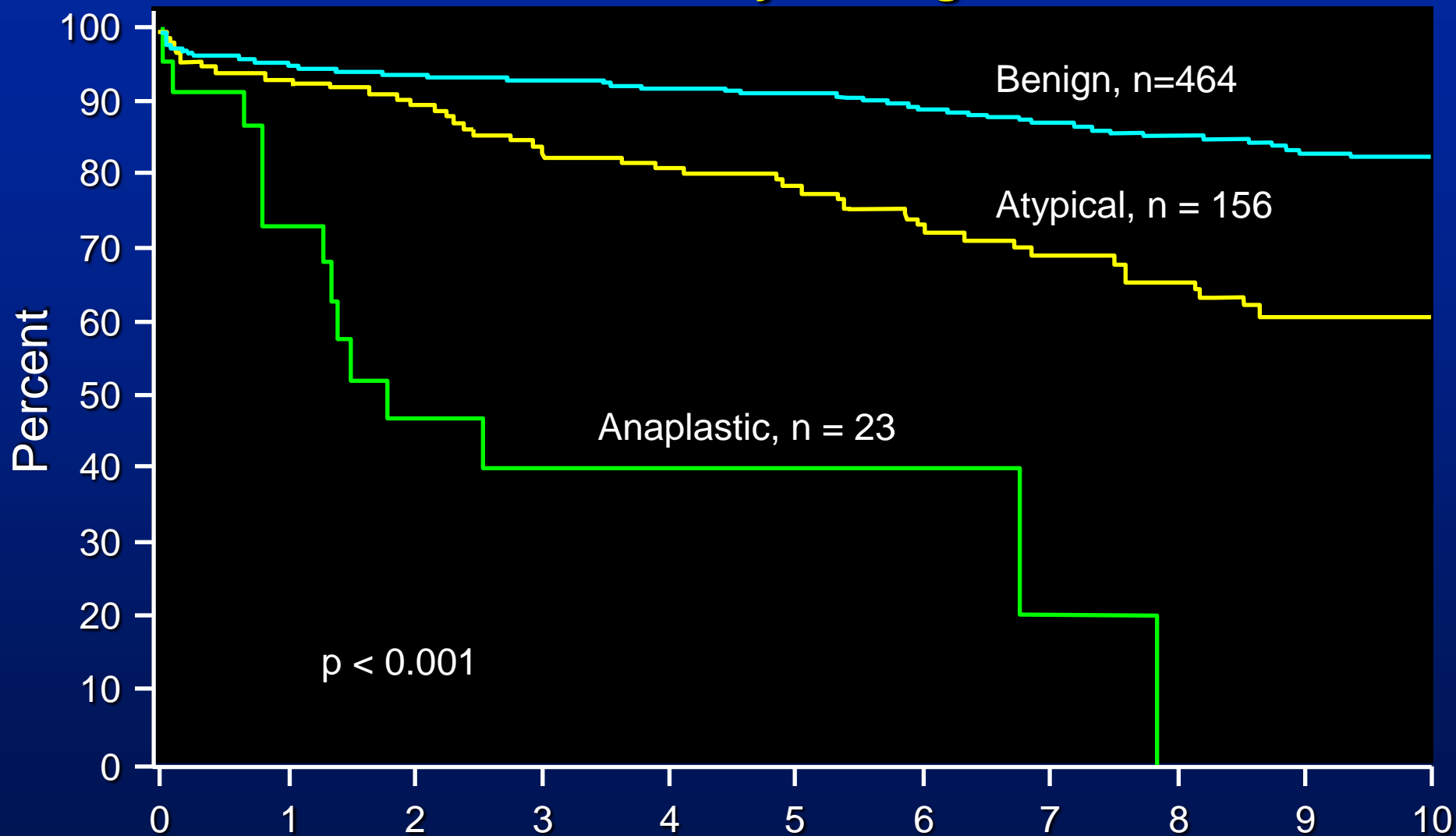


# Recurrence-free Survival in 643 Patients with Primary Meningioma



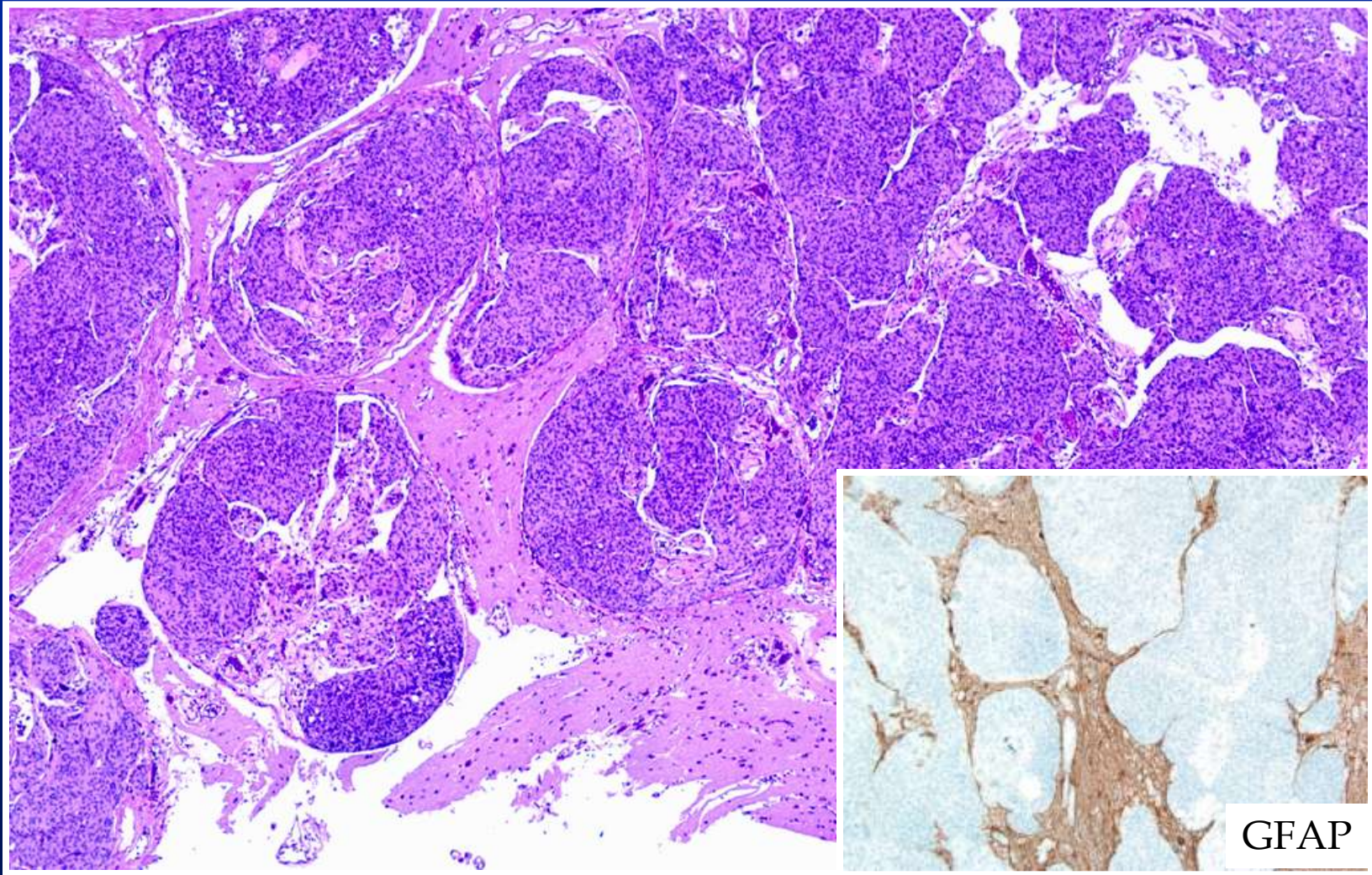


# Overall Survival in 643 Patients with Primary Meningioma





# BRAIN INVASIVE MENINGIOMA





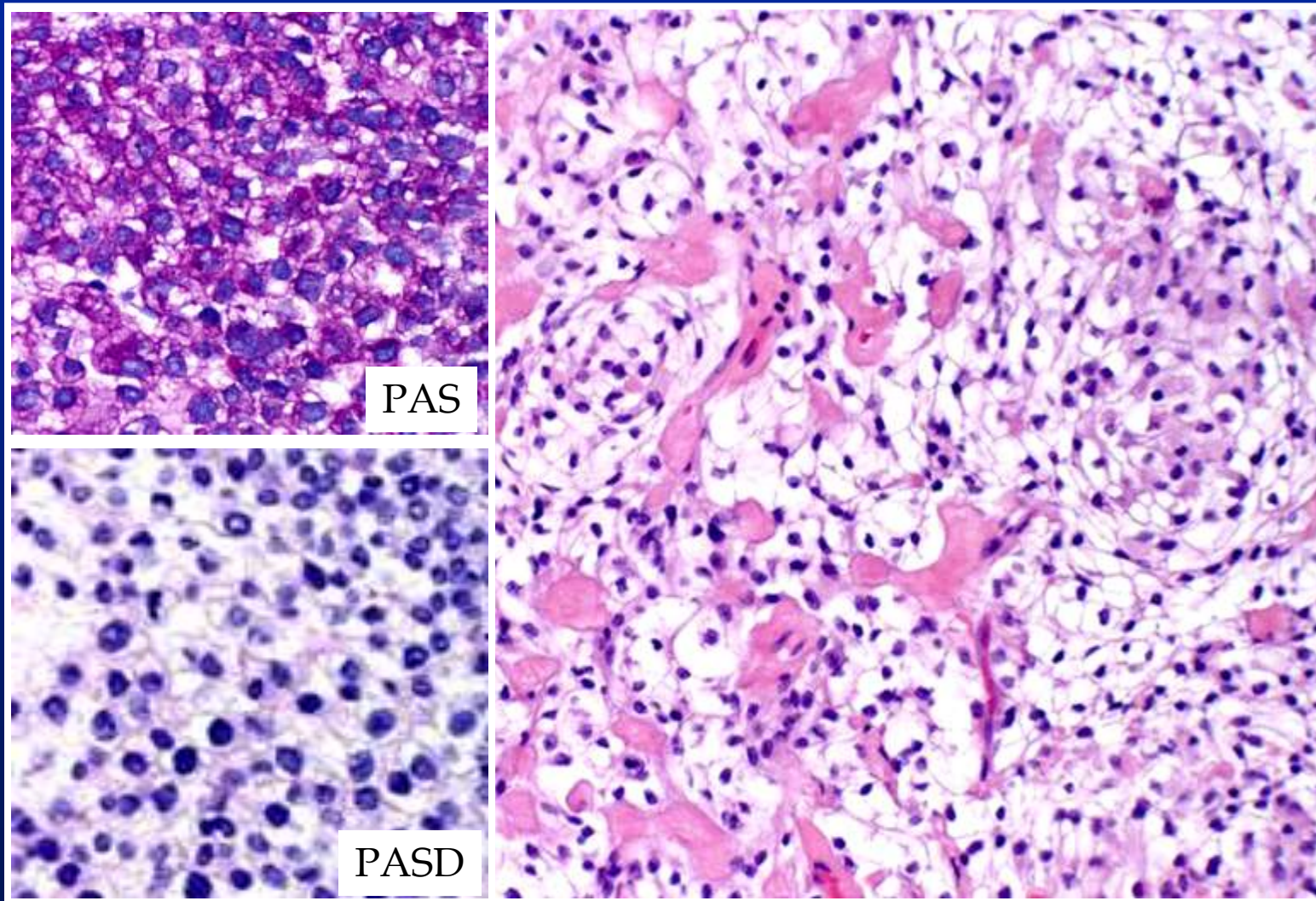
# BRAIN INVASIVE MENINGIOMA

The presence of brain invasion connotes a greater likelihood of recurrence. Brain-invasive, histologically benign and histologically atypical meningiomas both have recurrence and mortality rates similar to those of atypical meningiomas in general {1736}. As such, they should prognostically be considered WHO grade II. Whereas the genetic changes

WHO 2007

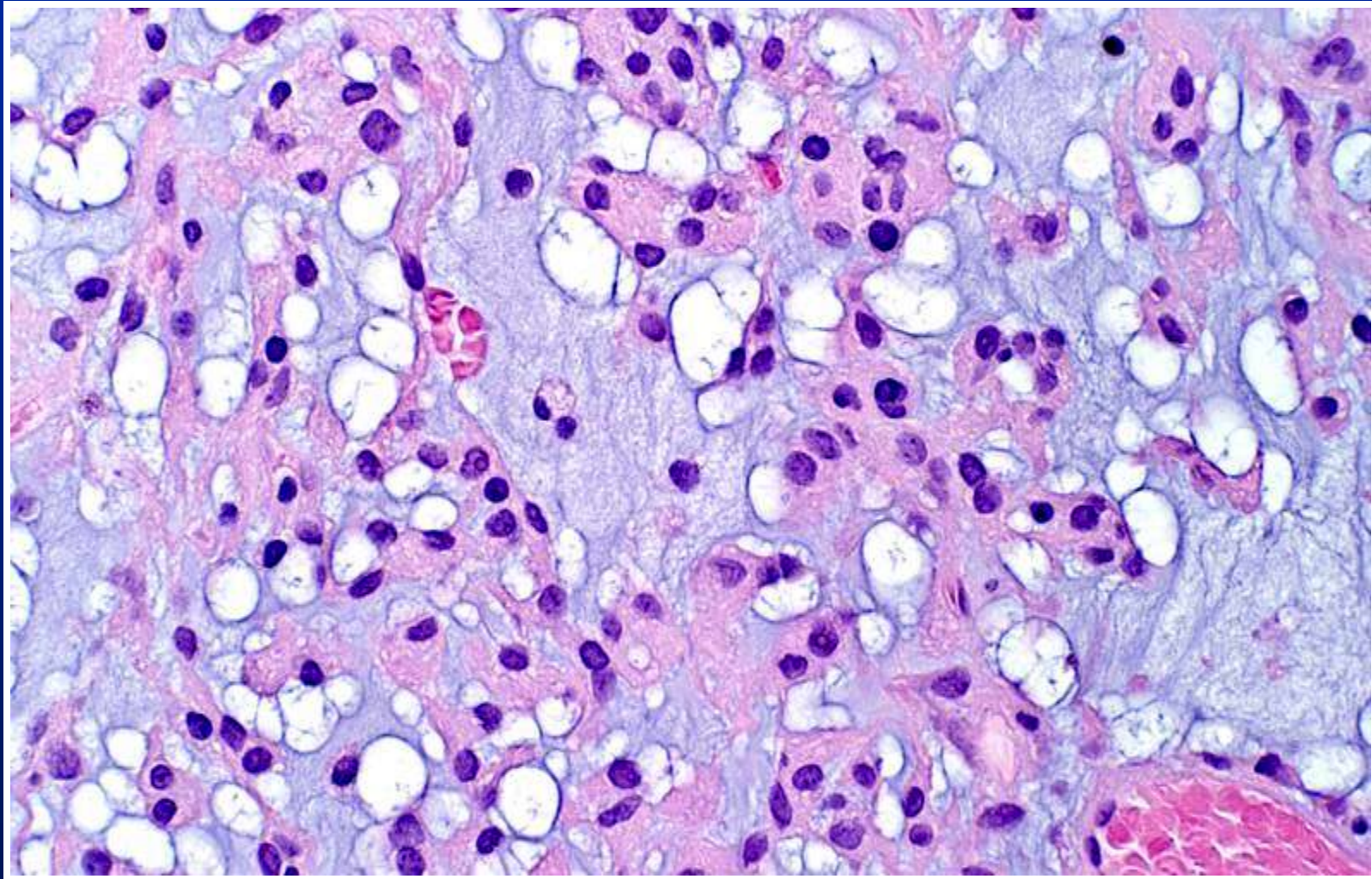


# CLEAR CELL MENINGIOMA (WHO II)



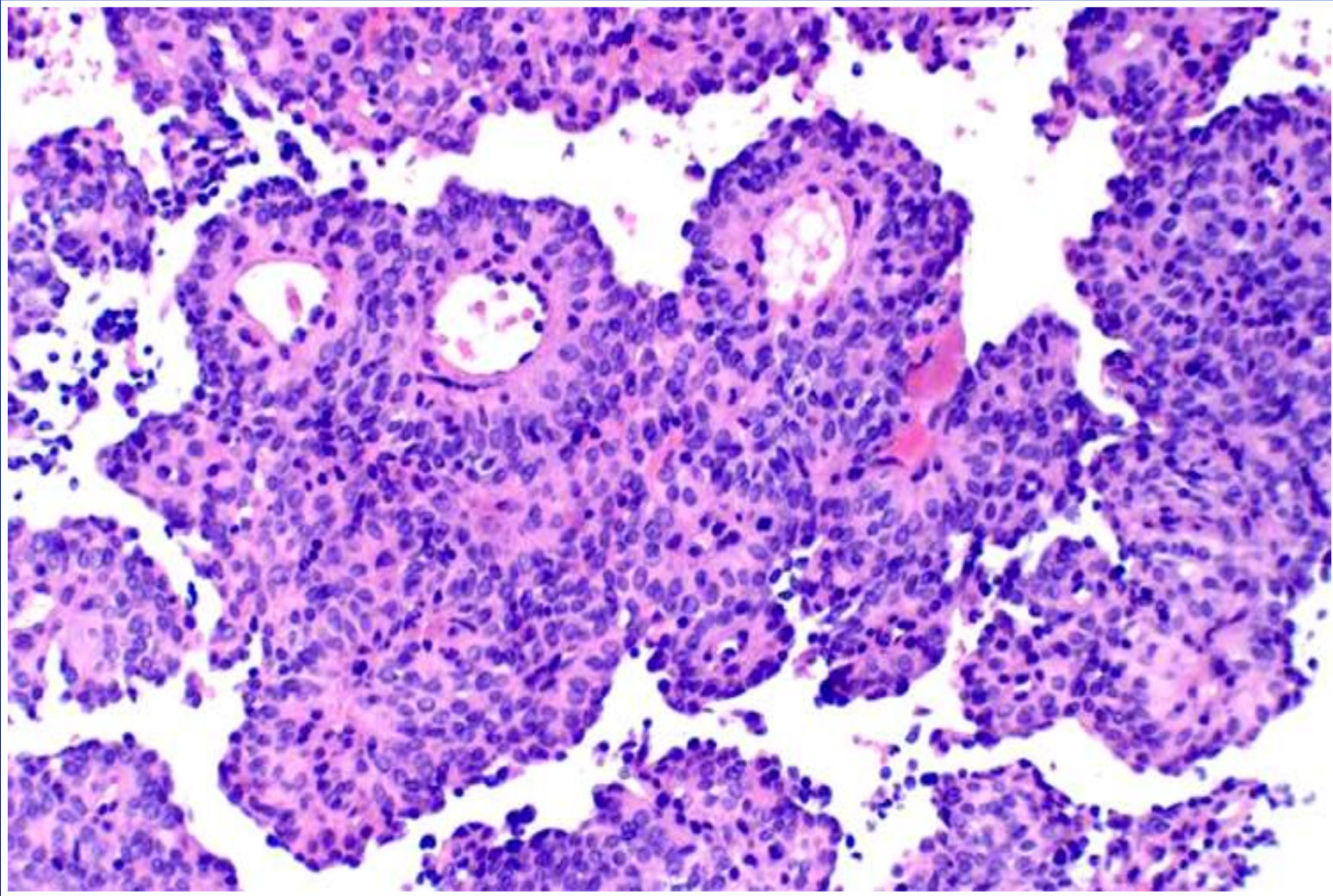


# CHORDOID MENINGIOMA (WHO II)



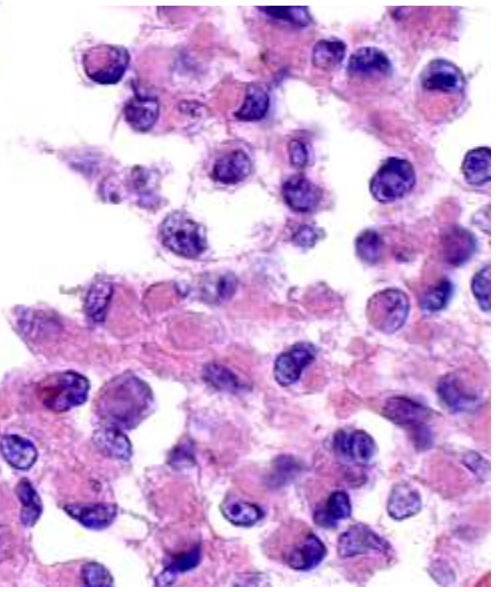
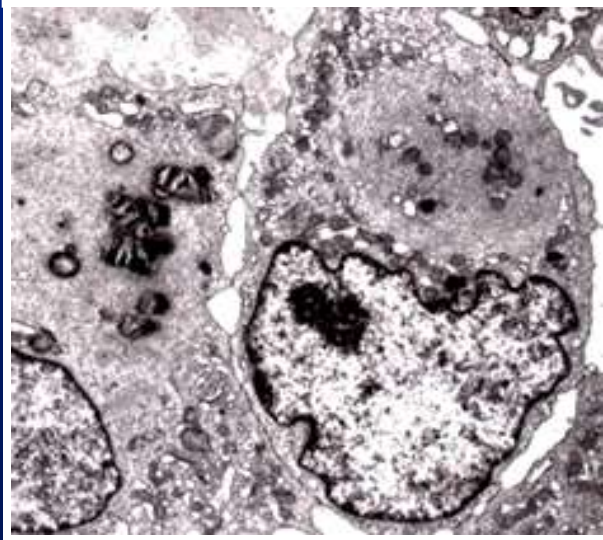
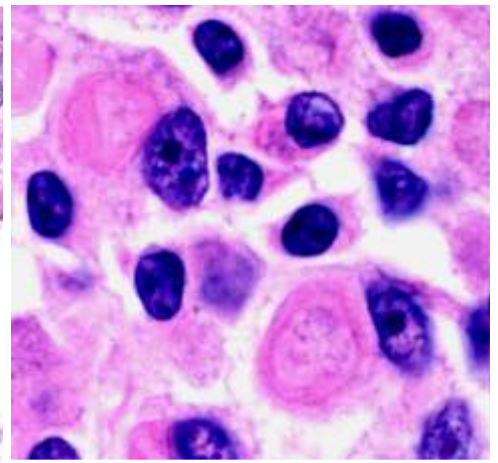
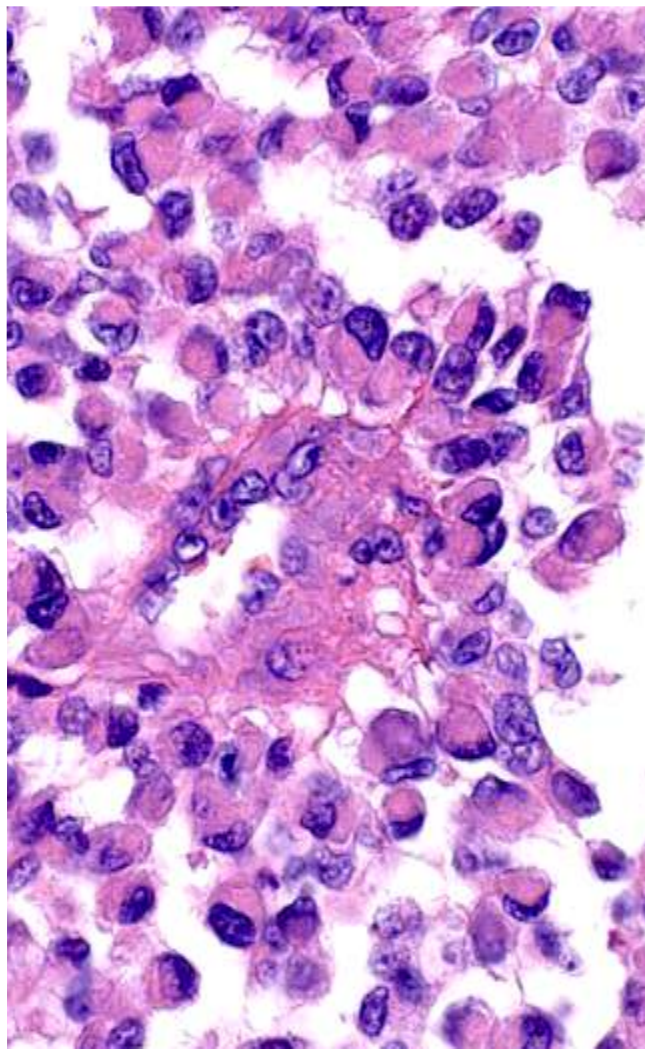
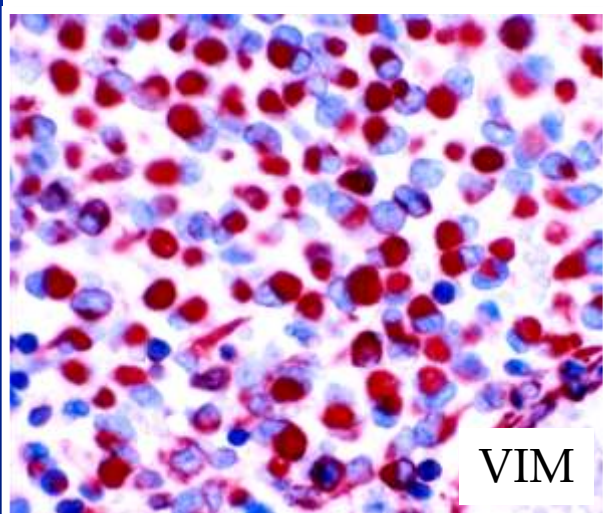


# PAPILLARY MENINGIOMA (WHO III)





# RHABDOID MENINGIOMA (WHO III)





Los colores de la la  
Fórmula 1 en Plus TV

Fórmula 1  
Gran Final en Fox Sports HD

# [CABLE MÁGICO]

Noviembre 2010  
Año 3 N° 39


[www.cablemagico.com.pe](http://www.cablemagico.com.pe)

Cable Mágico HD,  
la mejor oferta en  
Alta Definición  
del Perú

La nueva Nikita nos  
seduce por Warner

Dura de  
matar

Prontísima su venta

 CABLE MÁGICO



# Meningiomas





# MENINGIOMAS

Music and Lyrics by Arie Perry, M.D.



From the surface of the brain and the arachnoidal membrane  
Grows a dural neoplasm, meningioma is its name  
As a tumor of adults, with sharp margins and slow growth  
It may require the gamma knife, or surgery alone

Ch: Though most are low-grade, with a bland histology,  
There's an aggressive subset, with significant morbidity  
Atypical meningiomas, recur quite frequently, anaplastic cases have a high mortality

On neuroimaging exams, they're extra-axial in locale,  
With a classic dural tail, where the enhancement leaves a trail  
Hyperostosis of adjacent bone, implies invasion where the tumor's grown  
It's seen commonly in NF2, and there's often a female skew (chorus)

With a wide morphologic range, the differential may seem strange  
But with the histologic grade, predictions may be made  
The cases graded as atypical have a distinct proclivity  
To display brain invasion or mitotic activity (chorus)

Aggressive variants, include grades II and III  
With atypical, clear cell, and chordoid in the grade II category  
High-grade malignancy corresponds to grade III  
They include anaplastic, rhabdoid, and papillary (chorus)

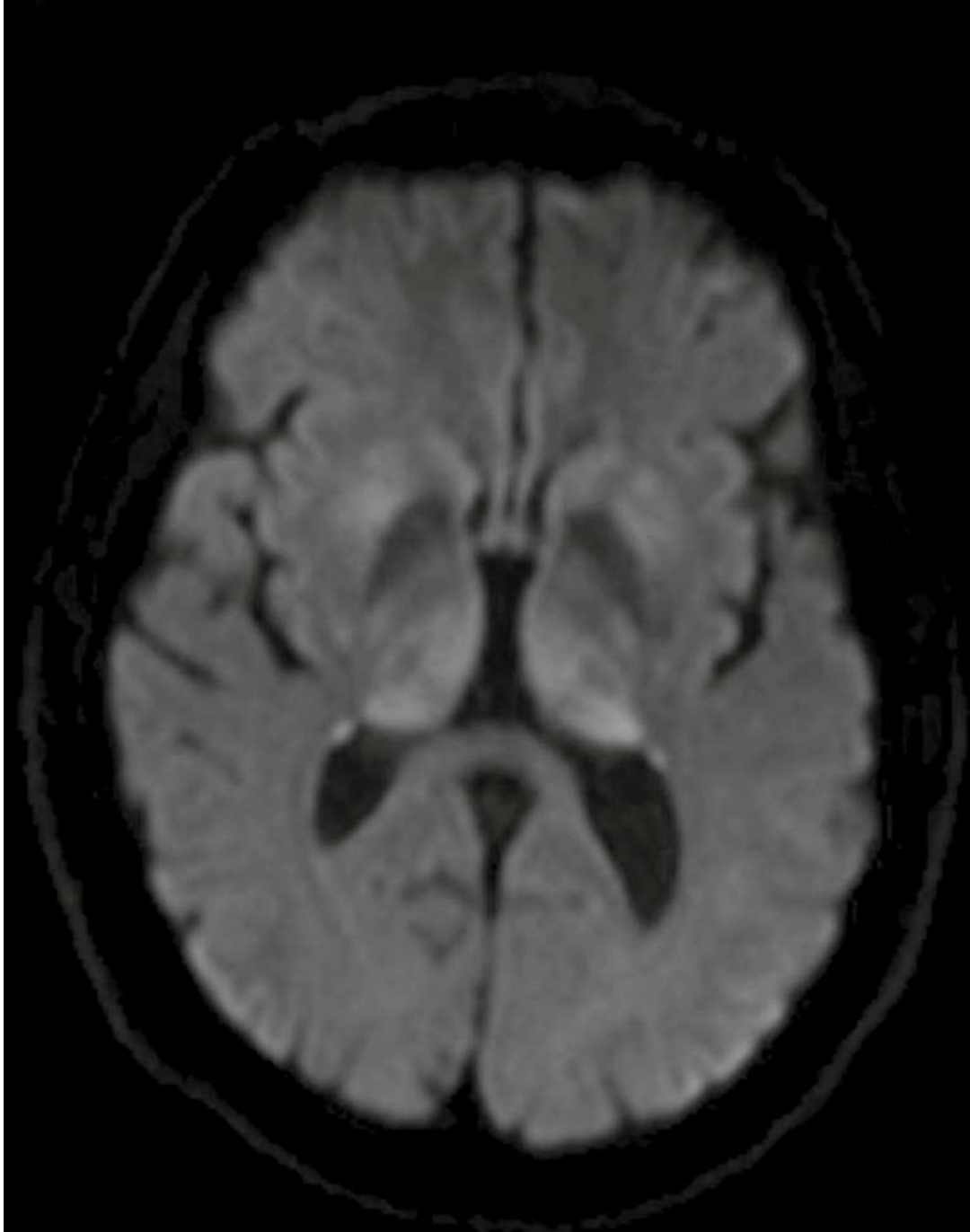
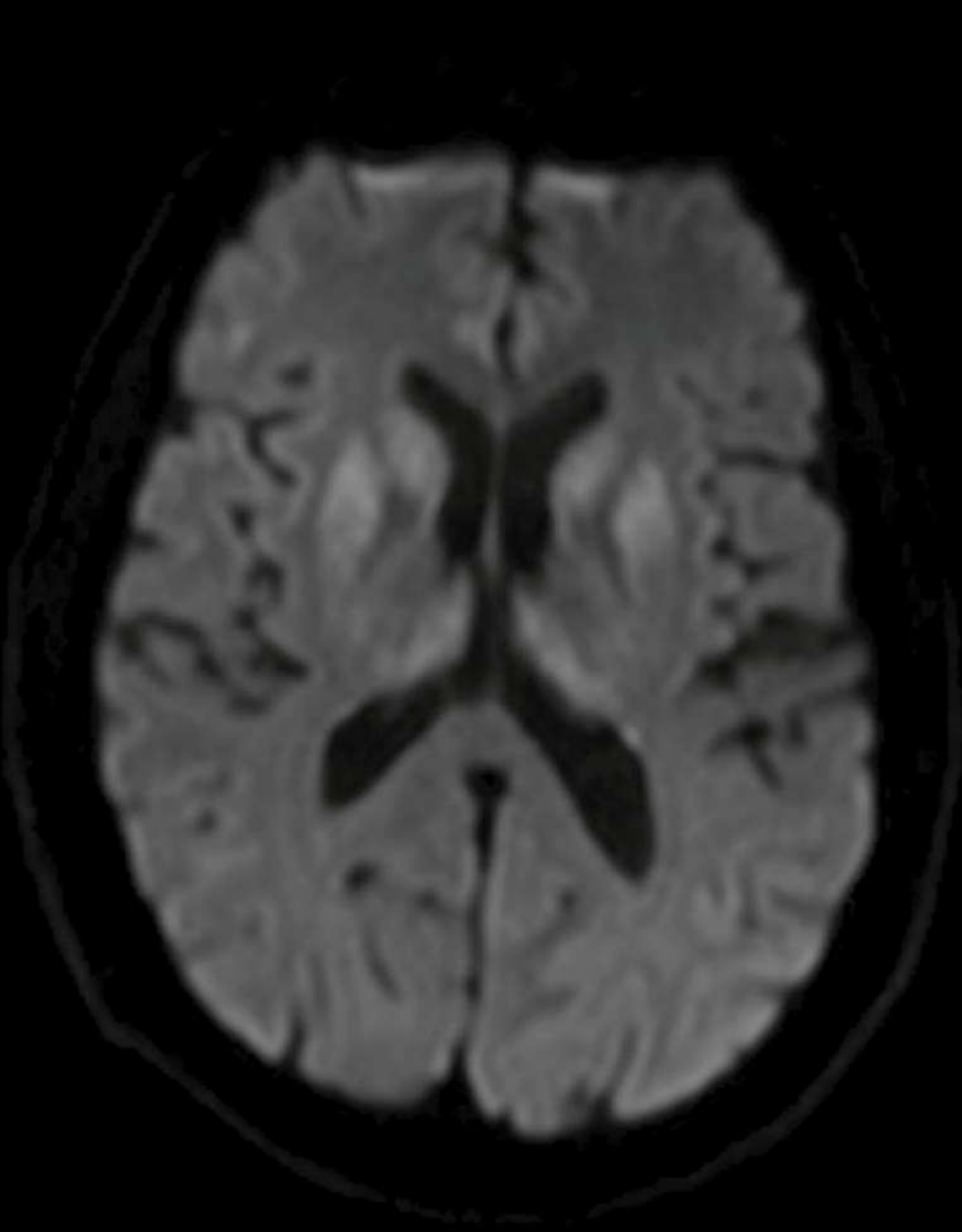
A common tumor from the surface of the brain, meningioma is its name



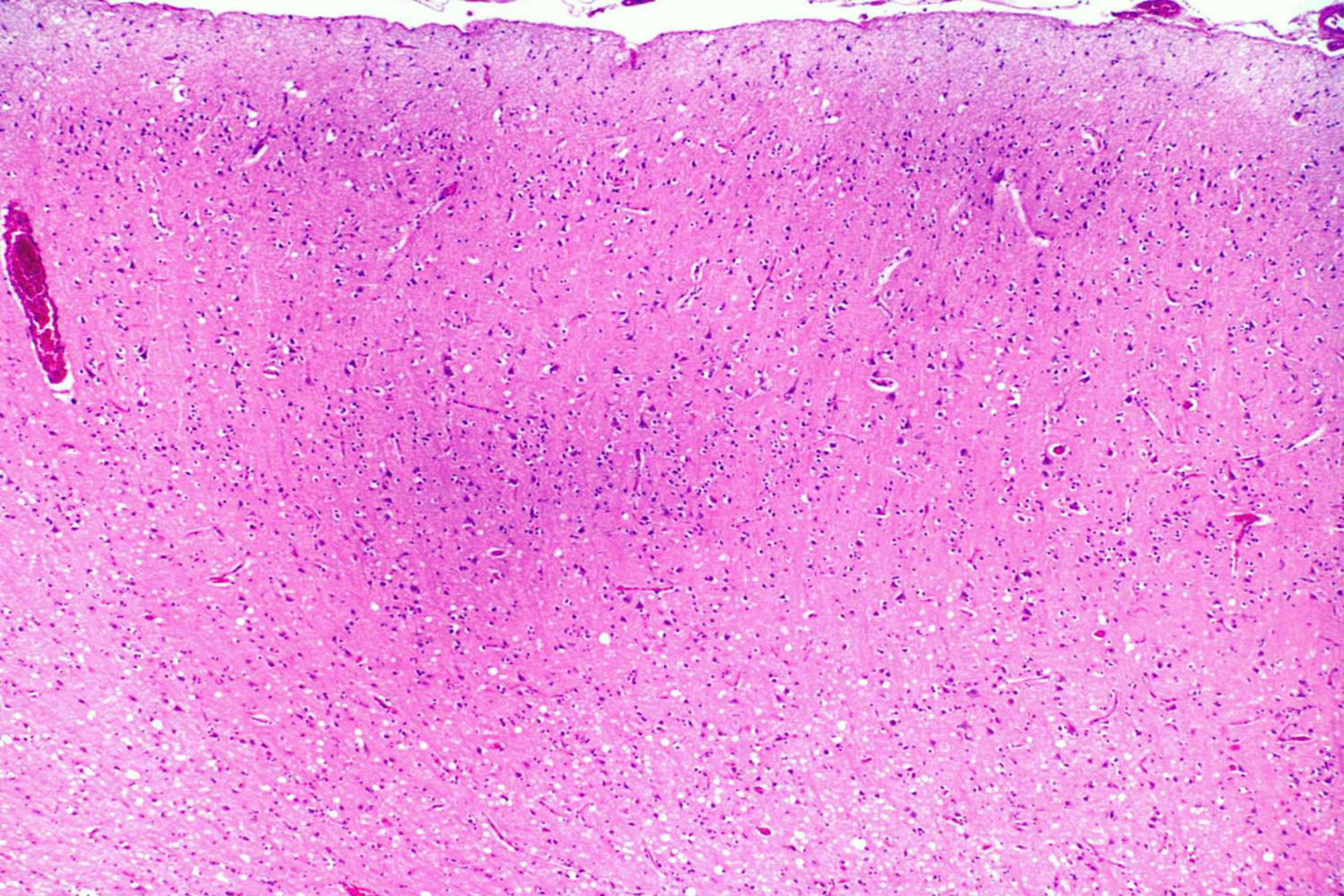
## NP CASE 4

- 74 year old man
- Rapidly progressive cognitive changes and confusion for 4 weeks
- MRI showed patchy FLAIR and DWI signal abnormalities in neocortex, basal ganglia, and thalamus
- DDx: CJD, Encephalitis, Vasculitis

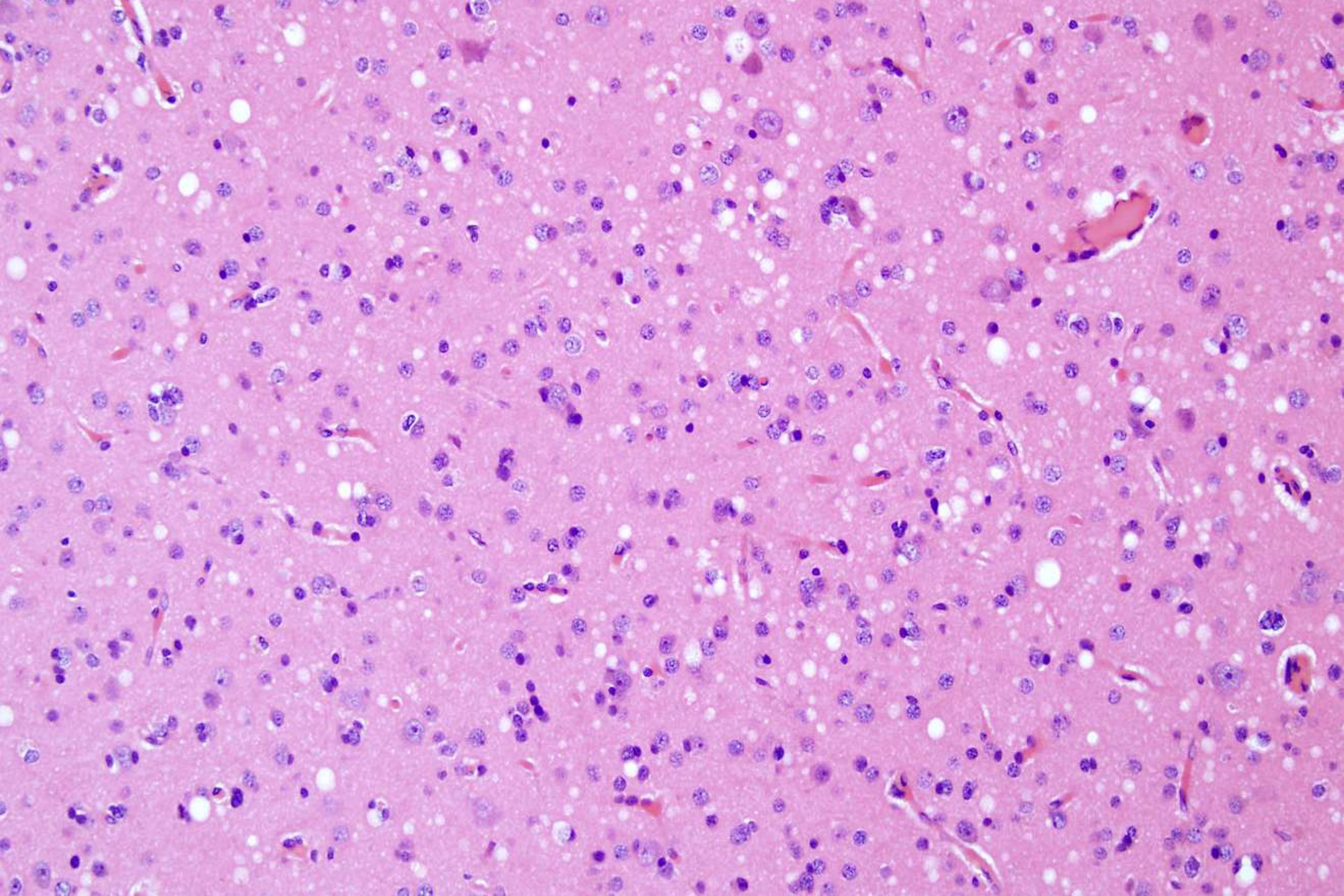




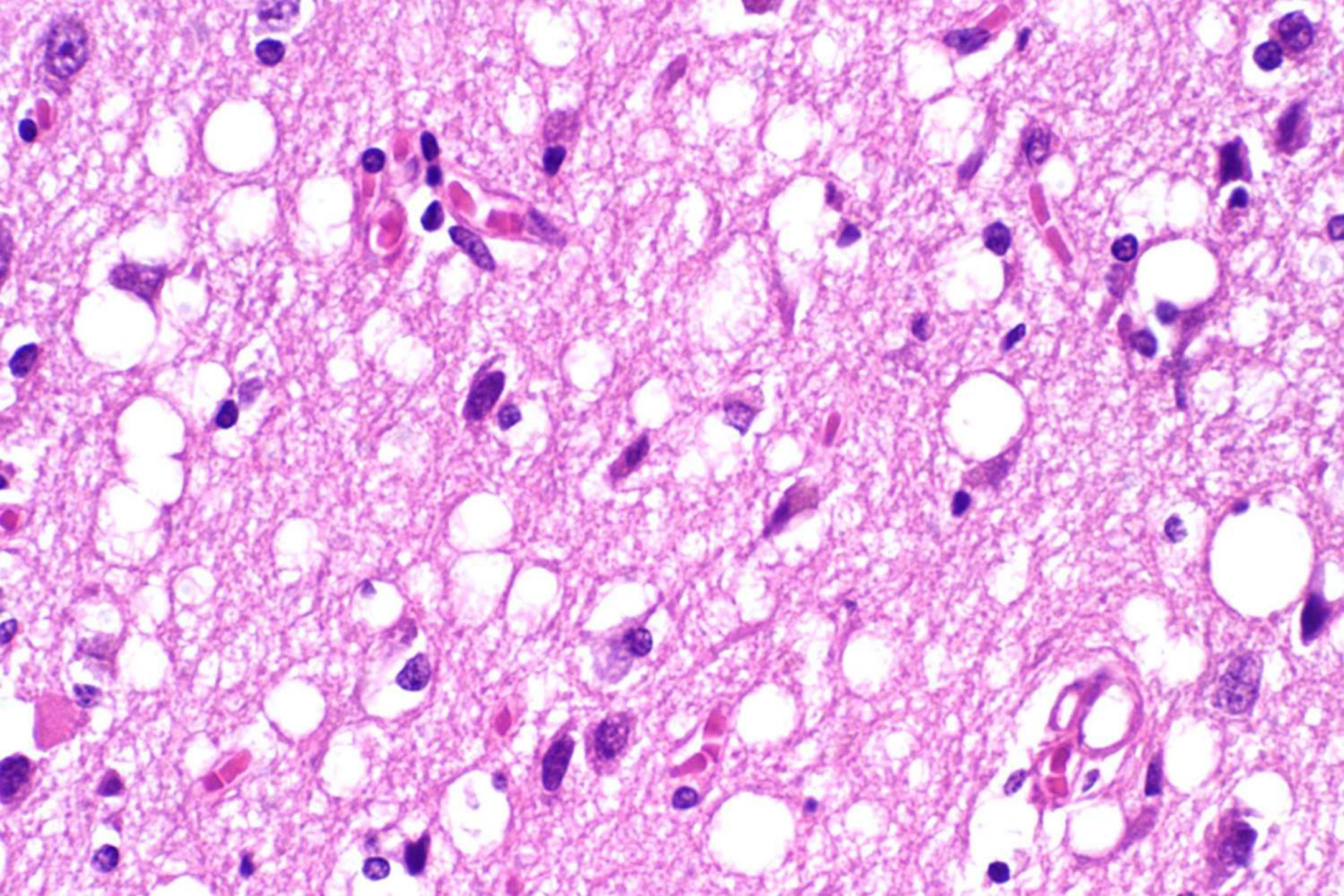


















# WHICH PATTERN(S)?

- Parenchymal Infiltrate with Hypercellularity
  - Solid Mass (Pure)
  - Solid and Infiltrative Process
  - Vasculocentric Process
  - Extra-axial Mass
  - Meningeal Infiltrate
  - Destructive/Necrotic Process
  - Subtle Pathology or Near Normal Biopsy
- 





# WHICH PATTERN(S)?

- Parenchymal Infiltrate with Hypercellularity
  - Solid Mass (Pure)
  - Solid and Infiltrative Process
  - Vasculocentric Process
  - Extra-axial Mass
  - Meningeal Infiltrate
  - Destructive/Necrotic Process
  - Subtle Pathology or Near Normal Biopsy
- 





# WHAT IS YOUR FAVORED DIAGNOSIS?

- Creutzfeldt-Jakob Disease
- Other neurodegenerative disorder with secondary vacuolation
- Ischemia and cerebral edema
- Artifactual vacuolation







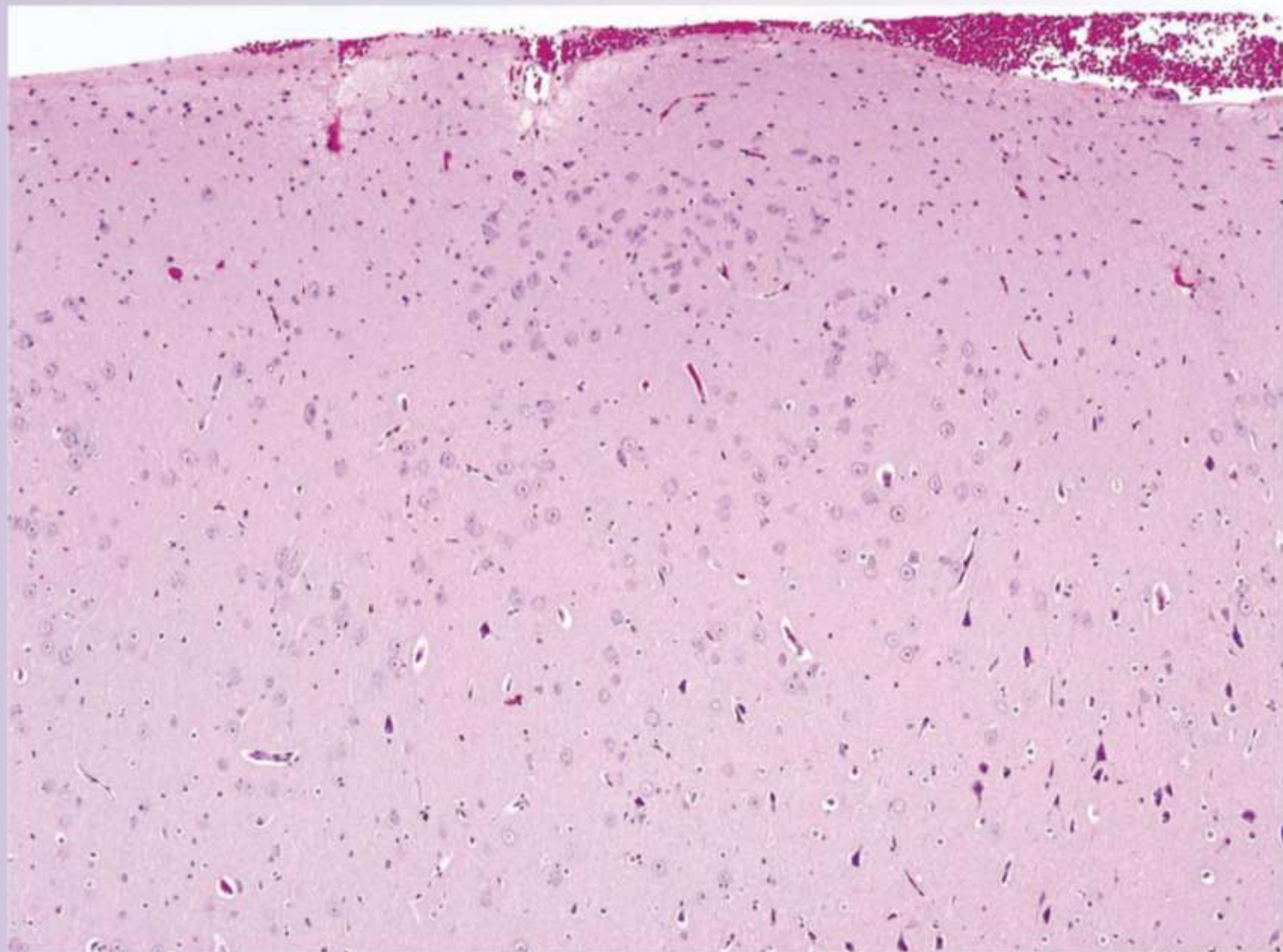
DX: CREUTZFELDT-JAKOB  
DISEASE (CJD)

Western Blot: PrP<sup>CJD</sup> positive





## Pattern 8: Subtle Pathology or Near-Normal Biopsy Specimen





	Subtle form of cortical dysplasia	(Ch. 23)
Balloon cells	Focal cortical dysplasia, type IIb	(Ch. 23)
	Tuber	(Ch. 23)
Neuronal loss in hippocampus (CA1, CA4)	Mesial temporal sclerosis	(Ch. 23)
Microglial nodules/scant perivascular inflammation	Encephalitis (infectious, paraneoplastic)	(Ch. 21)
	Rasmussen's encephalitis	(Ch. 23)
Intravascular pigment	Cerebral malaria	(Ch. 23)
Red necrotic neurons	Acute cerebral infarct	(Ch. 24)
Vascular hyalinization	Radiation effects	(Ch. 19)
	Meningioangiomatosis	(Ch. 20)
	Amyloid angiopathy	(Ch. 24)
	CADASIL	(Ch. 24)
	Arteriolosclerosis	(Ch. 24)
Granular vascular deposits	CADASIL	(Ch. 24)
Hemorrhage/hemosiderin	Epileptogenic "glial scar"	(Ch. 23)
	Amyloid angiopathy	(Ch. 24)
	Small cavernous angioma	(Ch. 24)
Neurofibrillary tangles or neuritic plaques	Alzheimer's disease	(Ch. 25)
Spongiform changes in gray matter	Cerebral infarct	(Ch. 24)
	→ Creutzfeldt-Jakob disease (CJD)	(Ch. 25)
	Other neurodegenerative disorders (usually superficial spongiosis)	(Ch. 25)

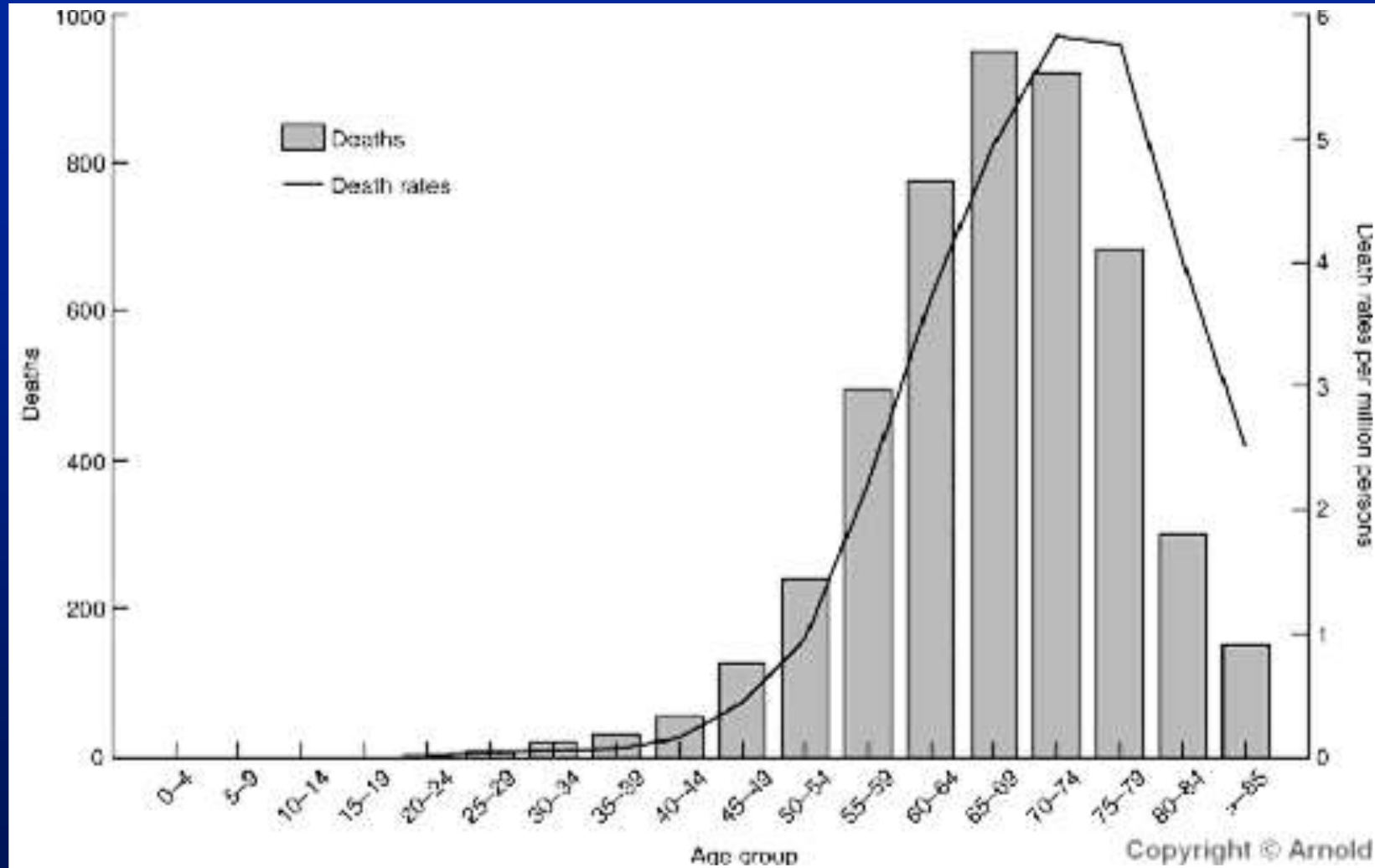


# CREUTZFELDT-JAKOB DISEASE (CJD)

- Prototypic **prion disease** (prion = “proteinaceous” and “infectious”)
- Transmissible spongiform encephalopathy (TSE)
- **Sporadic** (>90%)
  - 1/10<sup>6</sup> incidence
  - No germline mutation in *PRNP* gene (20p)
- **Familial** (5-10%) = *PRNP* gene mutation
- **Iatrogenic** = dural graft, corneal transplant, EEG electrodes, growth hormone extracts



# CREUTZFELDT-JAKOB DISEASE (CJD)



From: Greenfield's Neuropathology 7<sup>th</sup> ed., 2002

# CREUTZFELDT-JAKOB DISEASE (CJD)

- Clinical triad
  - Rapid dementia (duration <1 year)
  - Myoclonus
  - Periodic spikes on EEG (66% sensitive, 74% specific)
  - Basal ganglia lesions on MRI: 67% sensitive, 93% specific
  - Positive CSF protein 14-3-3: 93% sensitive and specific
- Pathology
  - Biopsy: 95% sensitive, 100% specific
  - Gross: normal to variable cerebral atrophy
  - Histology: spongiform encephalopathy, neuronal loss, gliosis in cortex, basal ganglia, and thalamus



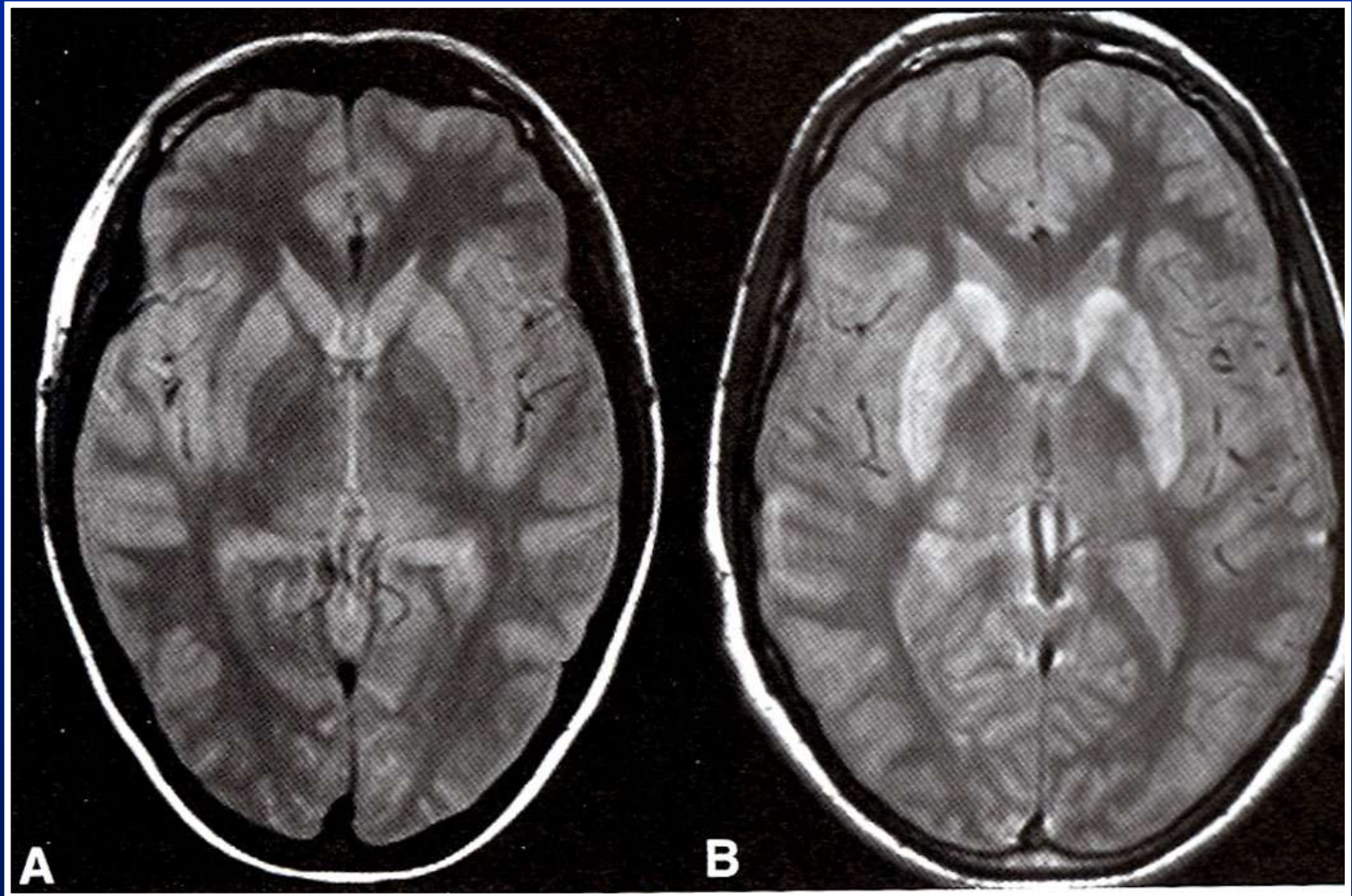
# CREUTZFELDT-JAKOB DISEASE (CJD)

- PrP = prion protein
- PrP<sup>C</sup> = normal cellular constituent ( $\alpha$ -helical) of neurons; functions: copper storage?, resistance to oxidative stress?
- PrP<sup>Sc</sup> or PrP<sup>CJD</sup> or PrP<sup>res</sup> = pathogenic, protease resistant form ( $\beta$ -pleated sheet; amyloid-like)
- PrP<sup>CJD</sup> is transmissible and induces further PrP<sup>C</sup> conversions.  $\Delta$ PrP = mutated form.
- Sporadic CJD = spontaneous conformation or age related mutation?

# CREUTZFELDT-JAKOB DISEASE (CJD)

- Codon 129 Genotype
  - ATG vs. GTG polymorphism
  - Methionine (M) vs. Valine (V)
  - **MM** = 37% of population (74% of cases)
  - MV = 51% of population (15% of cases)
  - VV = 12% of population (11% of cases)

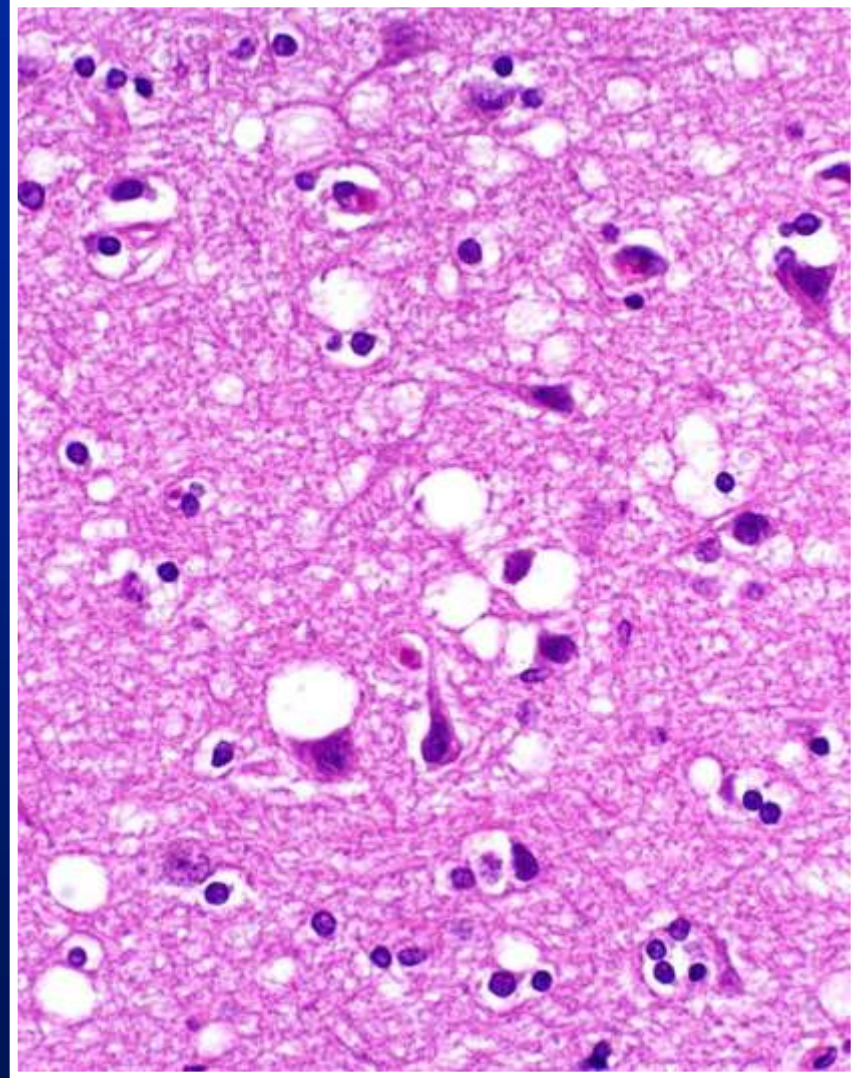
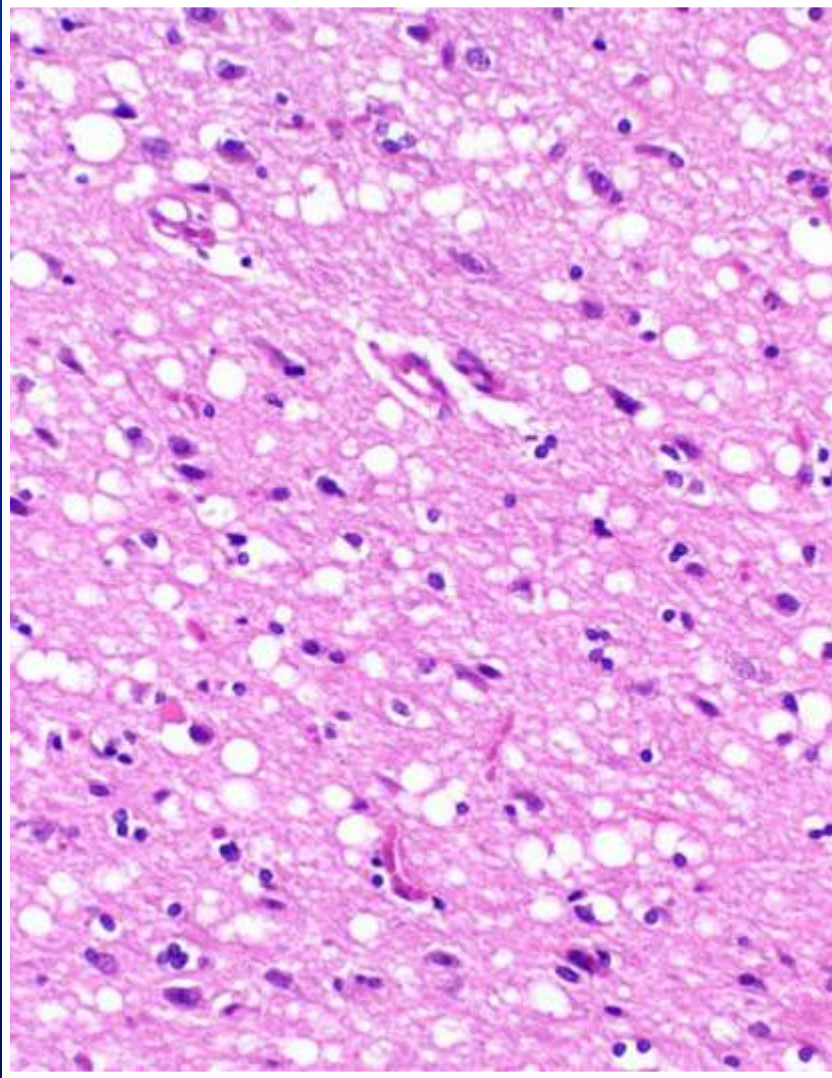




Neurodegeneration: The Molecular Pathology of Dementia and Movement Disorders, Edited by Dennis W. Dickson, 2003

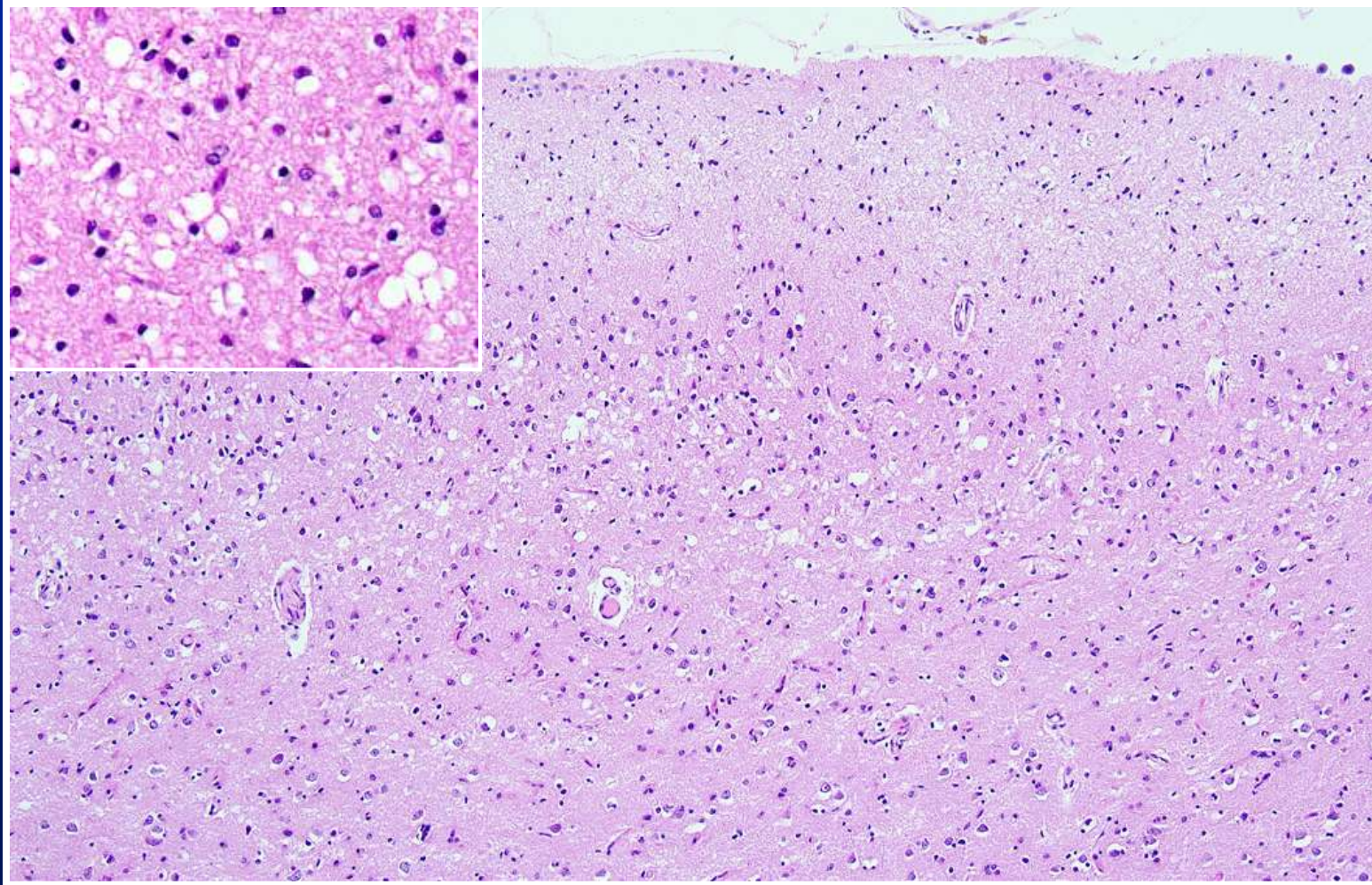


# CREUTZFELDT-JAKOB DISEASE (CJD)




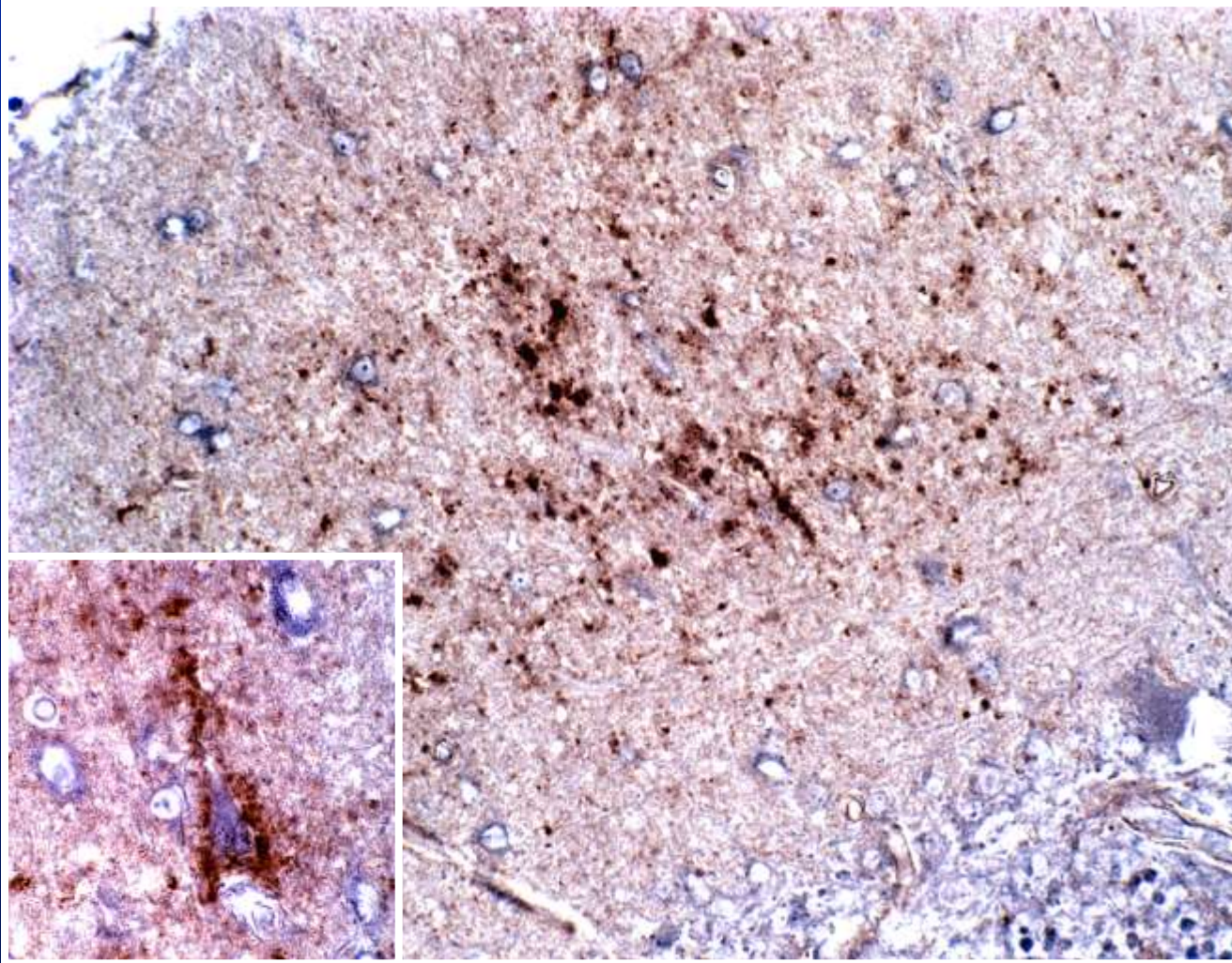


# BEWARE SUPERFICIAL SPONGIOSIS IN OTHER ND DISORDERS: FTLD, LBD

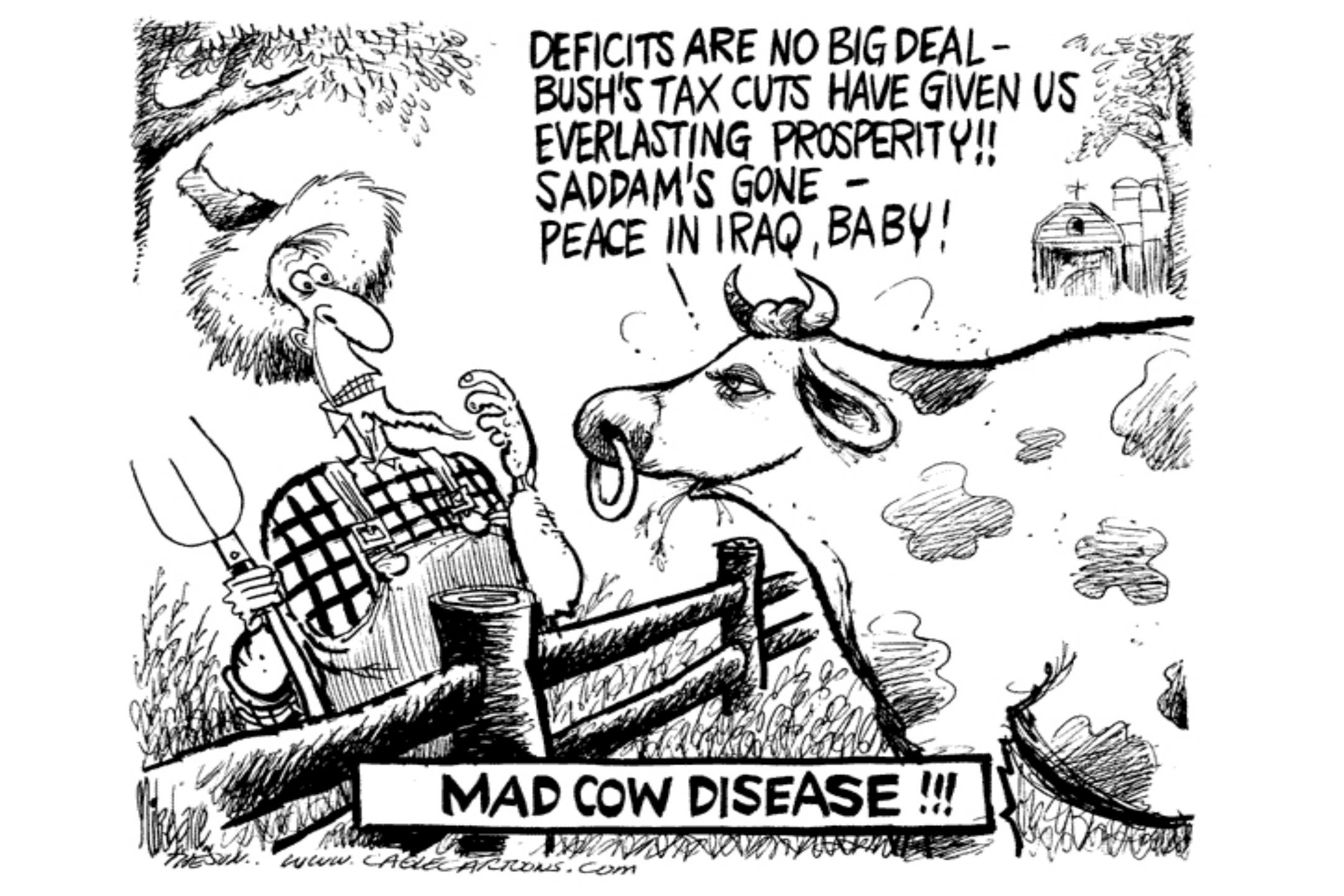




# CREUTZFELDT-JAKOB DISEASE (CJD)







DEFICITS ARE NO BIG DEAL -  
BUSH'S TAX CUTS HAVE GIVEN US  
EVERLASTING PROSPERITY!!  
SADDAM'S GONE -  
PEACE IN IRAQ, BABY!

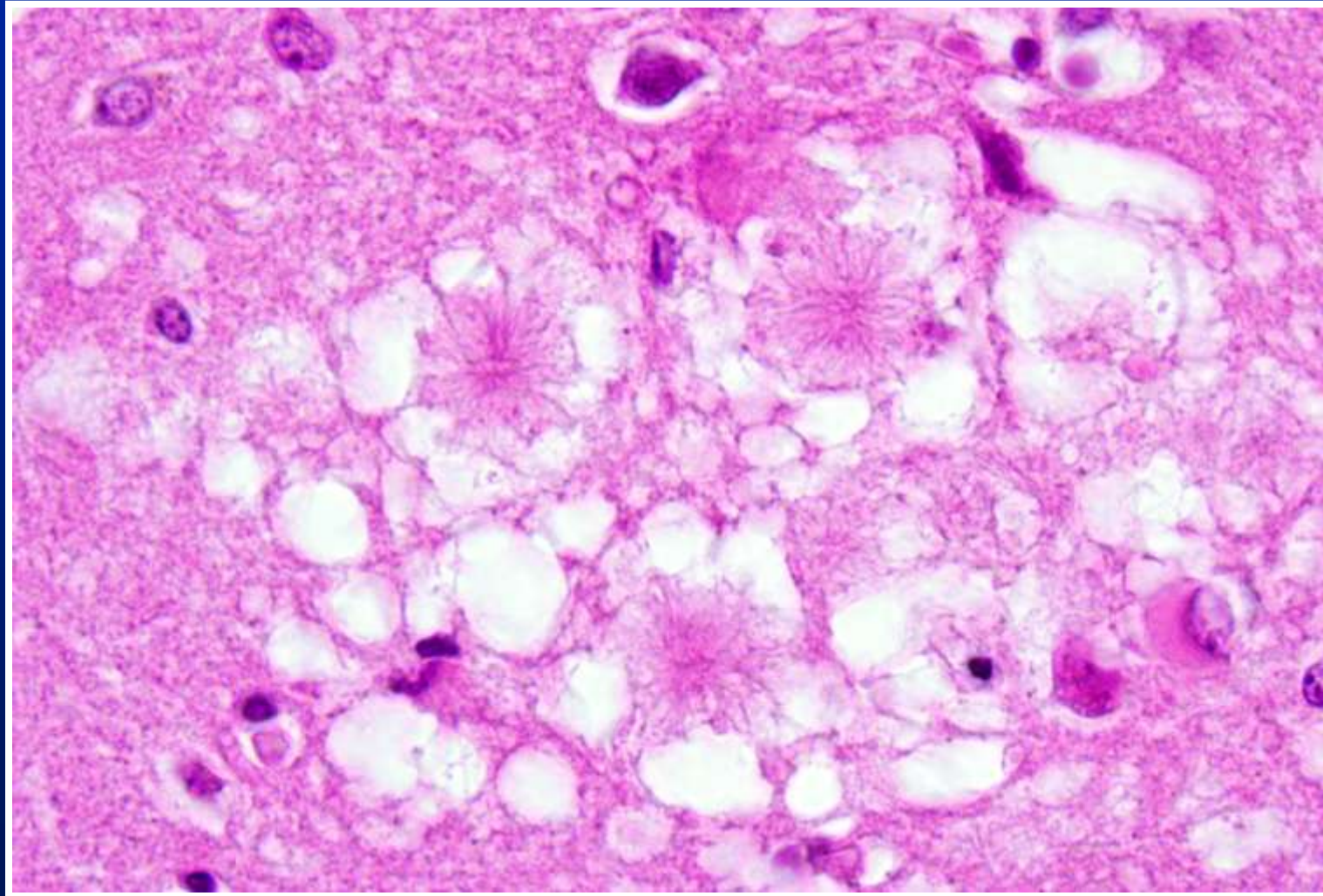
**MAD COW DISEASE !!!**

# NEW VARIANT CJD (nvCJD)

- Epidemiologic link with bovine spongiform encephalopathy (BSE) (“mad cow disease”) and identical PrP isoform
- Younger age of onset (mean 28 years)
- Sensory/ psychiatric symptoms, ataxia
- Extensive amyloid plaques
- Codon 129 genotype is MM (100%)
- Mode of transmission perplexing, since little PrP in skeletal muscle



# NEW VARIANT CJD (nvCJD)



# PRIONOPHOBIA





# BIOPSY TO R/O CJD

- Ideal bx should include cortex, subcortical WM, and portion of putamen under **CJD precautions**
- Divide tissue in two
  - Routine histo/IHC: **buffered formalin** for at least 24 hours followed by **formic acid Rx** for 30 minutes to an hour, then routine processing
  - **Snap frozen** for Western Blot, mutation analysis, etc.
- **Incinerate** all contaminated wastes, use **disposable instruments** when possible, treat instruments / surfaces with hypochlorite (chlorine/bleach), formic acid, or autoclaving at 134°C x 18 minutes

About the Center

About Human Prion Diseases

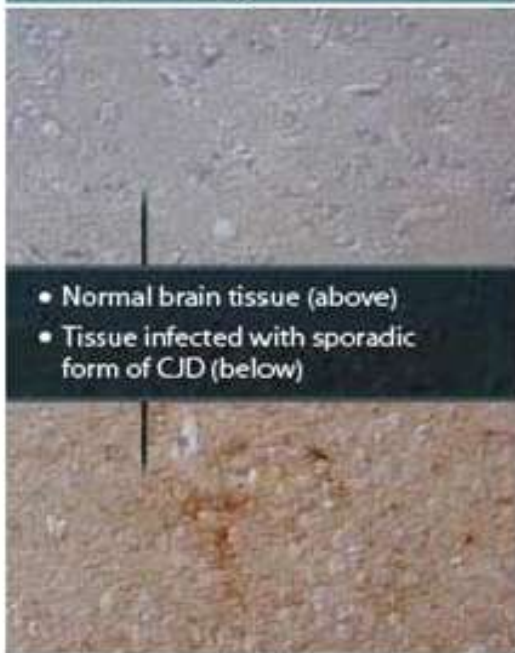Table of Cases Examined

Protocols

Forms

Resources

Contact & Mailing



- Normal brain tissue (above)
- Tissue infected with sporadic form of CJD (below)

National Prion Disease Pathology  
Surveillance Center

Case Western Reserve University  
2085 Adelbert Road, Room 419  
Cleveland, Ohio 44106  
Tel: 216-368-0587 / Fax: 216-368-4090

## Welcome

The National Prion Disease Pathology Surveillance Center (NPDPS) was established in 1997 at the Division of Neuropathology of Case Western Reserve University. Several European countries also have established surveillance centers to monitor the occurrence of prion diseases, or spongiform encephalopathies, in response to the epidemic of Bovine Spongiform Encephalopathy (BSE), also known as "mad cow disease," which occurred in the United Kingdom during the 1980s.

### Purposes of the Center:

- Acquire tissue samples and clinical information from as many cases of human prion disease occurring in the United States as possible in order to help monitor the possible occurrence of variant CJD (vCJD) in the USA.
- Help establish the diagnosis of prion disease by analyzing cerebrospinal fluid (CSF), blood, and brain tissue obtained either at biopsy or autopsy.
- Identify the precise type of prion disease (sporadic, familial, or acquired) by examining the prion protein and the prion protein gene, once the diagnosis of prion disease has been established.
- Report findings to caregivers in a timely fashion.
- Transfer the data obtained to the Centers for Disease Control and Prevention (CDC) and the Health Departments of the individual states in order to monitor the prevalence of prion diseases in the USA and investigate possible cases in which the disease has been acquired from other humans or from animals.
- Store tissues for future studies conducted at the NPDPS as well as at other laboratories around the world.

### Diagnostic Activities of the Center:

- In CSF: Search for the presence of the 14-3-3 protein. The 14-3-3 protein is a marker for some prion diseases, such as Creutzfeldt-Jakob disease (CJD), when a number of other neurodegenerative conditions are excluded.
- In DNA extracted from blood, brain, or other tissues: Search for the presence of mutation in the prion protein gene and determine the polymorphism at codon 129 and at other codons.
- In unfixed brain tissue obtained either at biopsy or autopsy: Search for the presence and establish the type of the abnormal, protease-resistant form of the prion protein, also known as scrapie prion protein (PrP<sup>Sc</sup>).
- On fixed brain tissue: Exclude or confirm and characterize the prion disease by microscopic examination following ordinary histological procedures and immunohistochemical demonstration of the prion protein.





Creutzfeldt-Jacob  
Disease



# CREUTZFELDT-JACOB DISEASE

Music and Lyrics by Arie Perry, M.D.




Intro: Creutzfeldt-Jakob disease, classic prion disorder

Ch: Oh CJD, it's plain to see, your spongiform encephalopathy,  
Marked neuronal loss, it comes across  
Gray matter is gliotic with cerebral atrophy,  
Please keep mutant prion proteins far away from me  
Last chorus repeat: Please keep mutant prion proteins far away from me

Rapid dementia is the first clue, periodic sharp waves, and myoclonus too  
Most are sporadic, one in a million rate, beta-pleated PrP amyloid leads to poor fate,  
histology shows (chorus)

Sporadic form is the common type, infectious spread is rare, despite the media hype  
Familial cases in five to ten percent, PrP germline mutations is what this represents,  
histology shows (chorus)

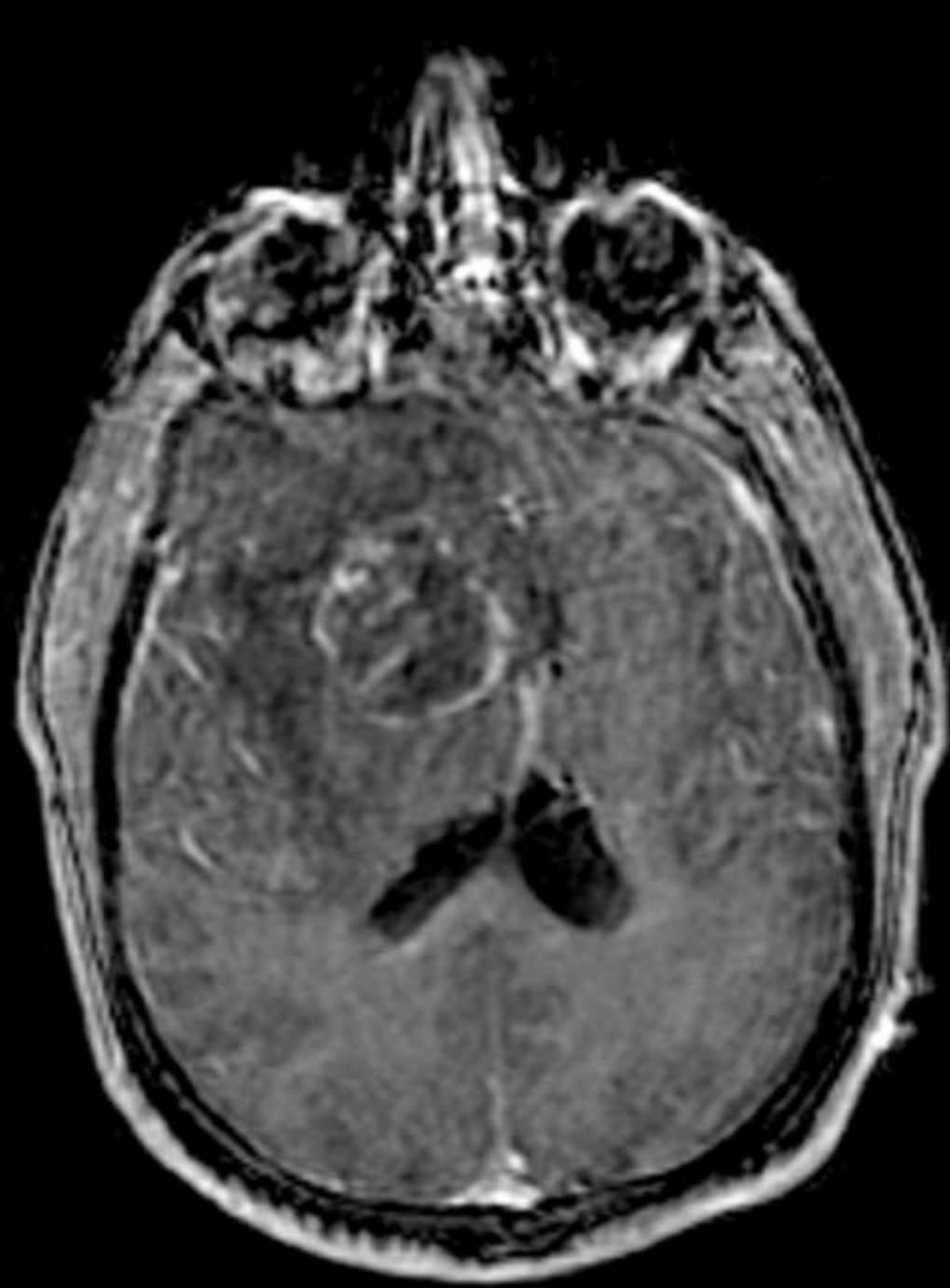
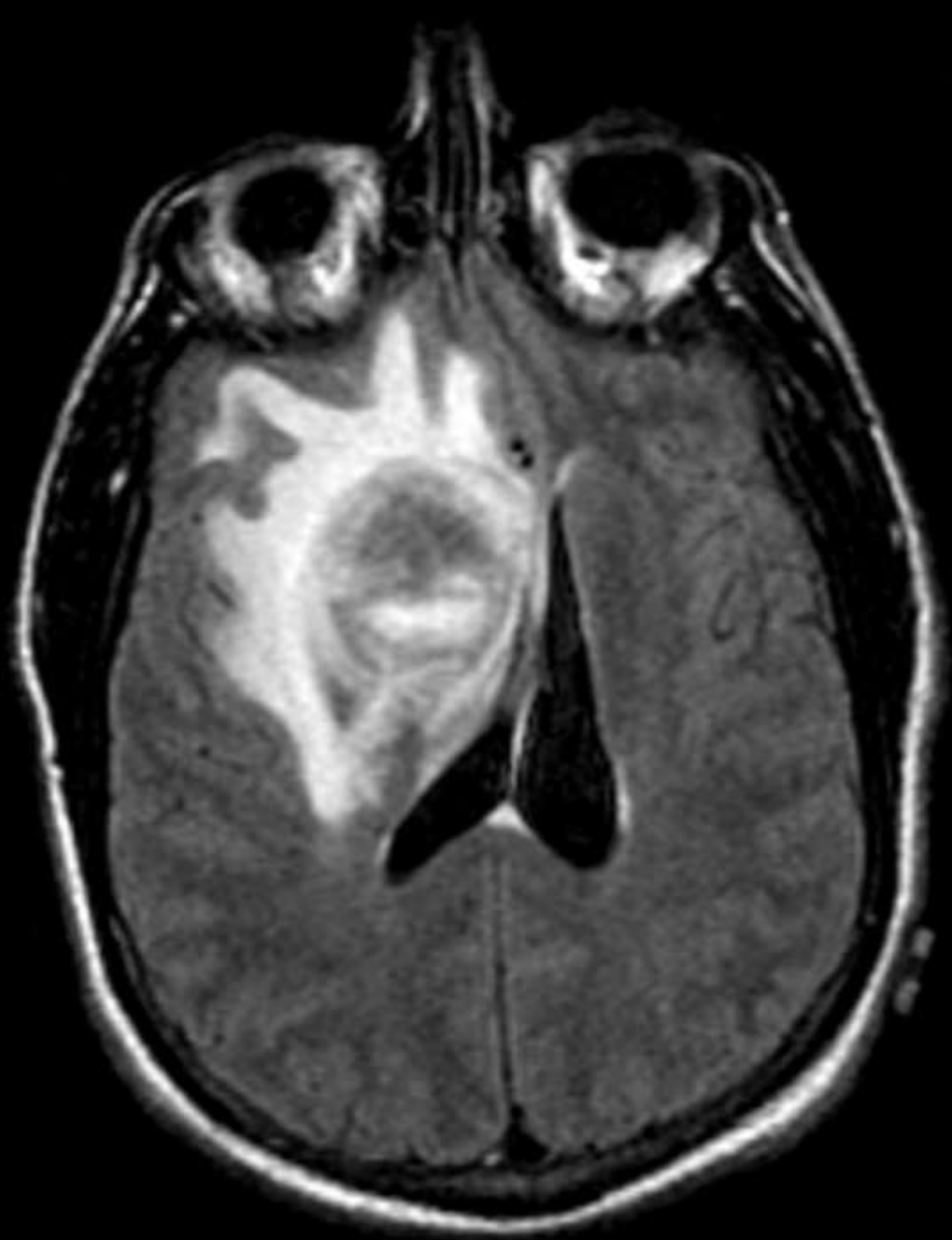
Mad cow disease was linked within the U. K., with new variant CJD, many bovines did they slay  
Psychiatric symptoms and ataxia at young age, homozygous Met at codon 129 will set the stage,  
histology shows (chorus)



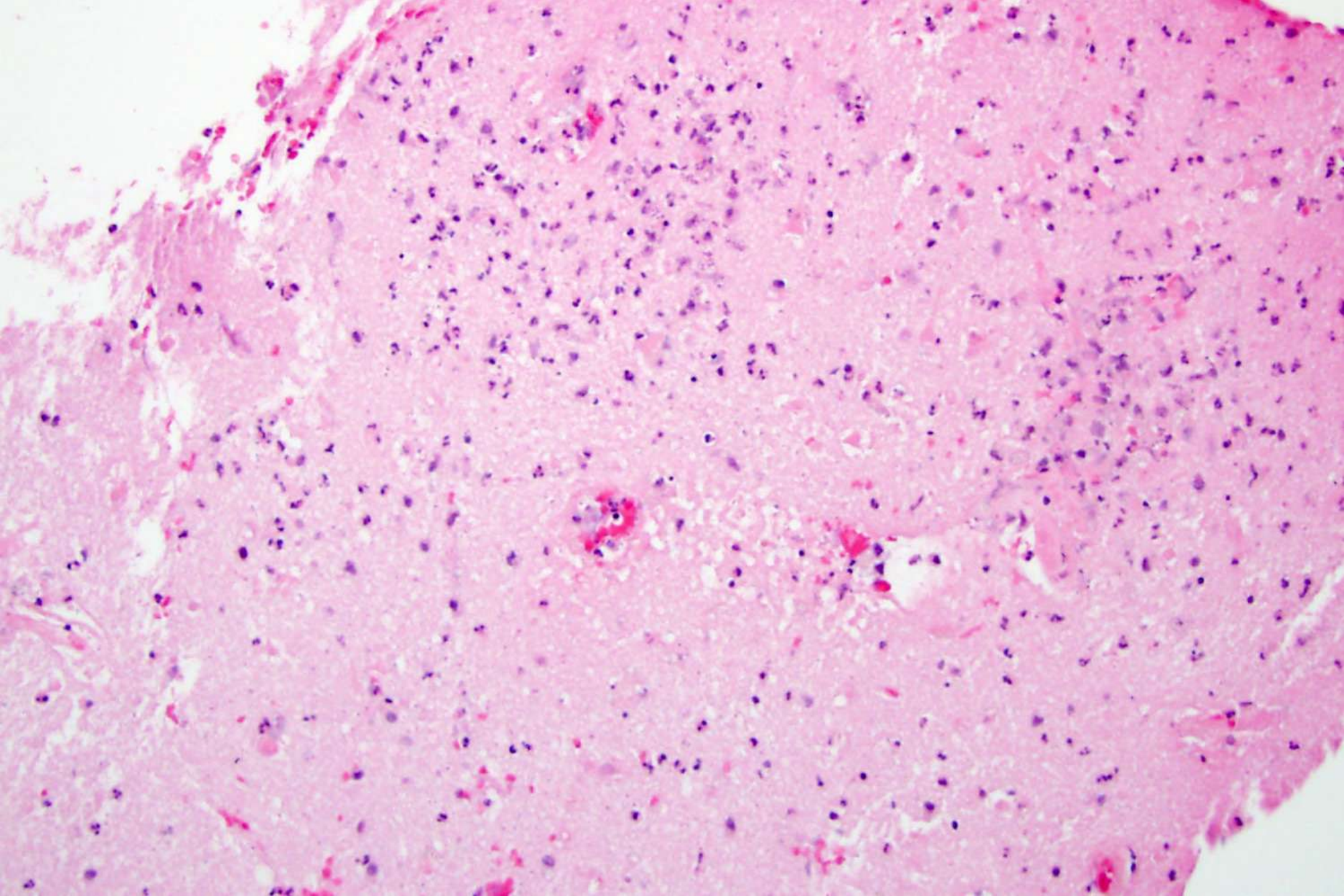


## NP CASE 5

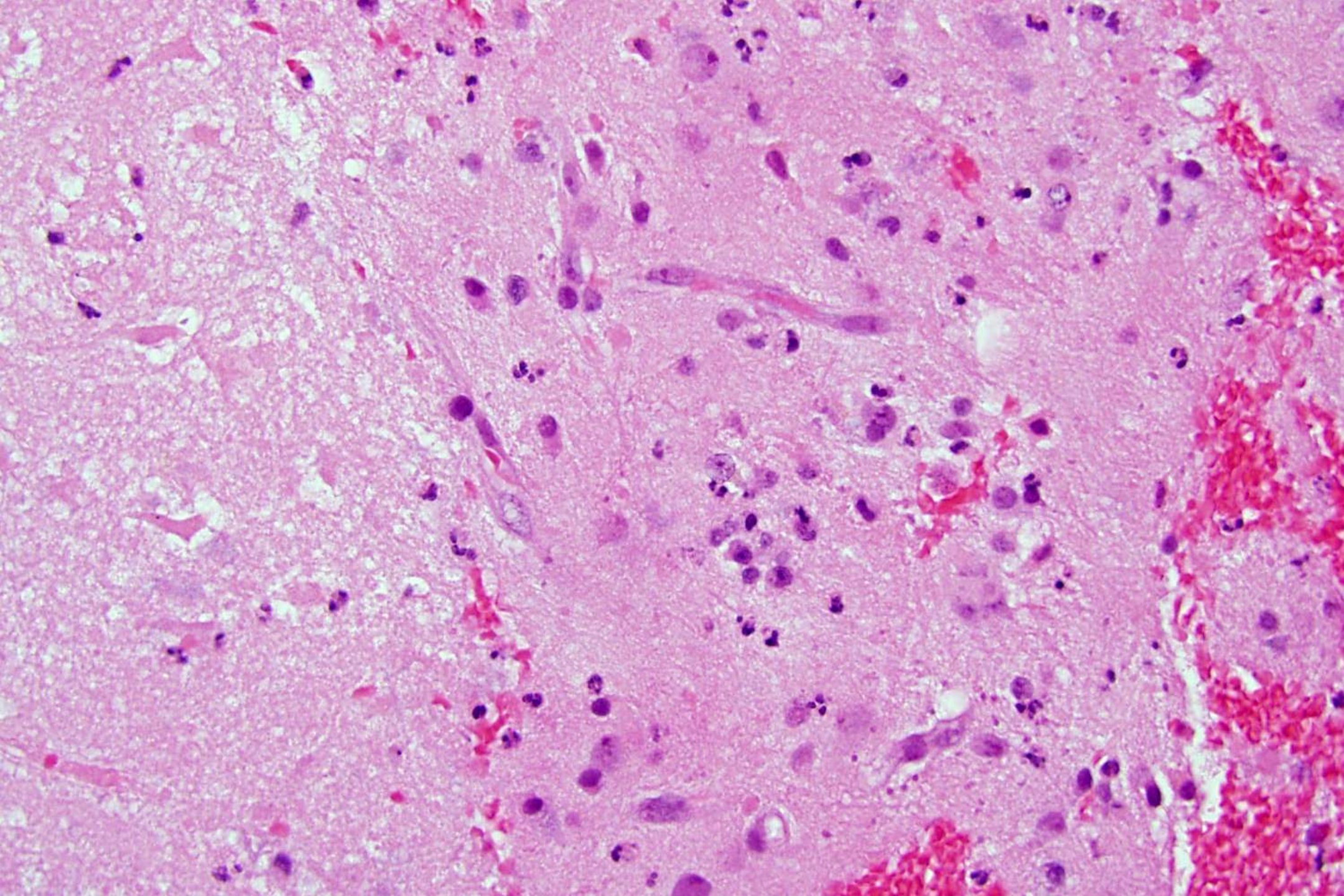
- 32 year old man presented with a two week history of left hemiparesis and headache
- Imaging revealed a rim-enhancing lesion in the right frontal lobe
- DDx: metastasis vs. GBM vs. abscess



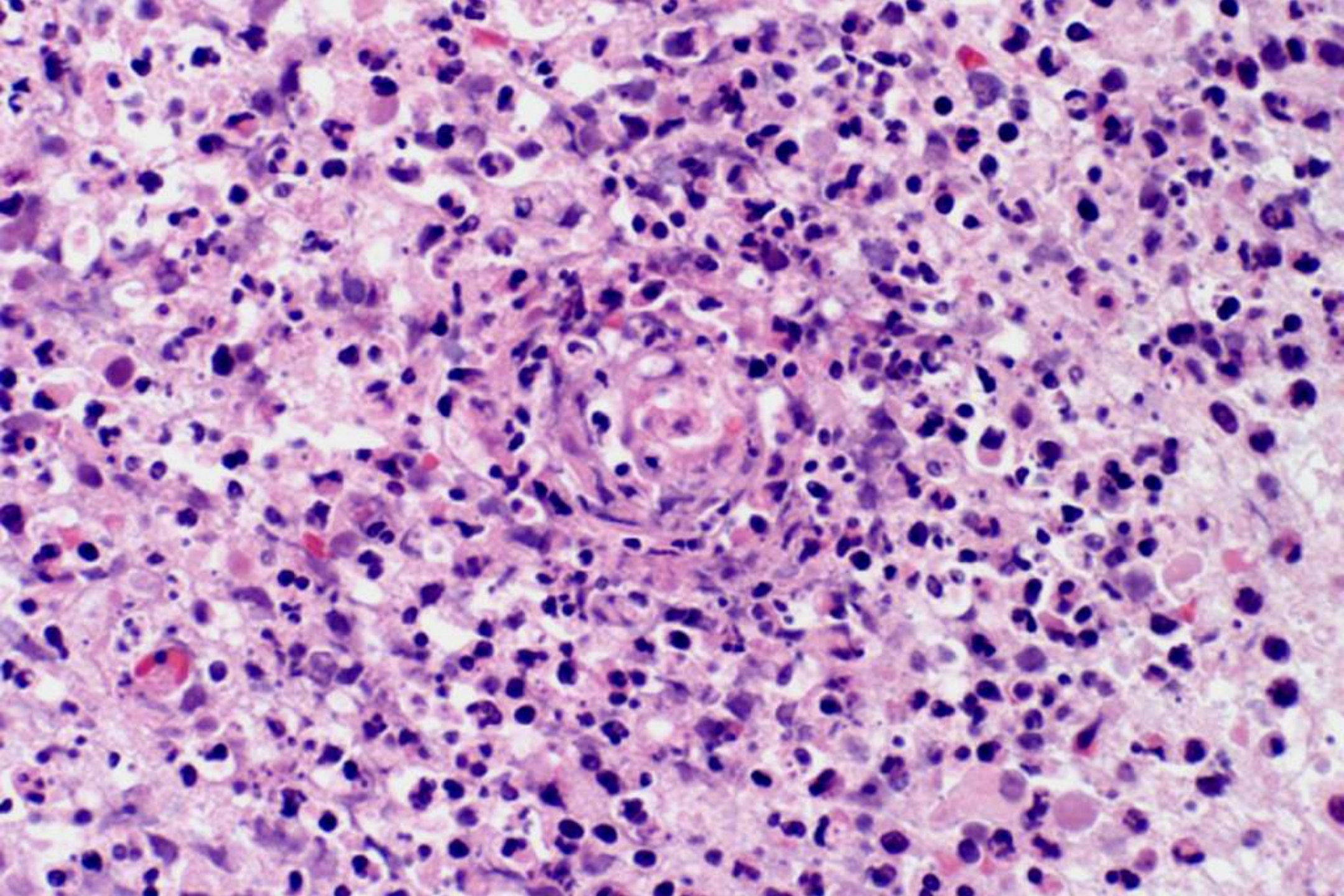




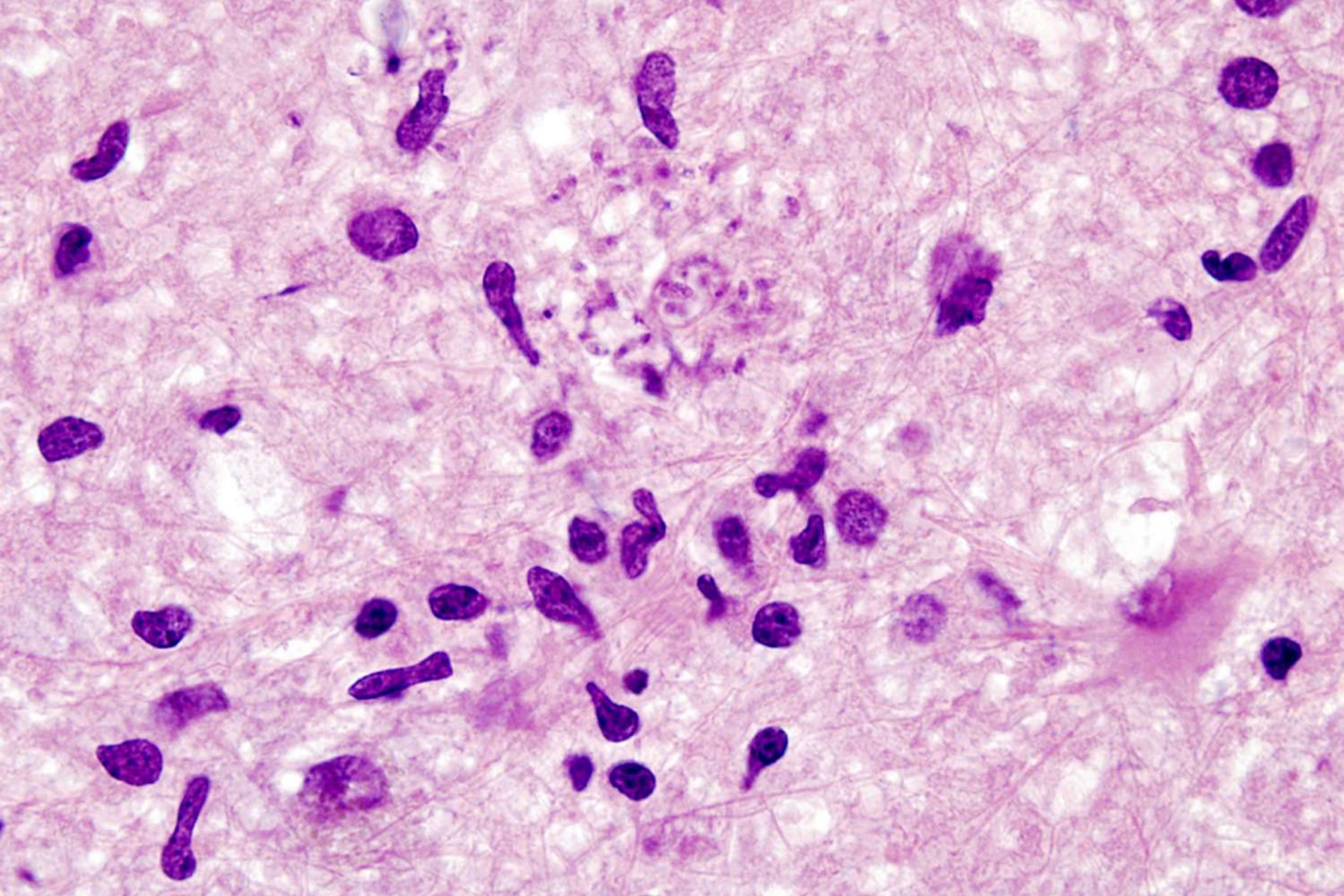




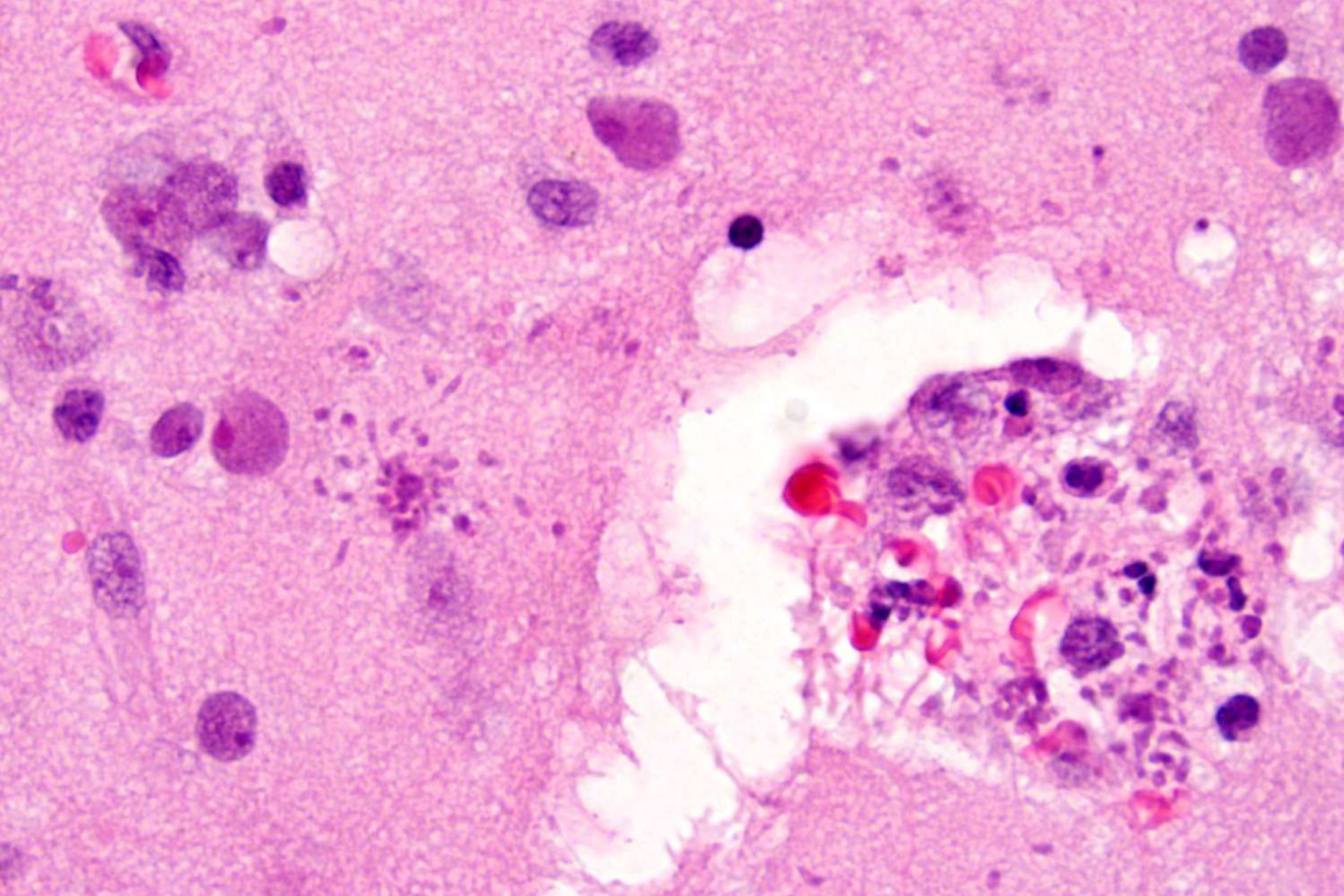




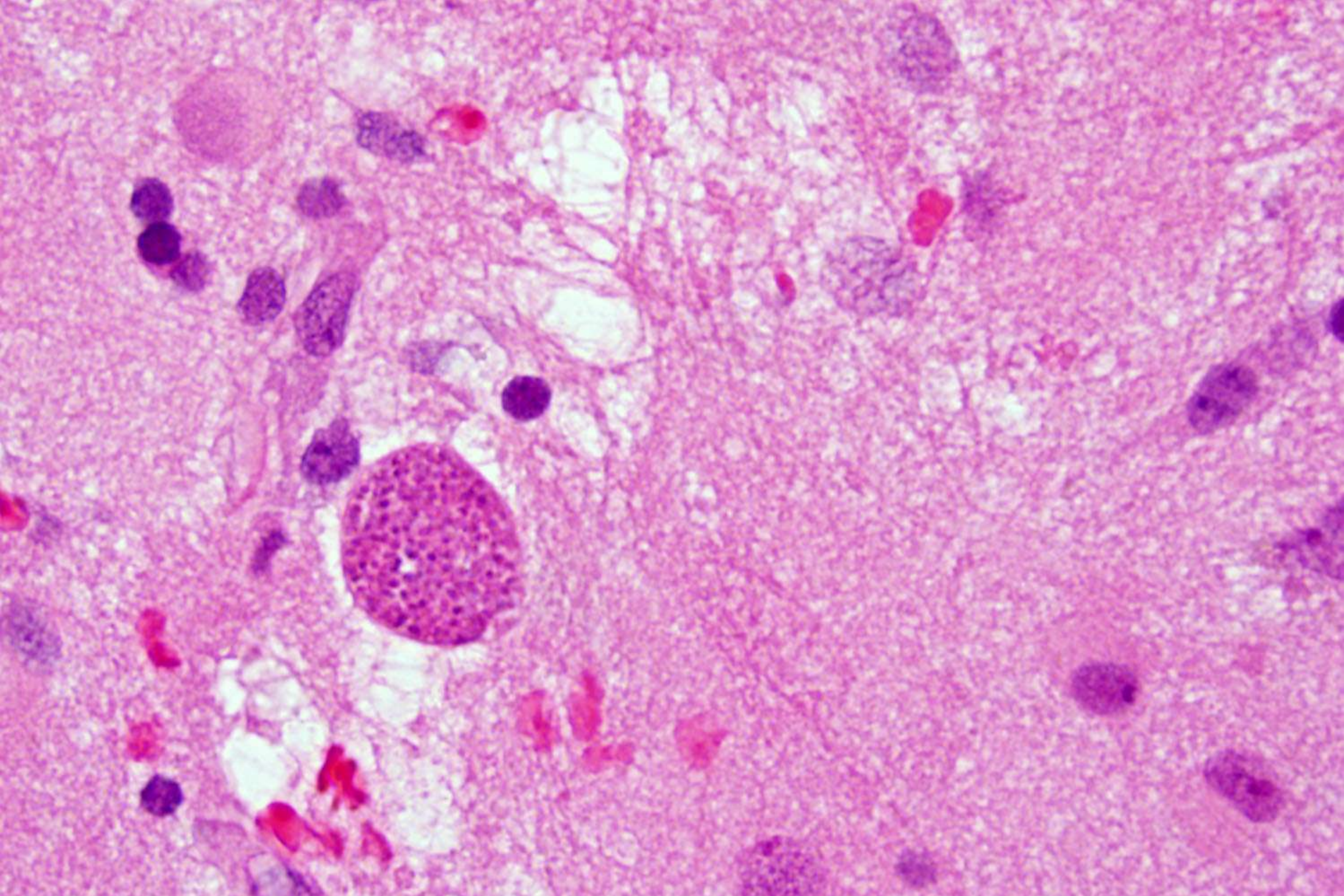


















# WHICH PATTERN(S)?

- Parenchymal Infiltrate with Hypercellularity
  - Solid Mass (Pure)
  - Solid and Infiltrative Process
  - Vasculocentric Process
  - Extra-axial Mass
  - Meningeal Infiltrate
  - Destructive/Necrotic Process
  - Subtle Pathology or Near Normal Biopsy
- 



# WHICH PATTERN(S)?

- Parenchymal Infiltrate with Hypercellularity
  - Solid Mass (Pure)
  - Solid and Infiltrative Process
  - Vasculocentric Process
  - Extra-axial Mass
  - Meningeal Infiltrate
  - **Destructive/Necrotic Process**
  - Subtle Pathology or Near Normal Biopsy
- 

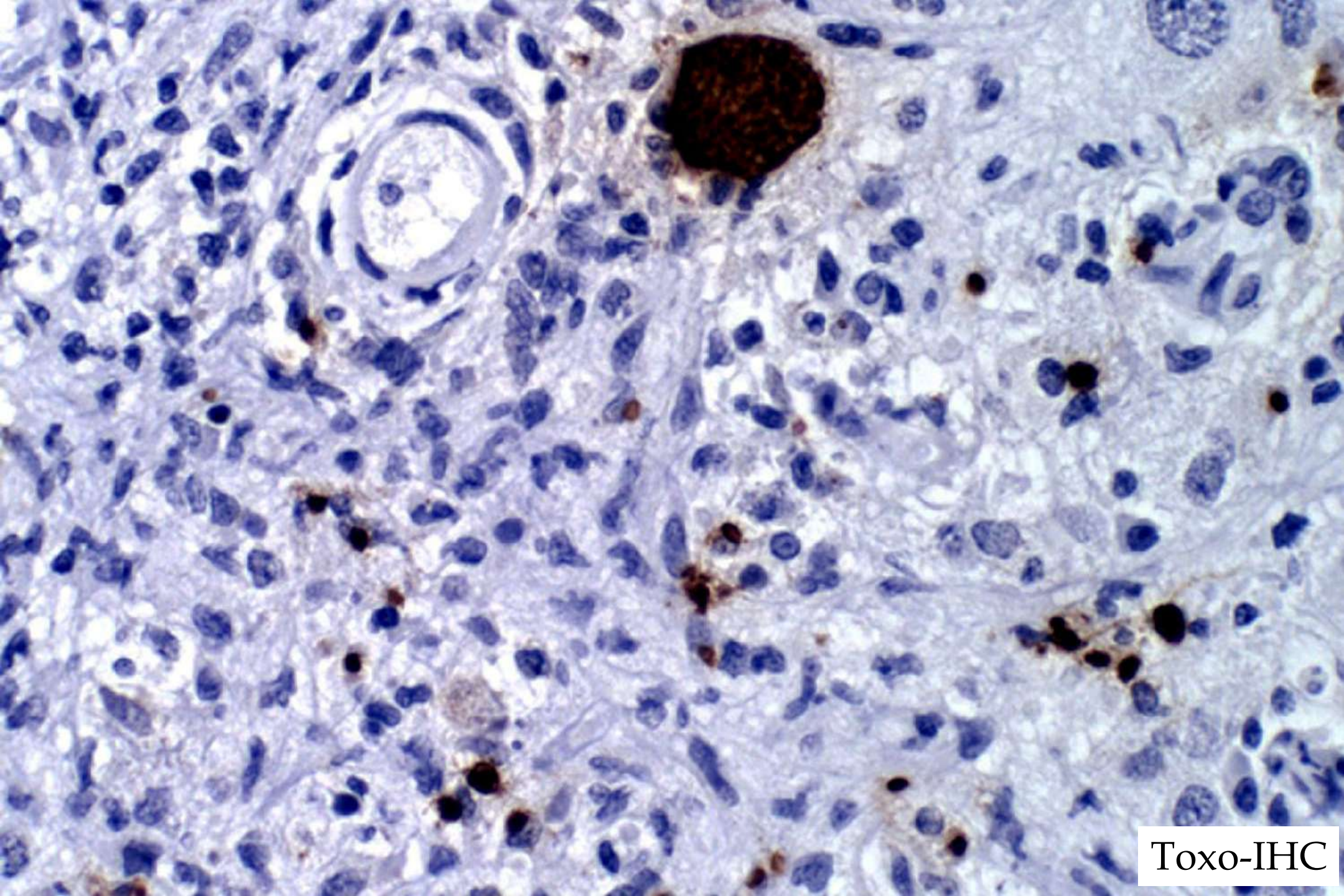




# WHAT IS YOUR FAVORED DIAGNOSIS?

- Bacterial abscess/cerebritis
- CNS Vasculitis
- Viral encephalitis
- Toxoplasmosis





Toxo-IHC

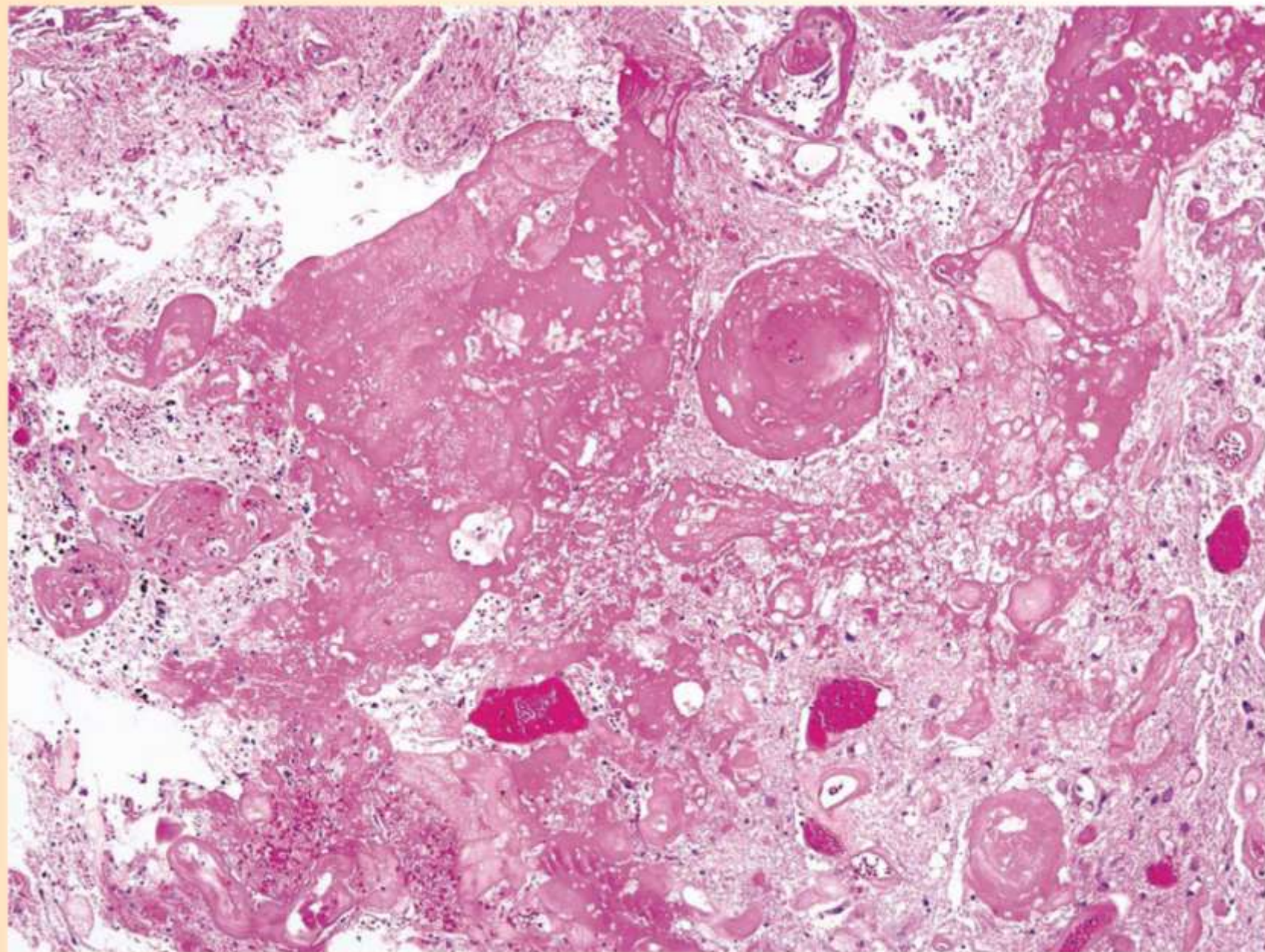




DX: TOXOPLASMOSIS



## Pattern 7: Destructive or Necrotic Process





Additional Findings	Diagnostic Considerations	Chapter/page
Fibrinoid brain necrosis, vascular hyalinization, telangiectasias	Radiation necrosis or treatment effects	(Ch. 19)
Angionecrosis	Radiation necrosis or treatment effects → Infection (toxoplasmosis) Vasculitis	(Ch. 19) (Ch. 21) (Ch. 24)
Vascular or perivascular inflammation	Lymphoma (immunosuppressed host) Severe demyelinating disease (rare) Vasculitis	(Ch. 14) (Ch. 22) (Ch. 24)
Intraluminal infiltrate	Intravascular lymphoma	(Ch. 14)
Granular vascular deposits	CADASIL	(Ch. 24)
Eosinophilic necrotic neurons	Acute cerebral infarct	(Ch. 24)
Neutrophil-rich infiltrate	→ Infection (abscess) Acute cerebral infarct (rare)	(Ch. 21) (Ch. 24)
Macrophage-rich infiltrate	Severe demyelinating disease (rare) Metabolic or toxic disorders Cerebral infarct	(Ch. 22) (Ch. 22) (Ch. 24)
Granulomas or giant cells	Infections (TB, fungal) Vasculitis	(Ch. 21) (Ch. 24)
Viral inclusions	Encephalitis (HSV)	(Ch. 21)

# CNS TOXOPLASMOSIS

- Opportunistic infection
- AIDS / Neonates (TORCH)
- Necrotizing encephalitis
- Free and encysted organisms in tissue
- Medically treatable!



# CNS TOXOPLASMOSIS

- Rim-enhancing masses can mimic tumors
- Secondary vasculitis common, so typically necrotizing
- Cerebritis or abscesses
- Often includes an encephalitis pattern with microglial nodules

A photograph of a person in a gondola on a canal, viewed through the arch of a bridge. The water is blue and rippled. The bridge is made of stone or concrete. On the right side, there is a wooden structure with a lattice pattern, possibly a railing or part of a building. The overall scene is serene and typical of Venice.

**Toxoplasmosis**



# TOXOPLASMOSIS



Music to 'O Sole Mio by E. di Capua, Lyrics by Arie Perry,  
M.D.

Toxoplasma gondii, an opportunistic parasite,  
afflicting patients who are immunocompromised  
In the central nervous system, lesions are necrotizing,  
in neonates and HIV, that is where you're gonna see, a problem

Ch: Toxoplasmosis, a feline pest, keep it in your differential,  
so you don't fail the test  
Remember, it's treatable, with the right antibiotics, lesions regress

On brain biopsy, of an enhancing lesion,  
there's vasculitis and encephalitis  
Abscess formation and rod cell activation,  
there are bradyzoite cysts and tachyzoites exist as free forms (chorus)