

# ENCAPSULATED LESIONS WITH FOLLICULAR PATTERN

**Elsa Fonseca**

Faculdade de Medicina da Universidade do Porto  
IPATIMUP

Hospital de S. João - Porto

# ENCAPSULATED LESIONS WITH FOLLICULAR PATTERN

Follicular adenoma and Follicular carcinoma

Follicular variant of papillary carcinoma

Well-differentiated tumour of uncertain malignant potential (WT-UMP)

Follicular tumour of uncertain malignant potential (FT-UMP)

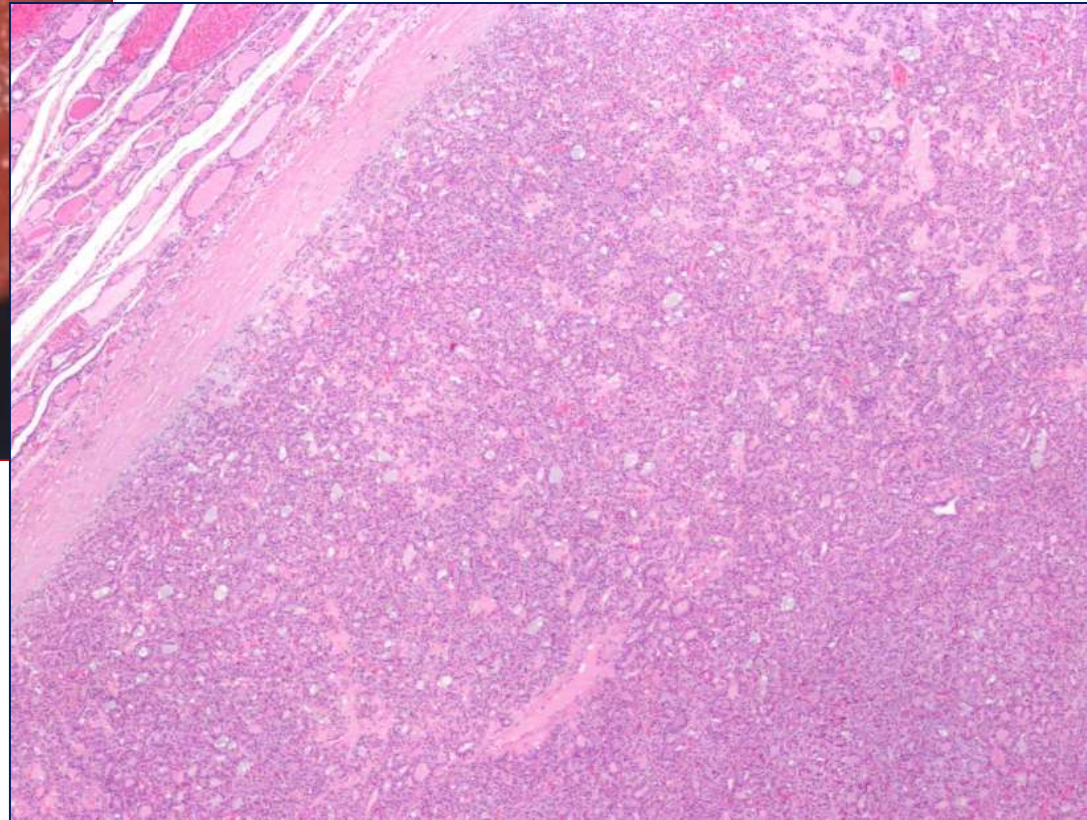
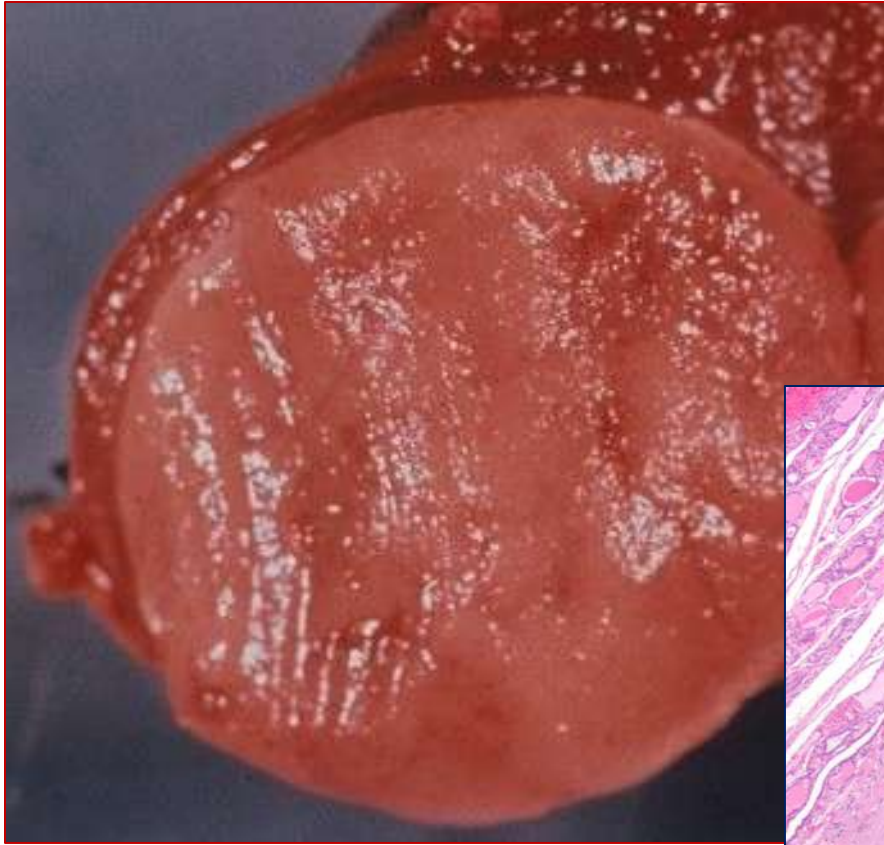Well-differentiated carcinoma, NOS (WDC, NOS)

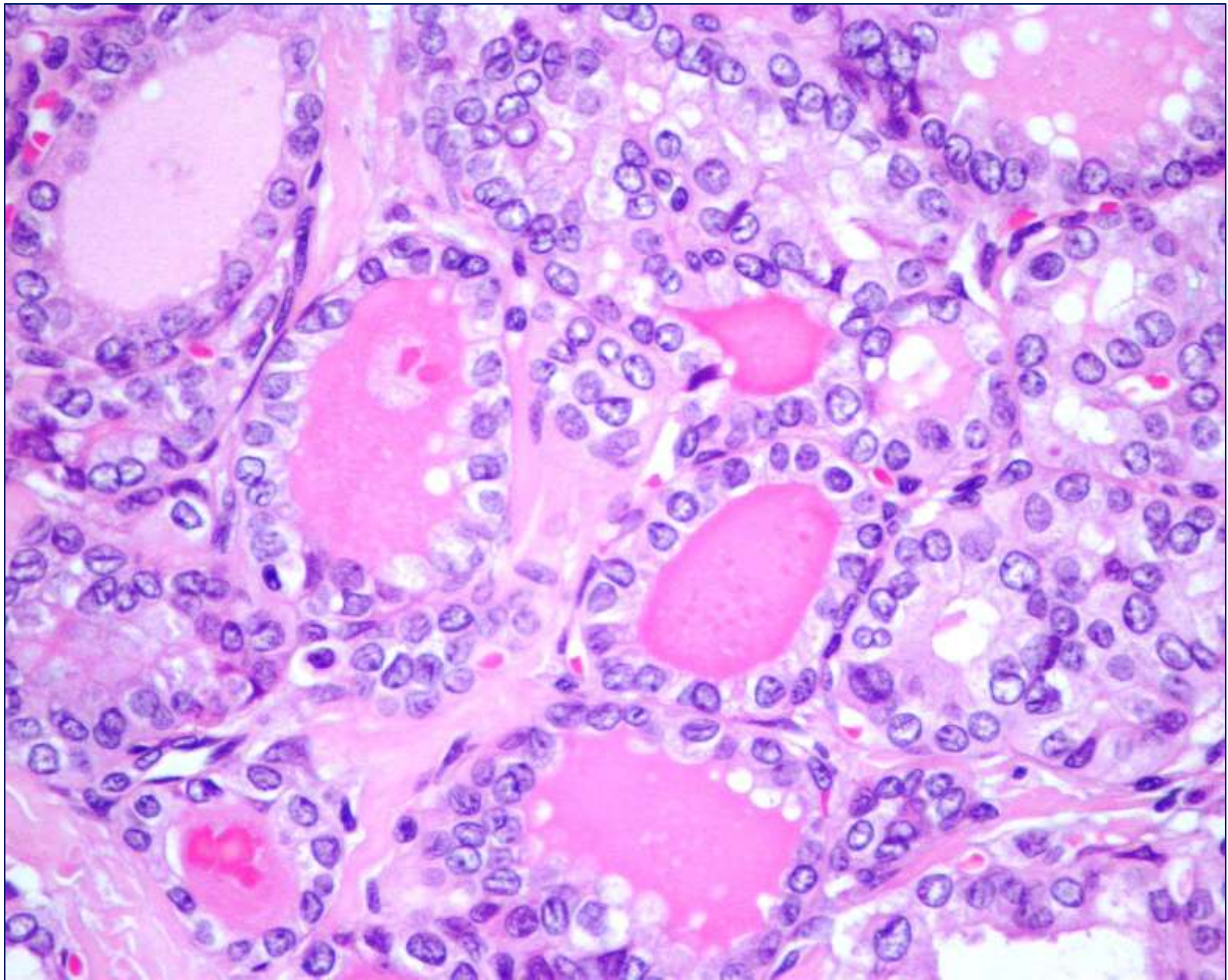


## The day to day of the thyroid pathologist

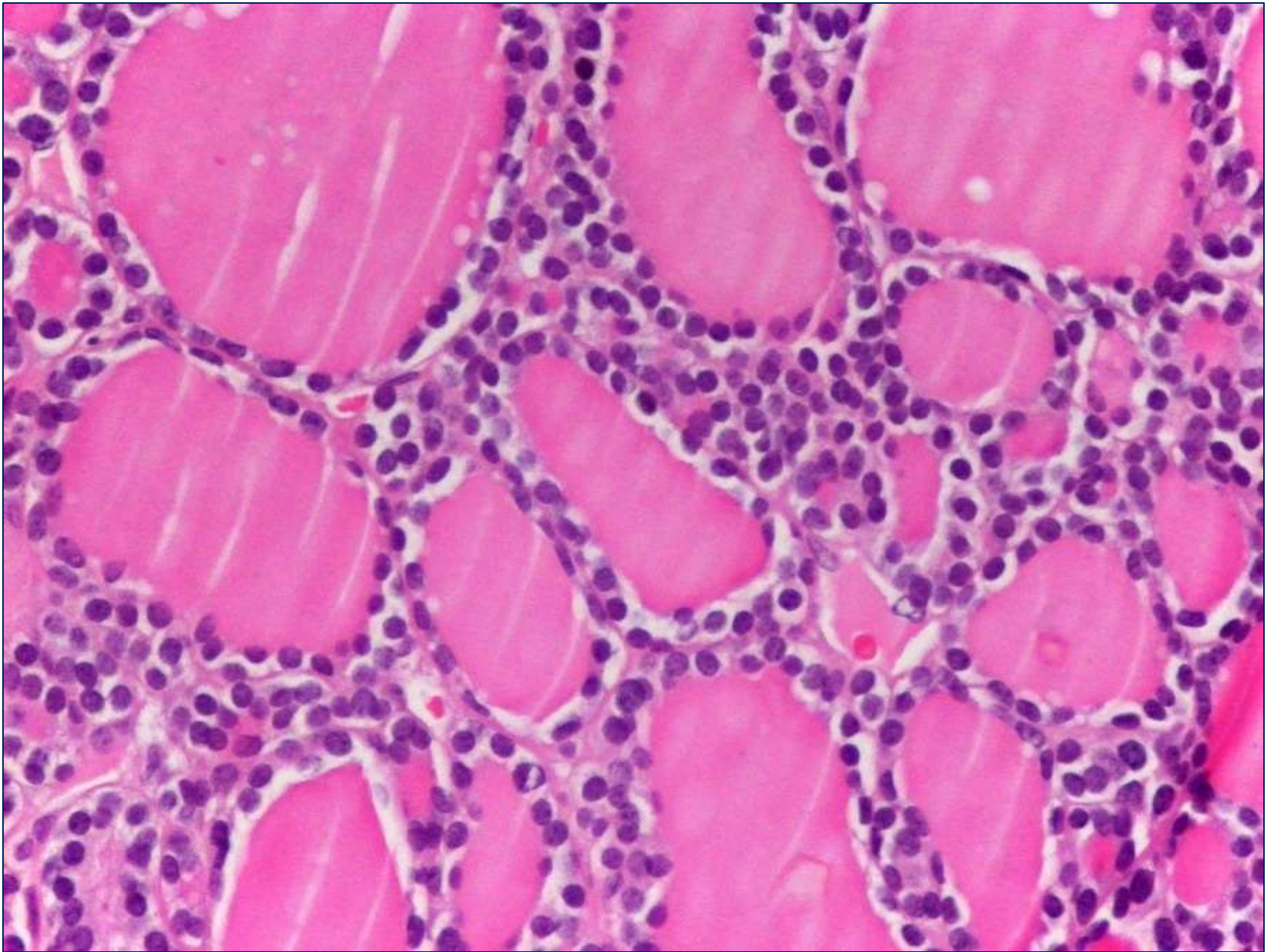
- Is it a follicular variant of papillary carcinoma?
- Is it a follicular adenoma or a follicular carcinoma?
- Are these nuclear features typical of papillary carcinoma?
- Is this “true” capsular invasion?
- Is this “true” vascular invasion?

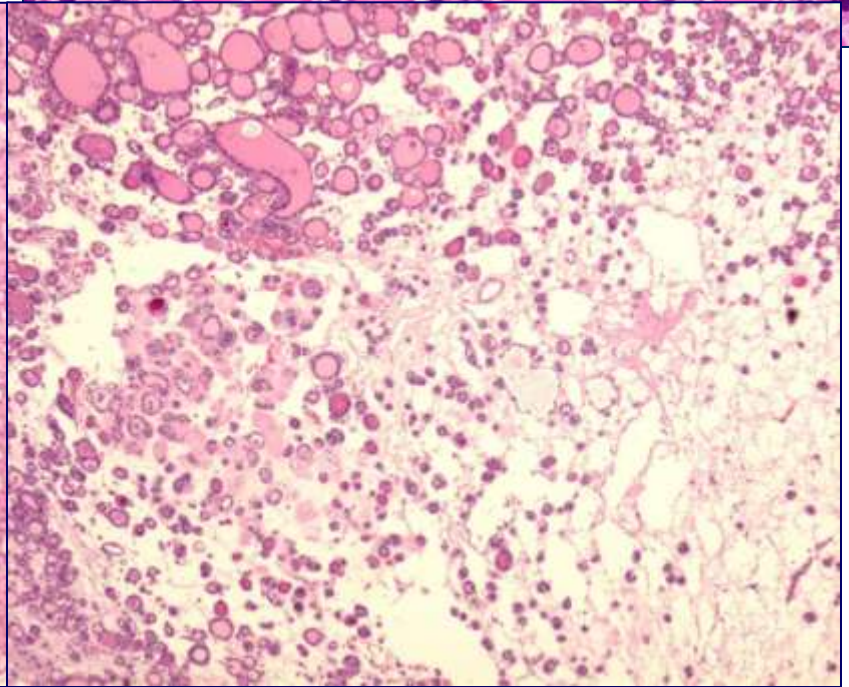
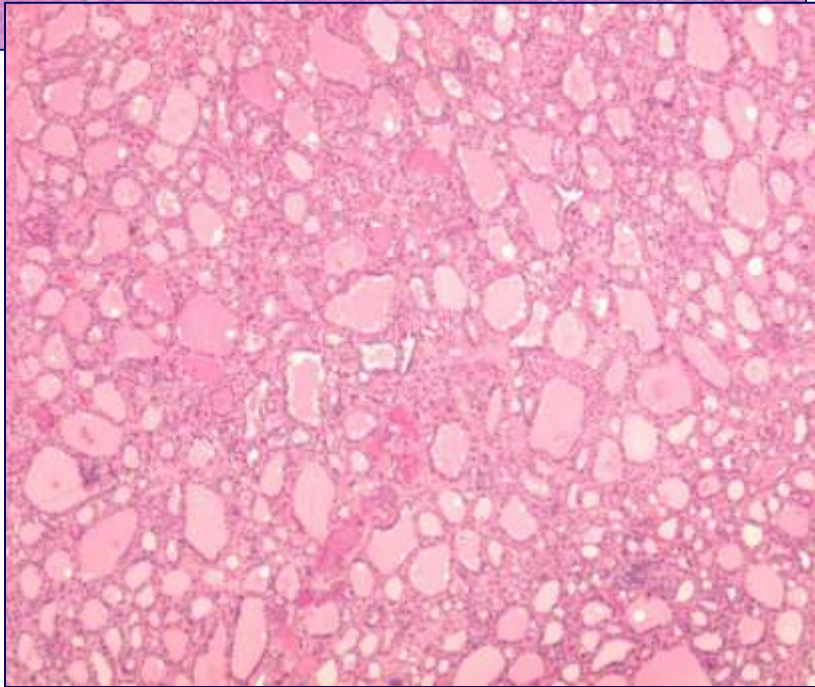
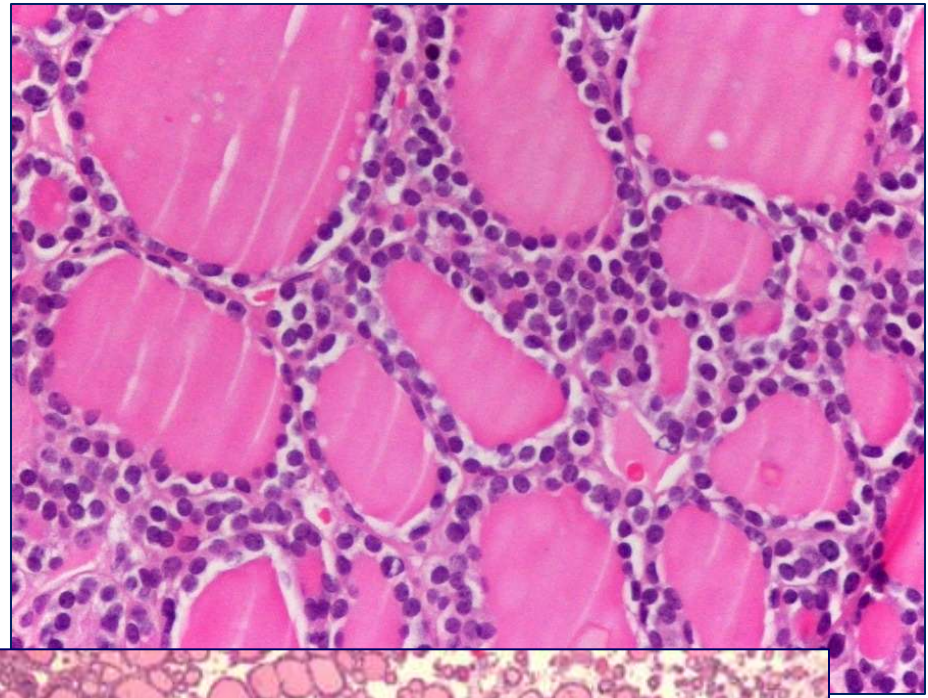
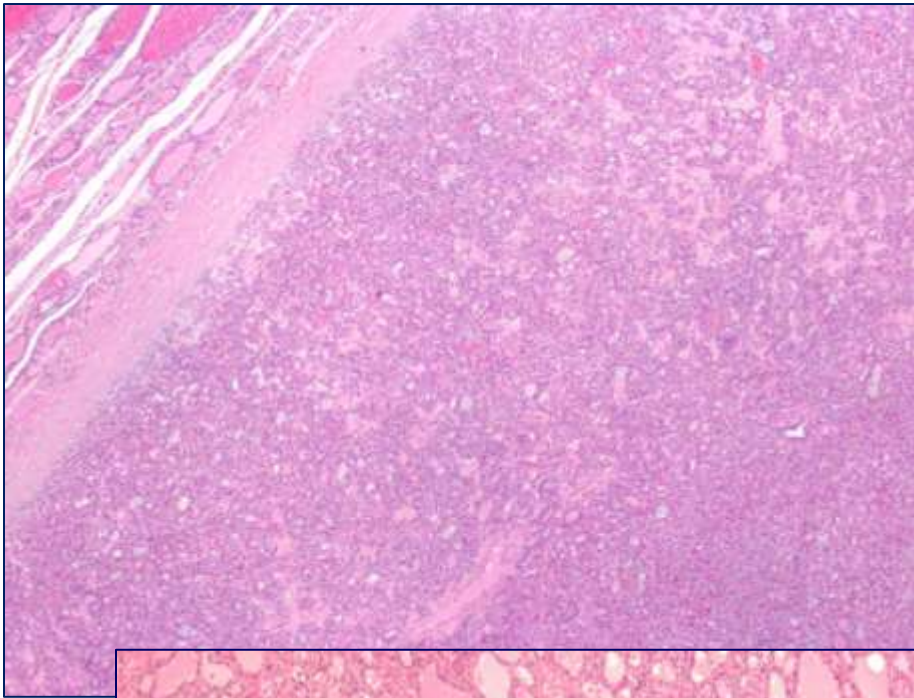
# Encapsulated thyroid nodule

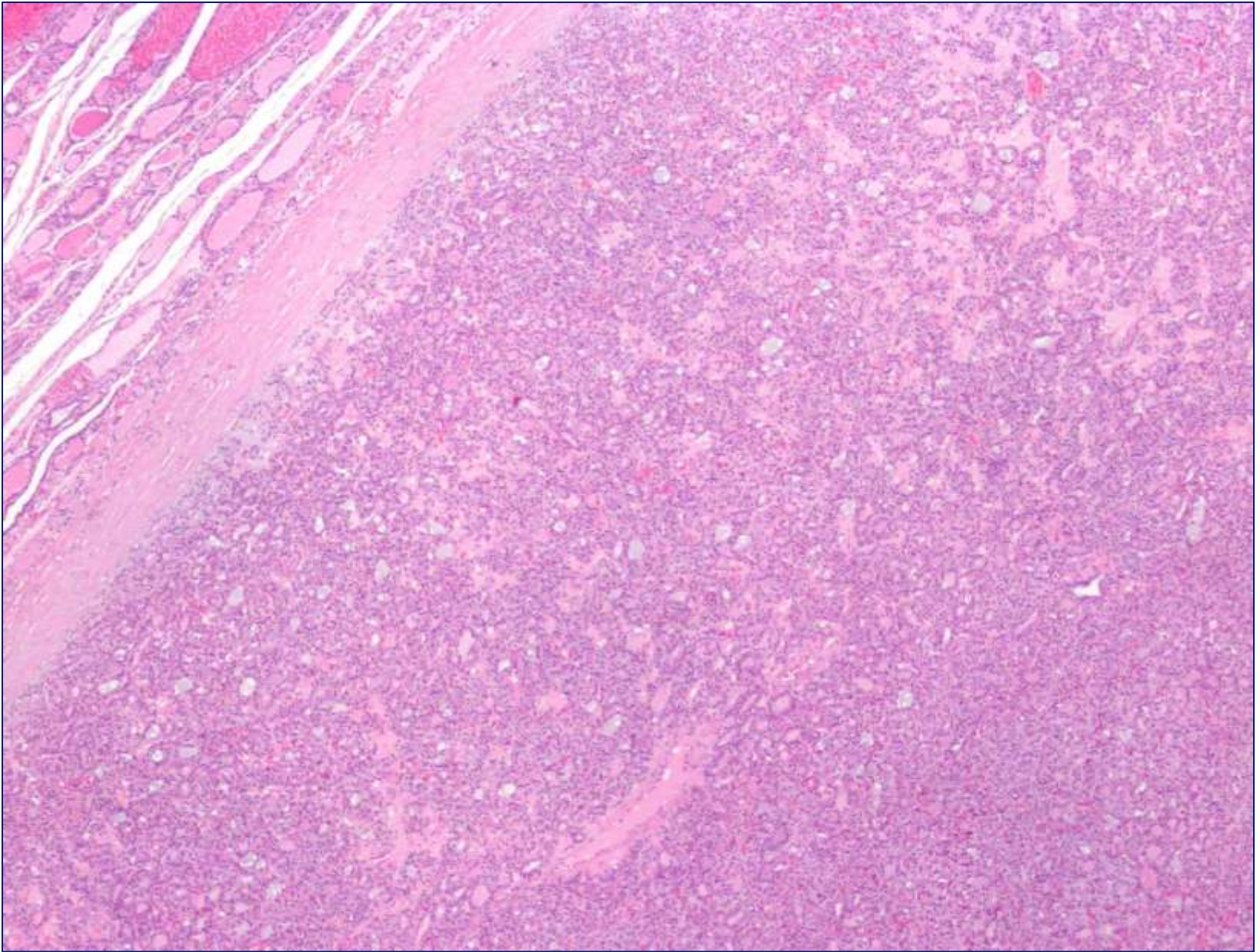




Follicular variant of papillary carcinoma



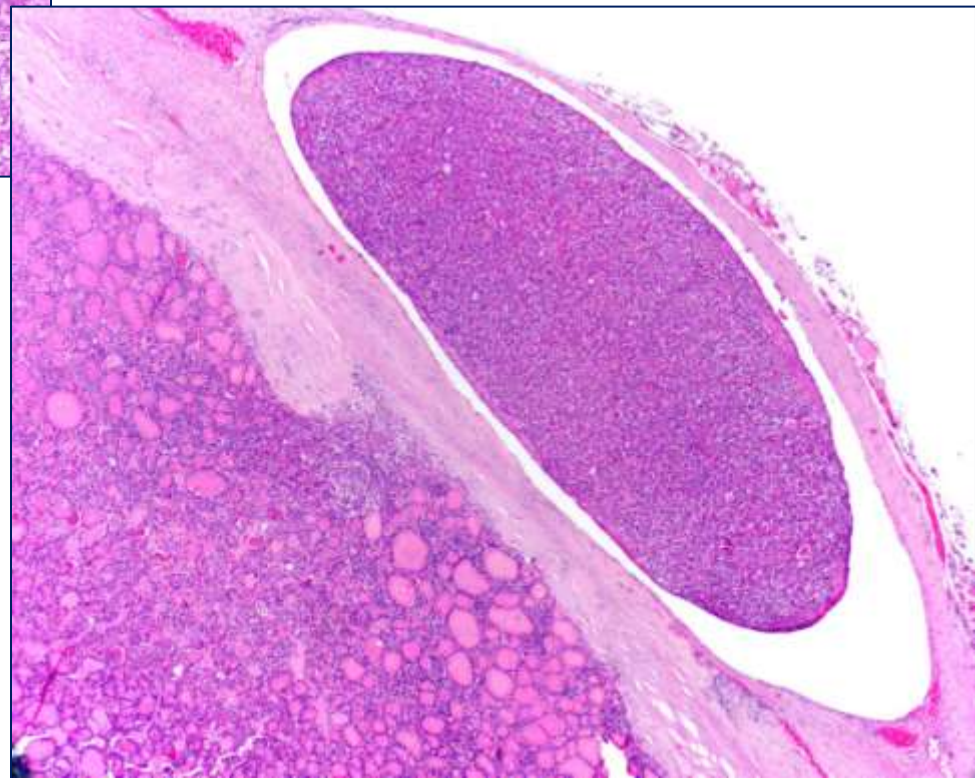
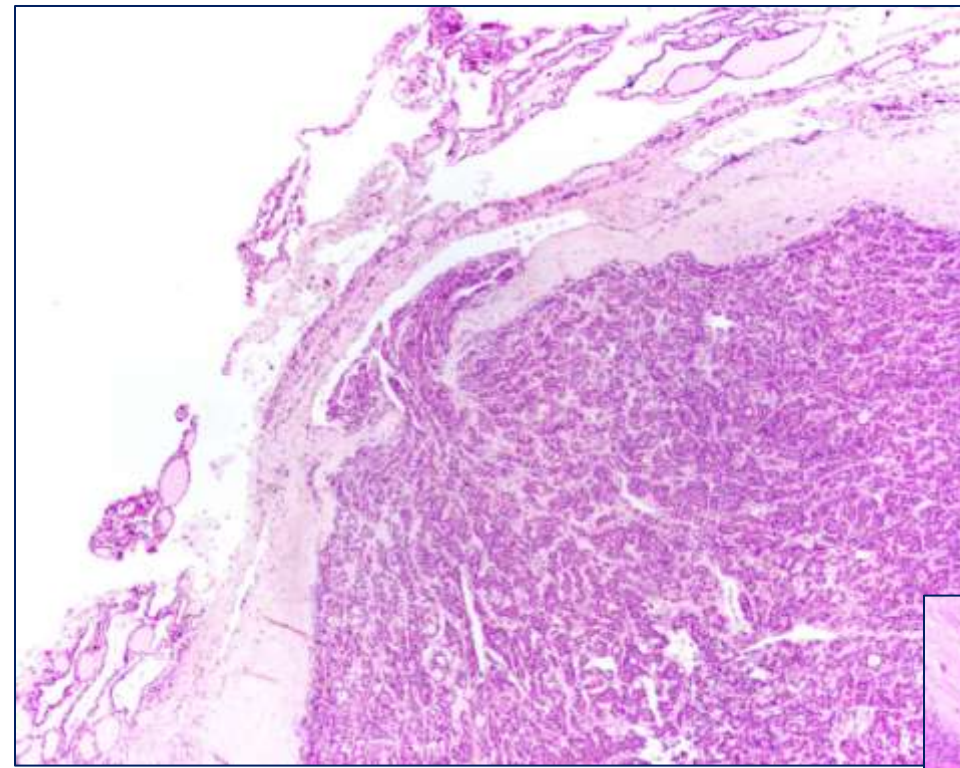


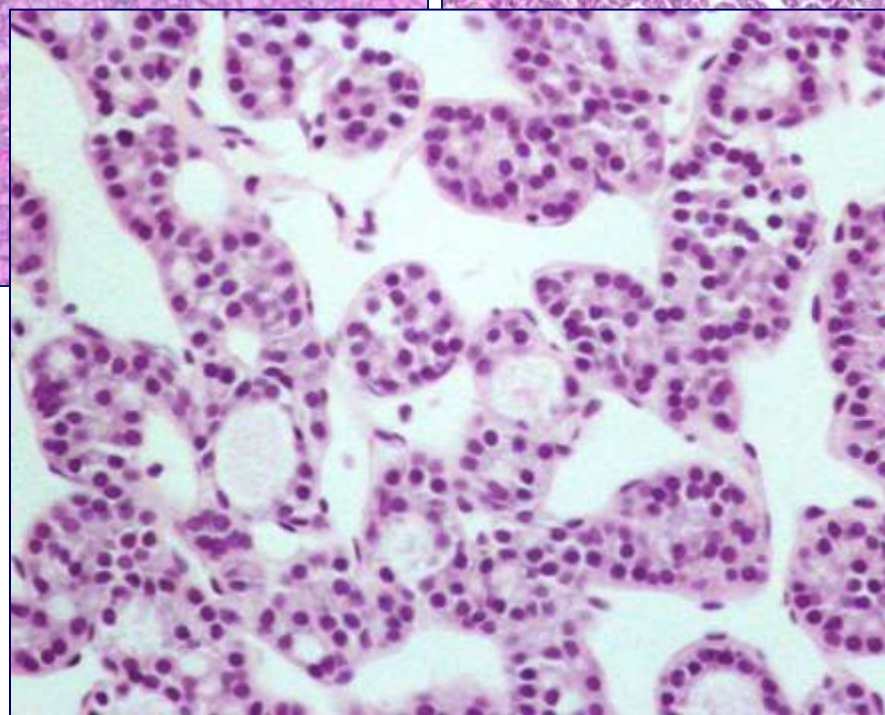
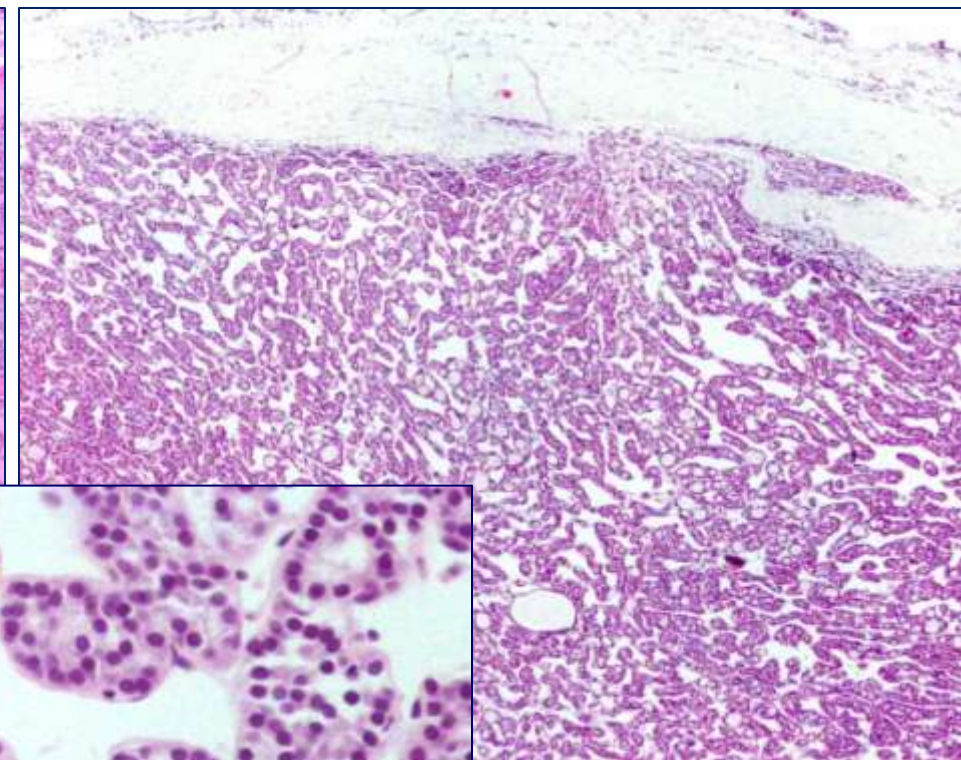
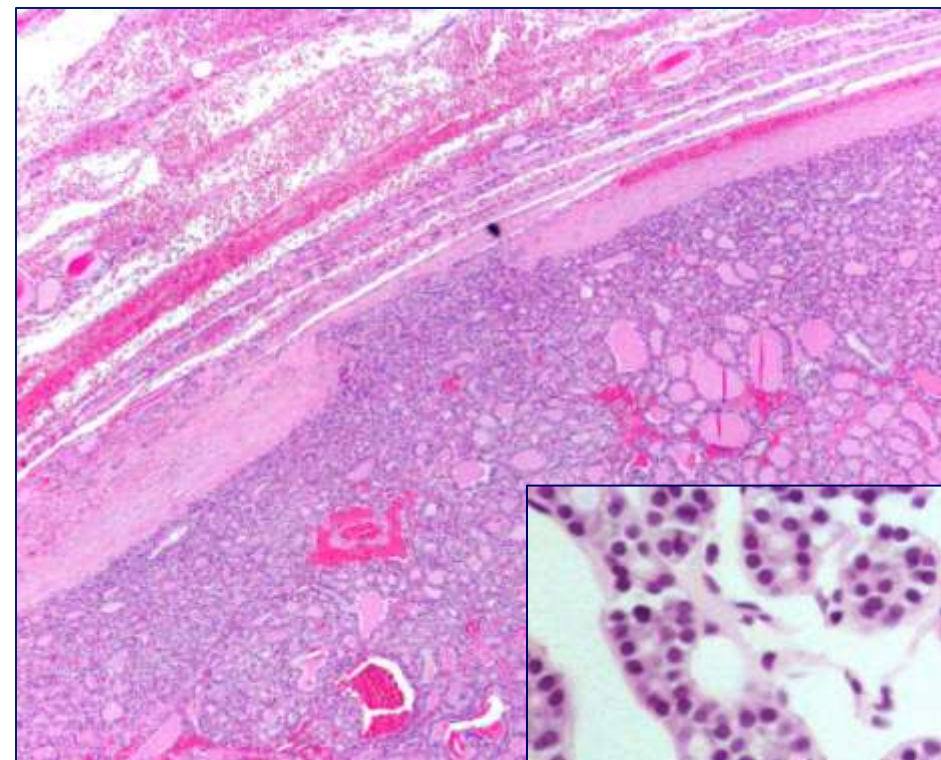


Follicular adenoma

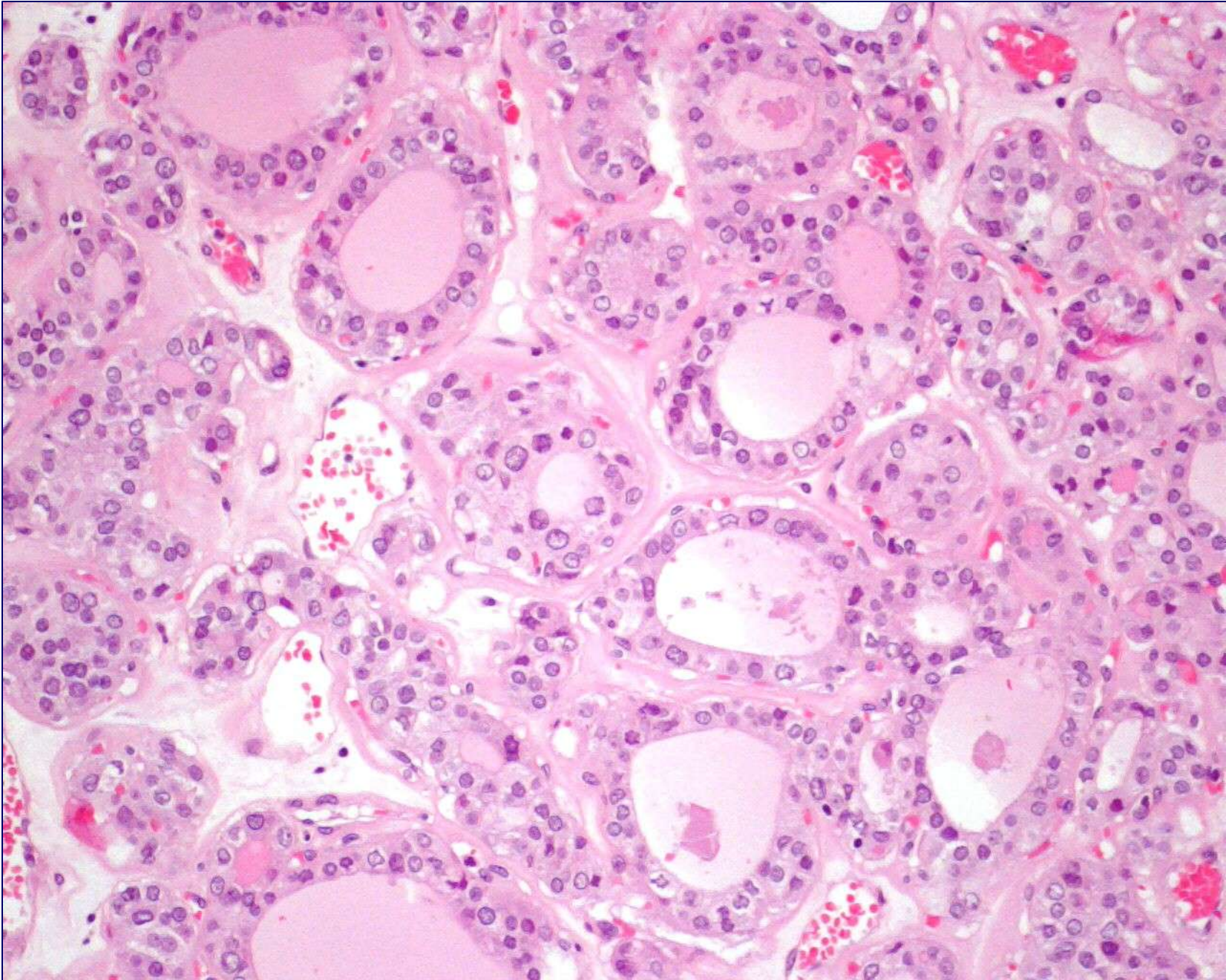


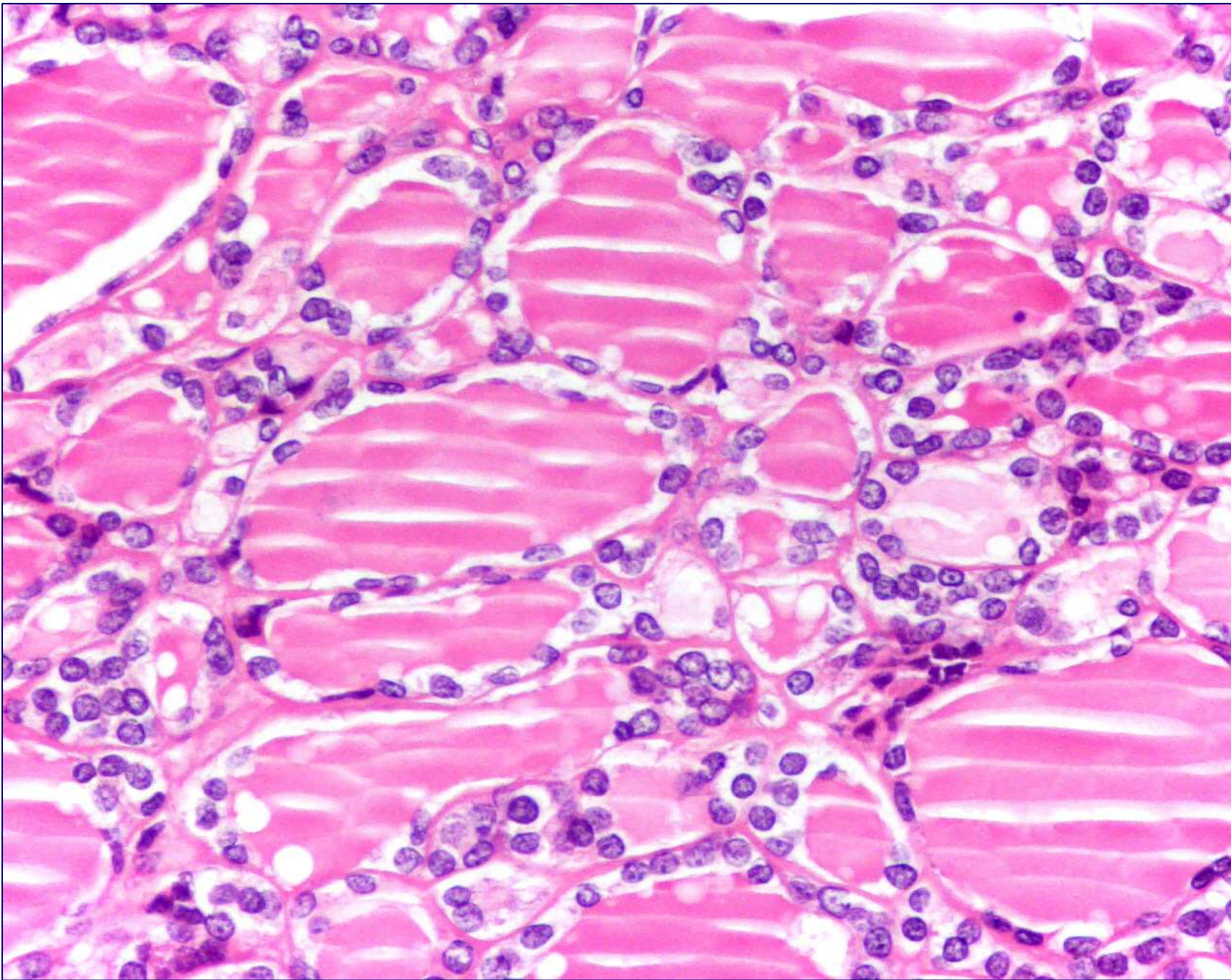
## Follicular carcinoma

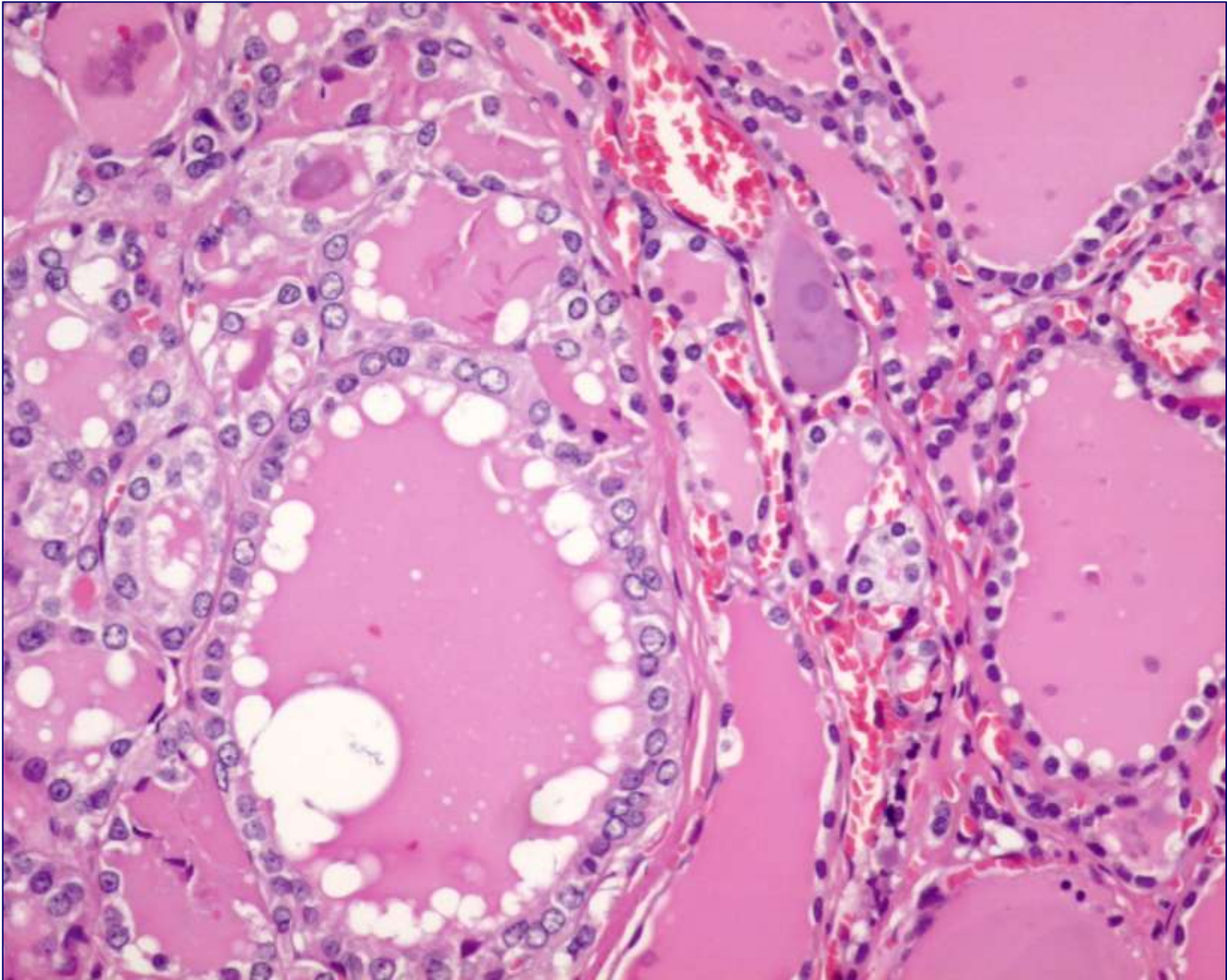


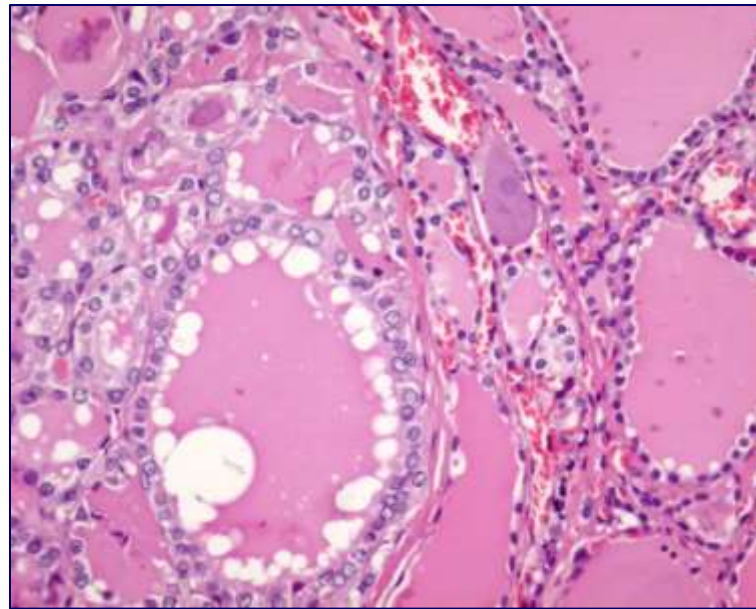
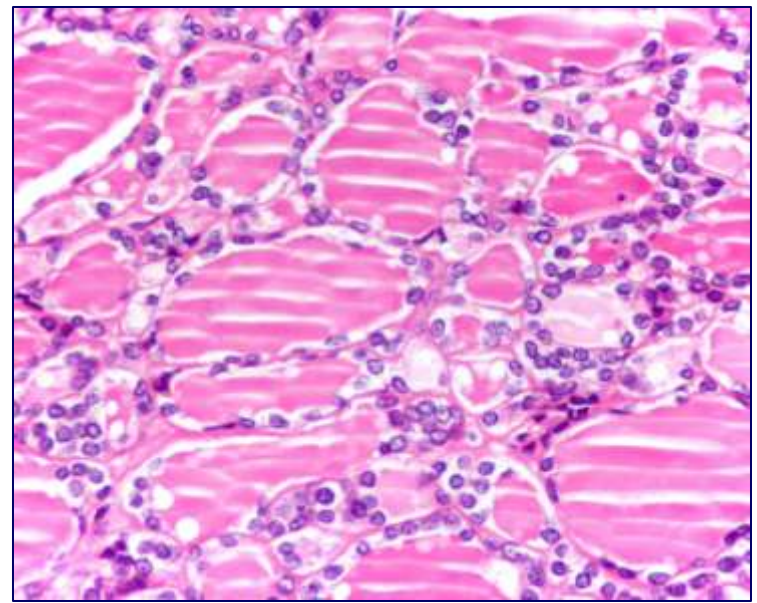
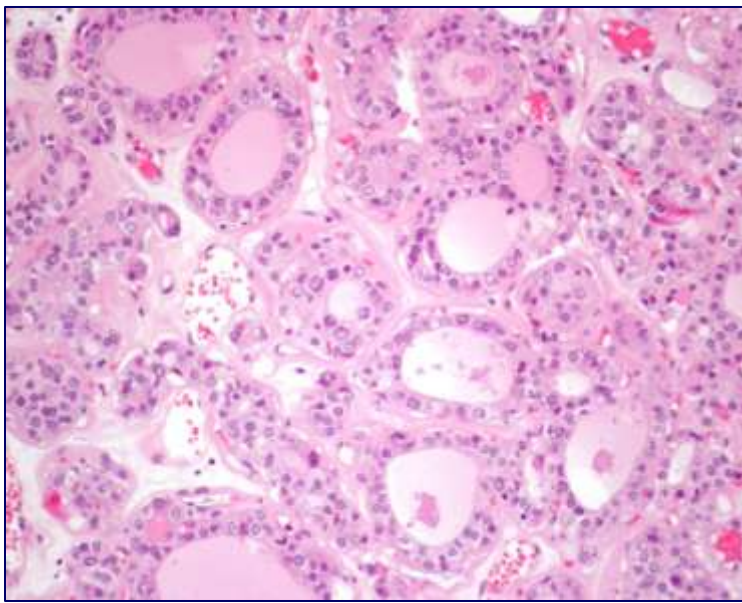


Follicular tumour of uncertain malignant potential (FT-UMP)

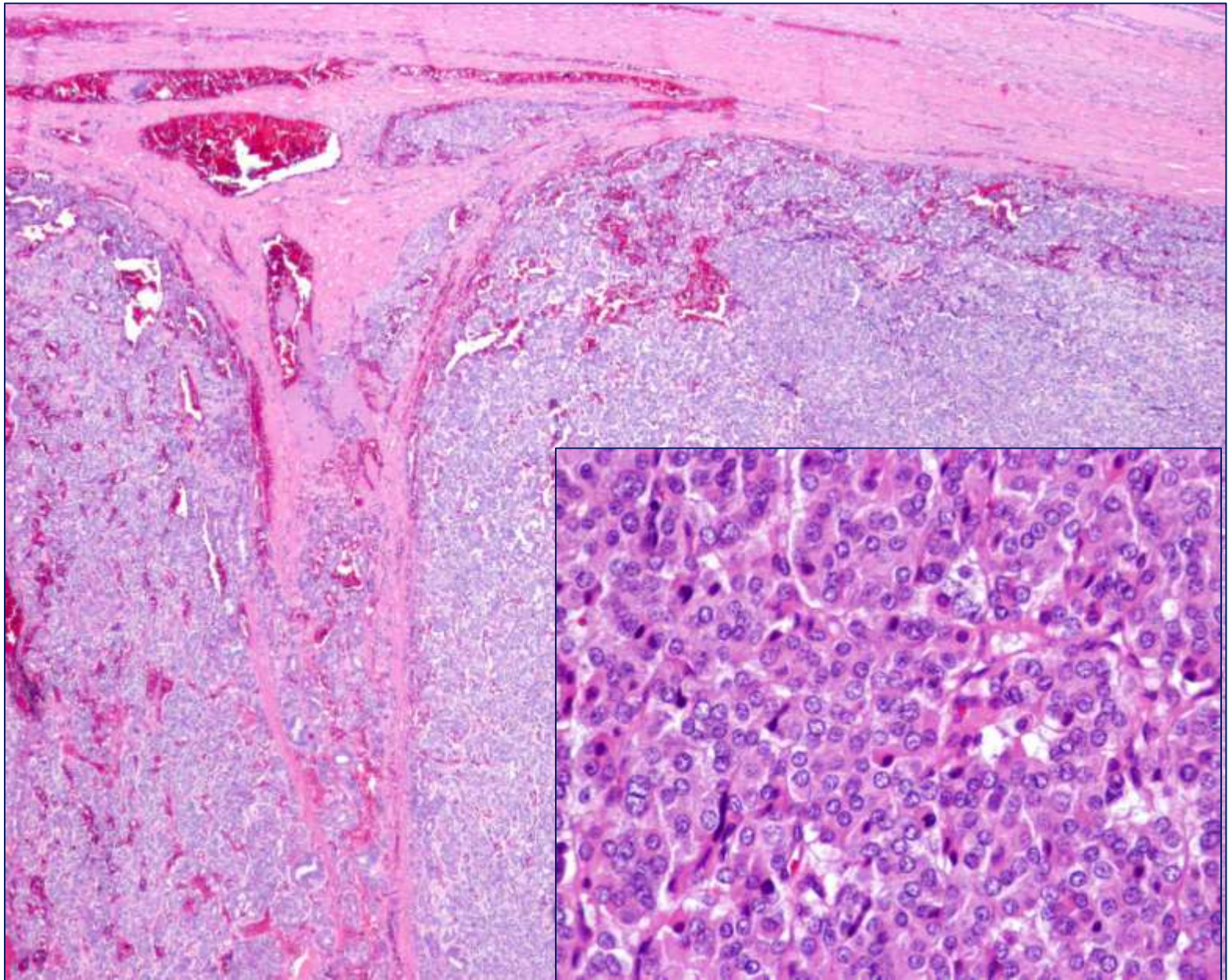






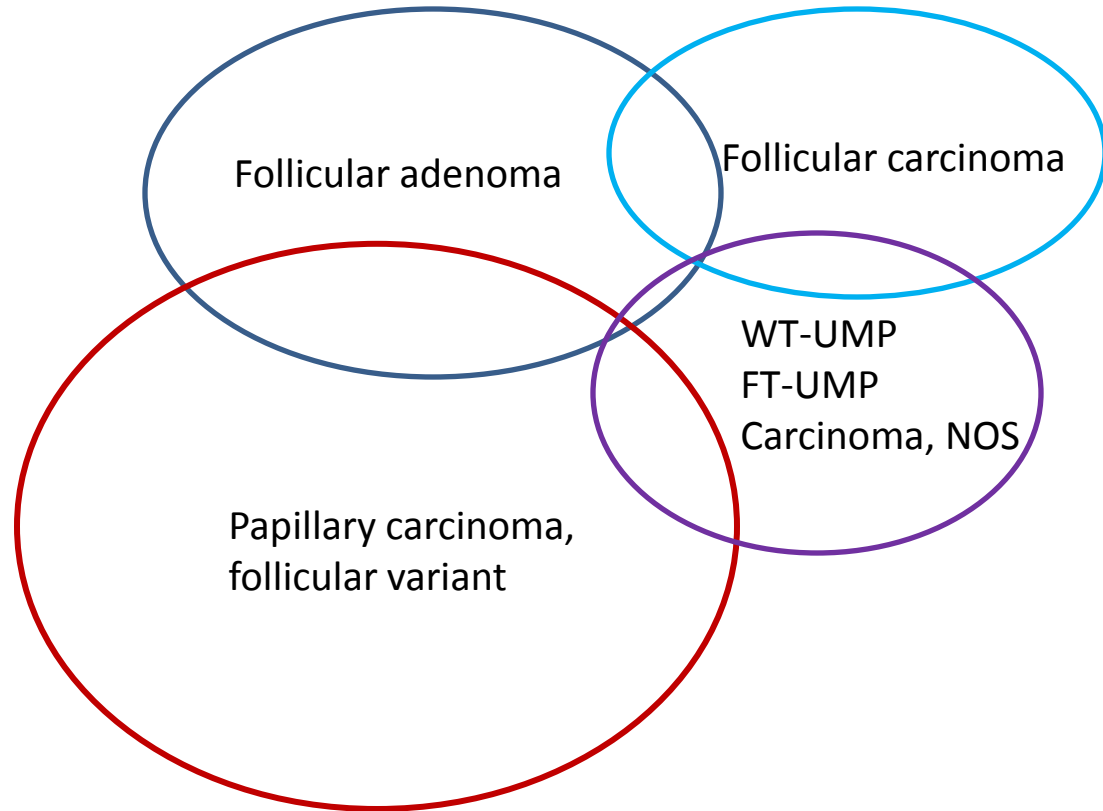
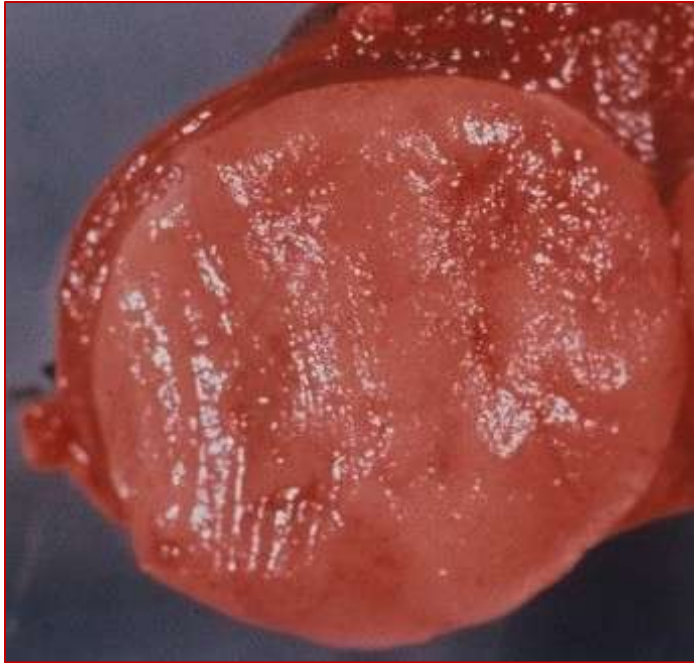

Well-differentiated tumors of uncertain malignant potential (WT-UMP)?  
Papillary carcinoma?



Well-differentiated carcinoma, NOS (WDC, NOS)

# Encapsulated follicular tumours







Gracias