

XXV Congreso de la Sociedad Española de Anatomía Patológica Y División de la International Academy of Pathology. XX Congreso de la Sociedade Española de Citología Y I Congreso de la Sociedad Española de Patología Forense



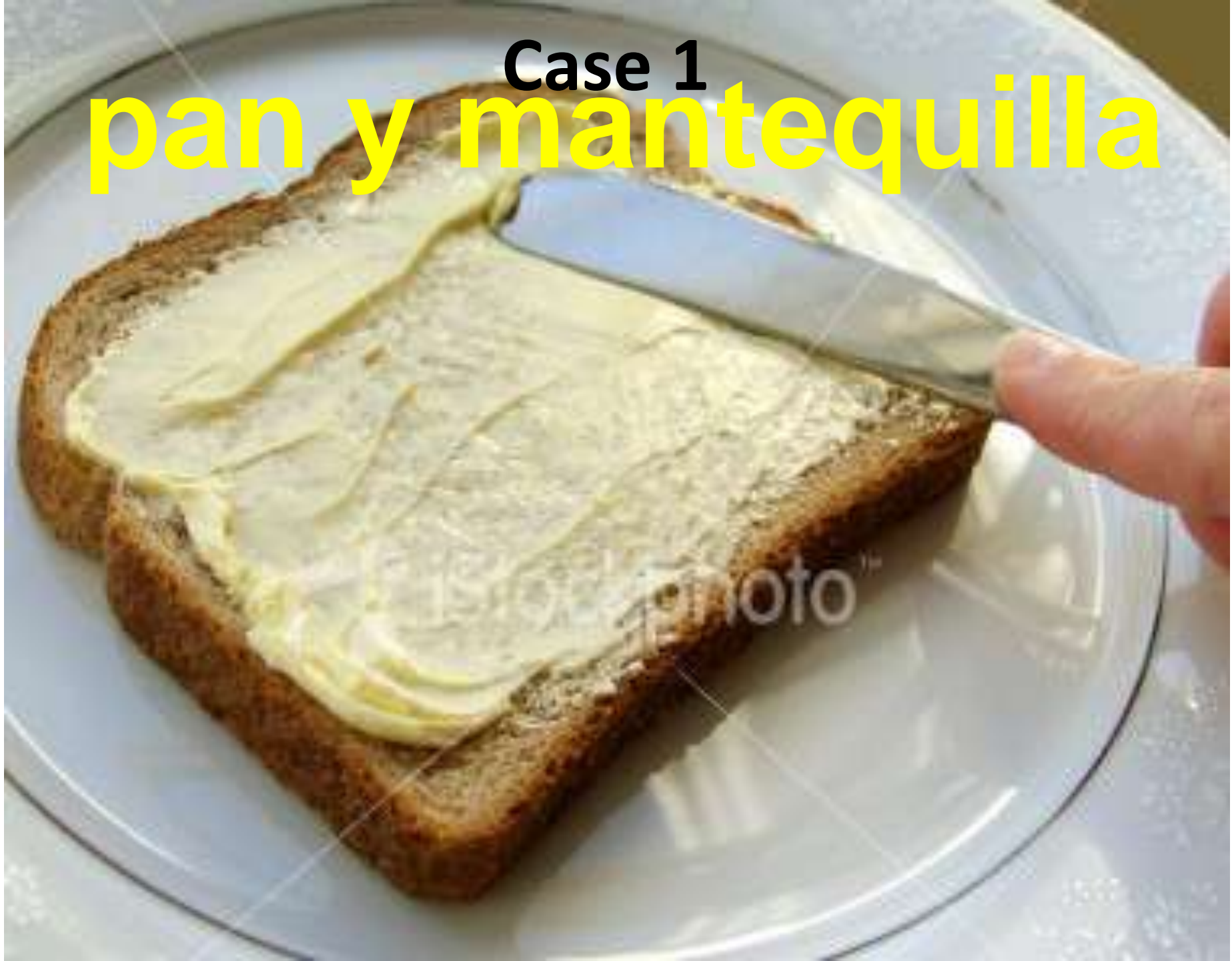Consolidando puentes

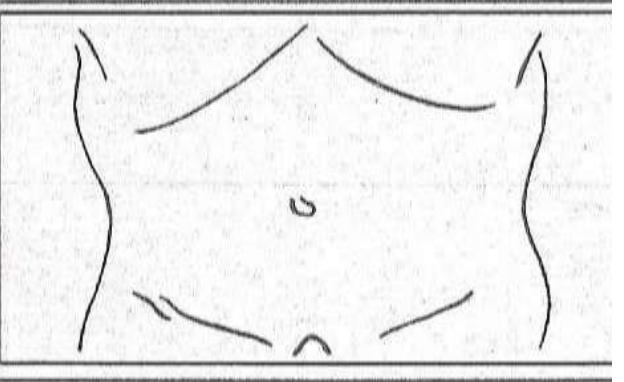
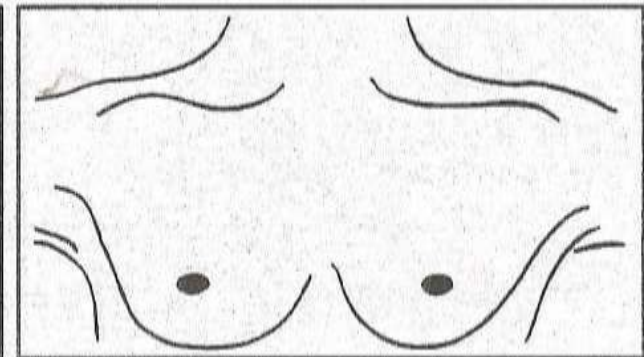
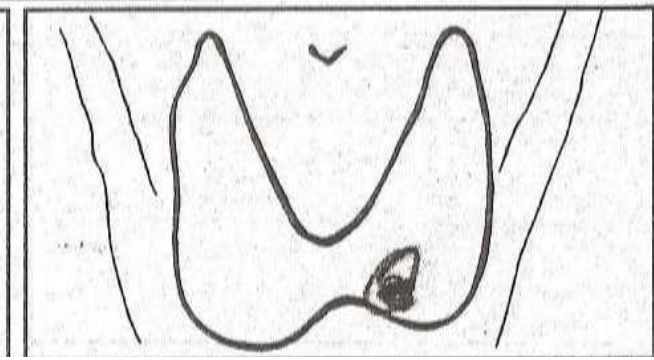
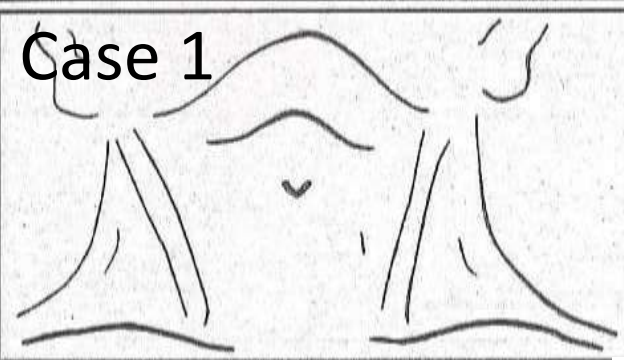
PATOLOGÍA DEL TIROIDES & CO:

DEL PAN CON MANTECA AL CAVIAR (SC)

Case 1

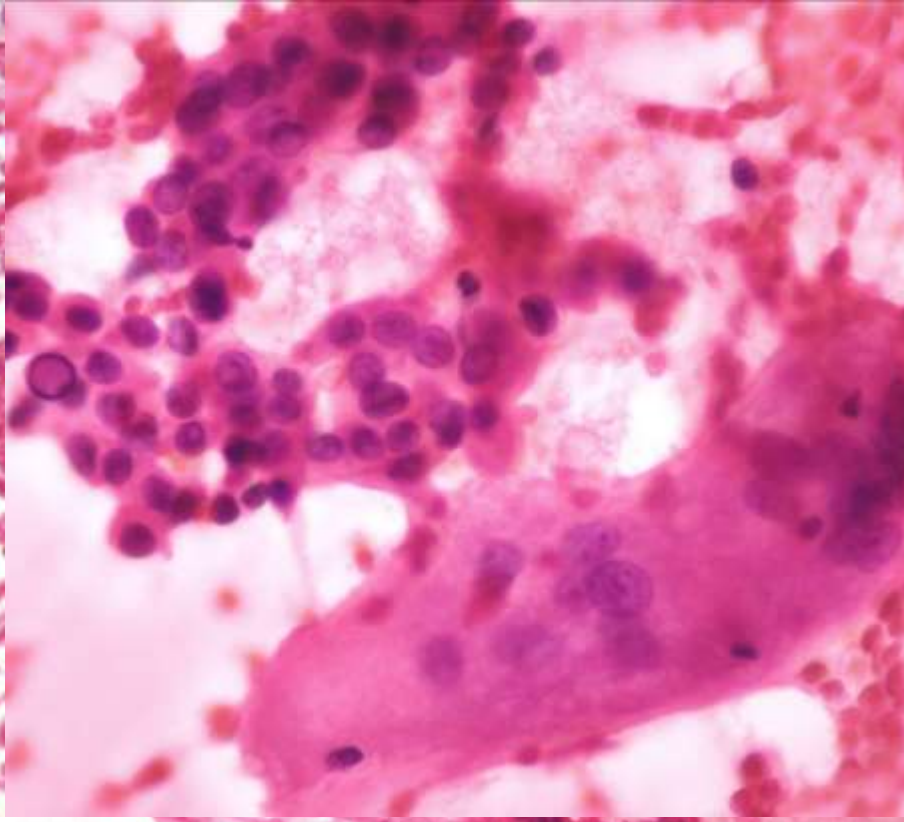
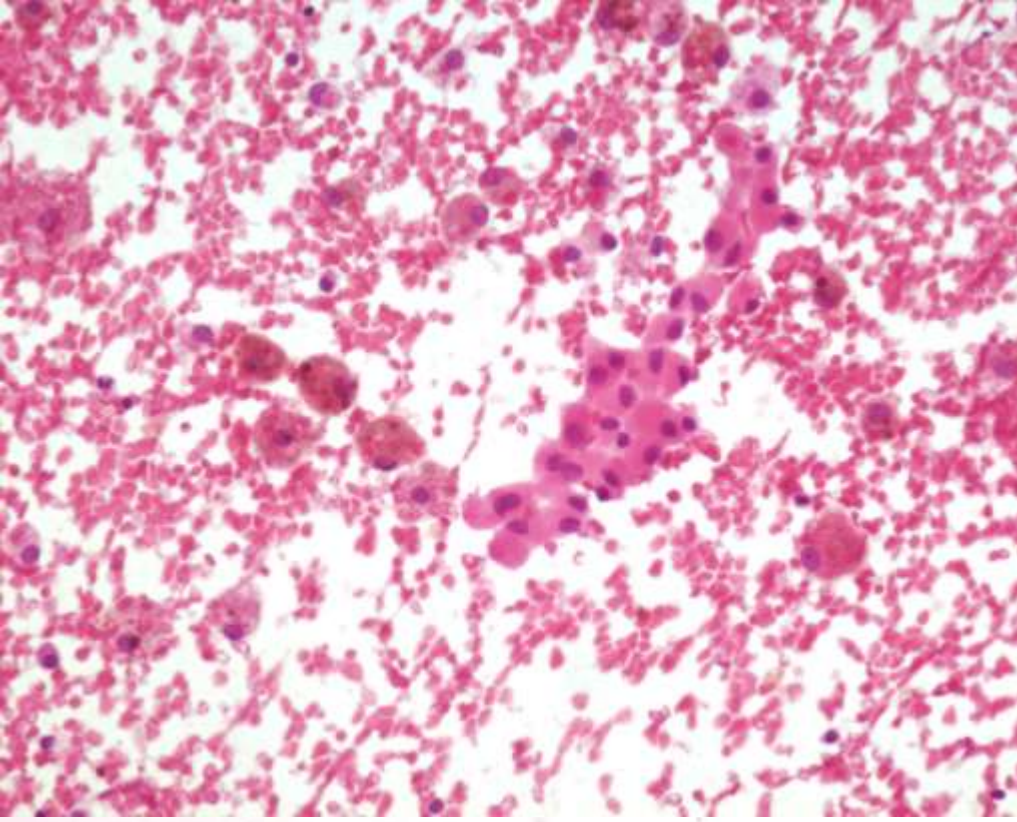
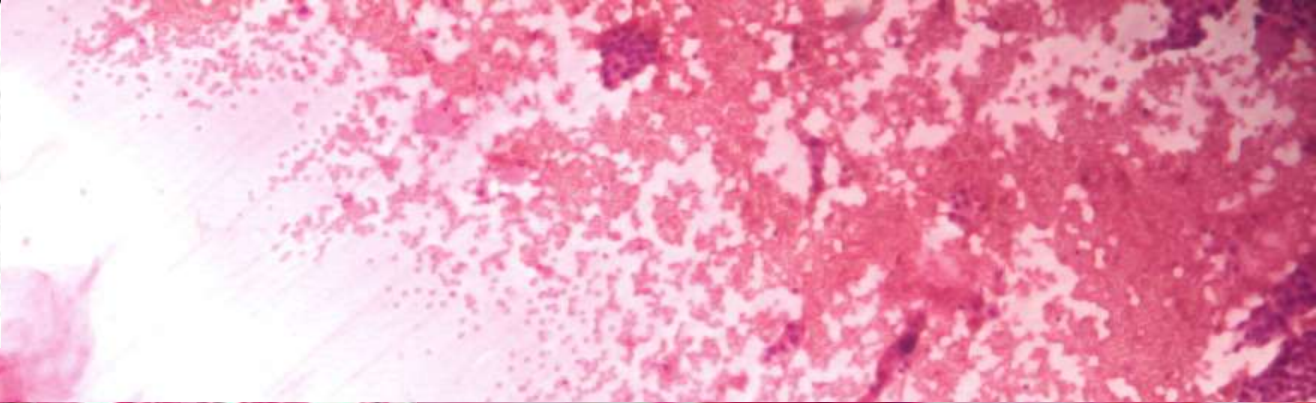
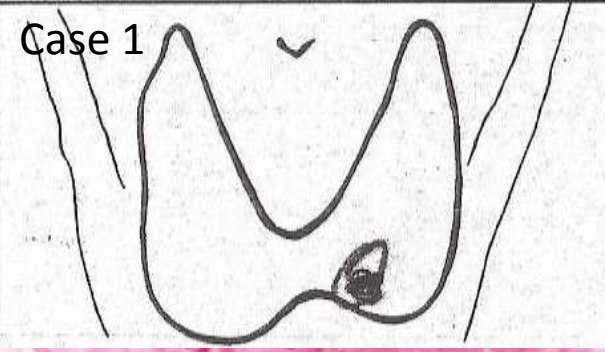
pan y mantequilla

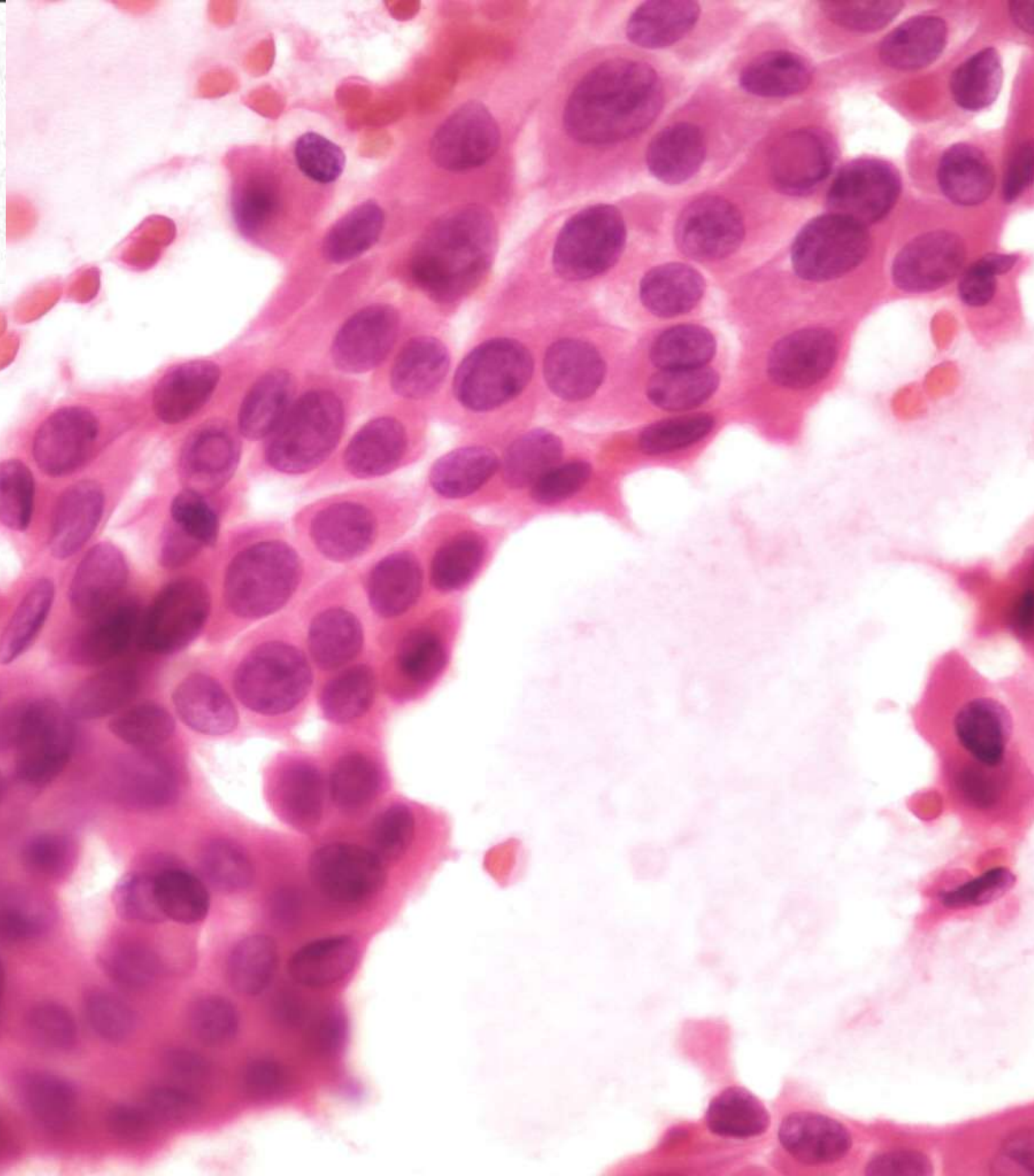
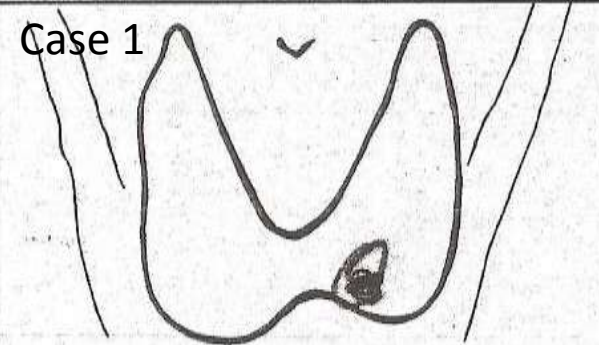


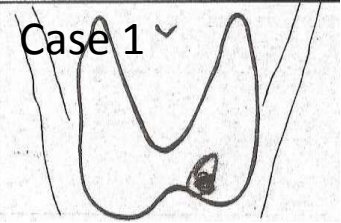


79 year- old female with a nodule of the left lobe.

Fine needle aspiration performed





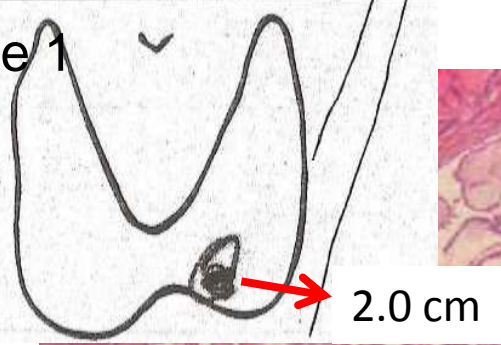


Bethesda

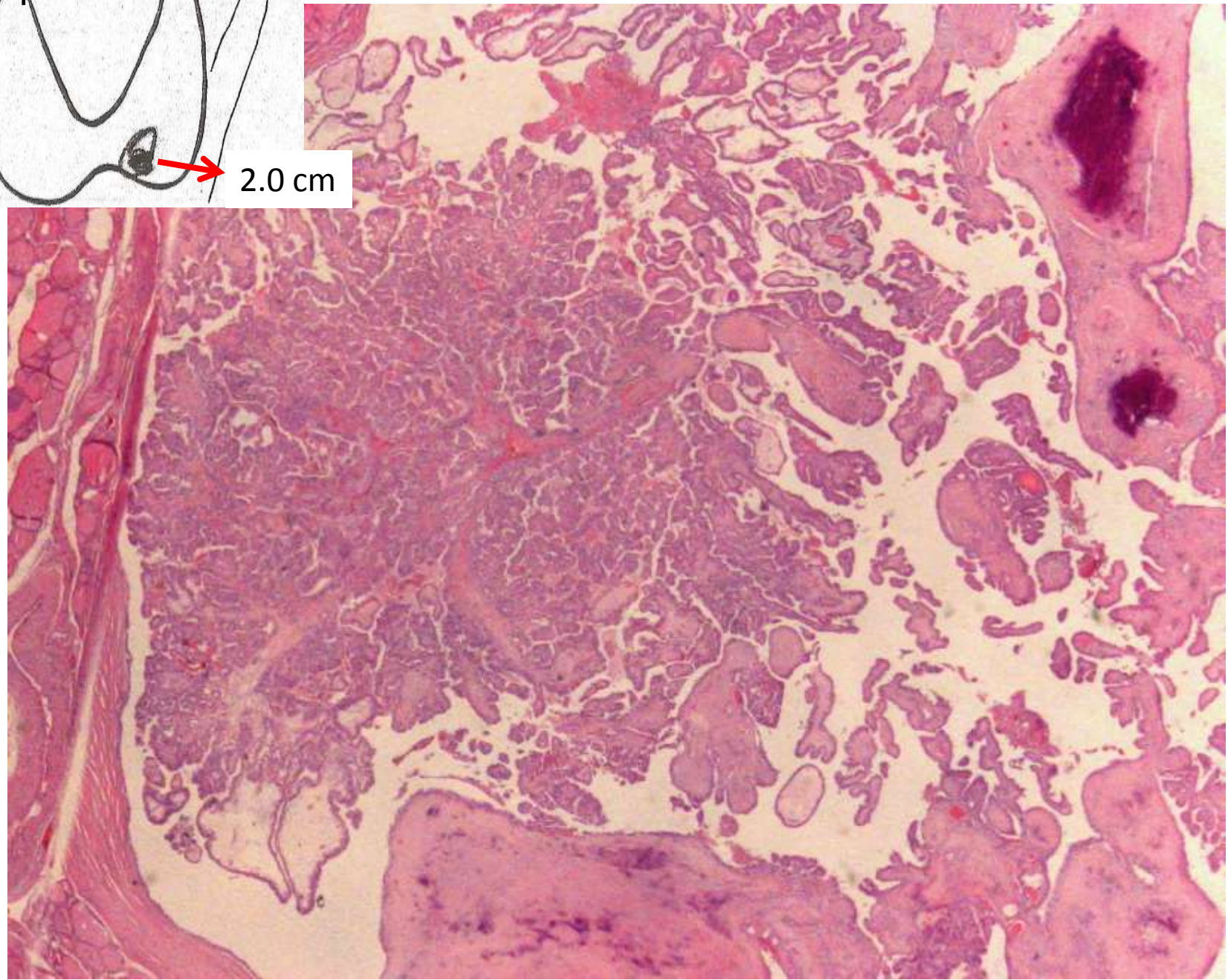
- NONDIAGNOSTIC or UNSATISFACTORY
- BENIGN
- ATYPIA OF UNDETERMINED SIGNIFICANCE or FOLLICULAR LESION OF UNDETERMINED SIGNIFICANCE
- FOLLICULAR NEOPLASM or SUSPICIOUS FOR A FOLLICULAR NEOPLASM
- SUSPICIOUS FOR MALIGNANCY
- MALIGNANT

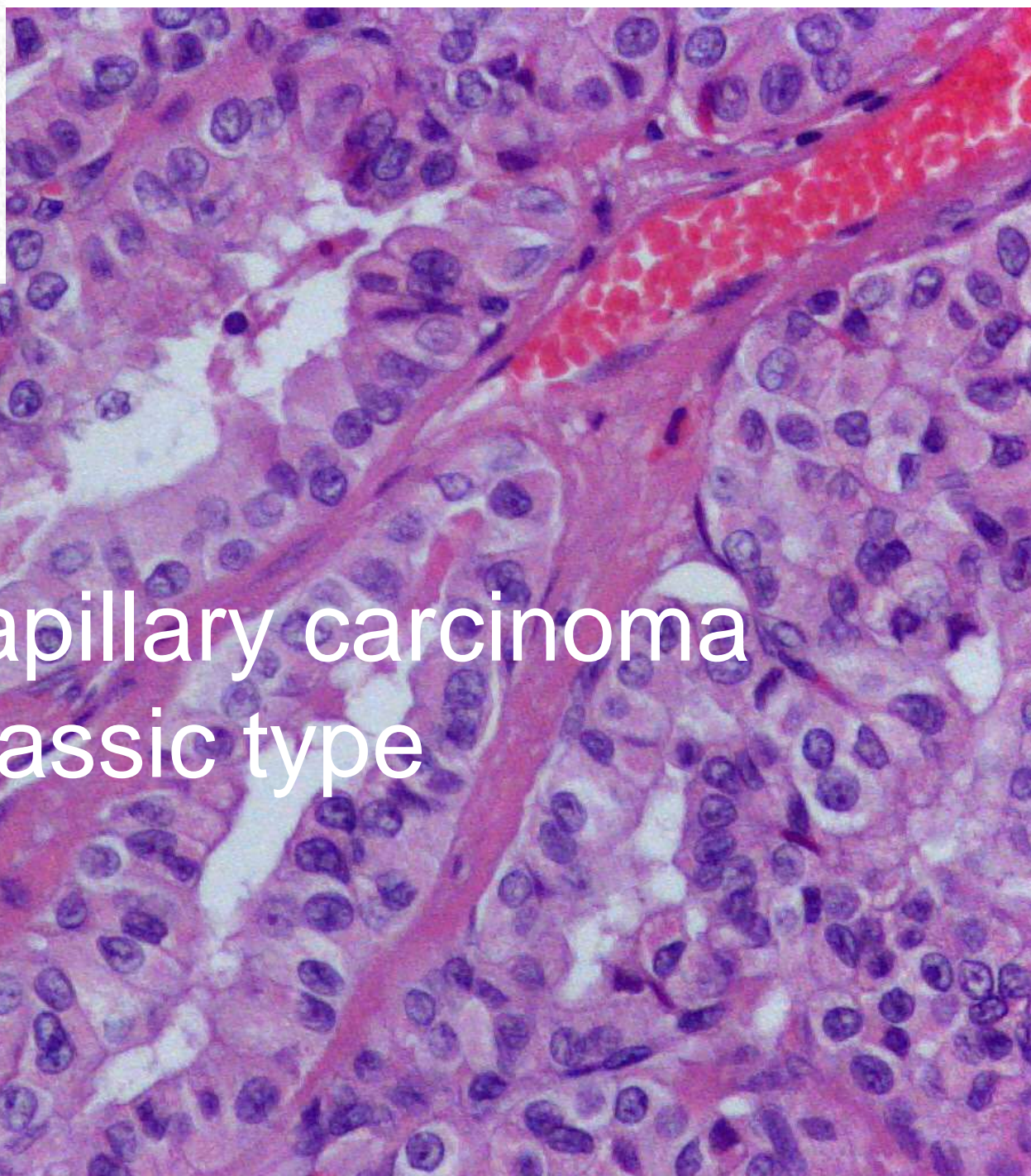
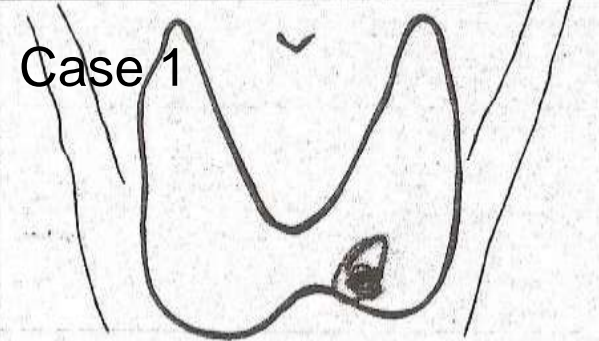
Papillary carcinoma

Case 1



Total thyroidectomy - 23 g





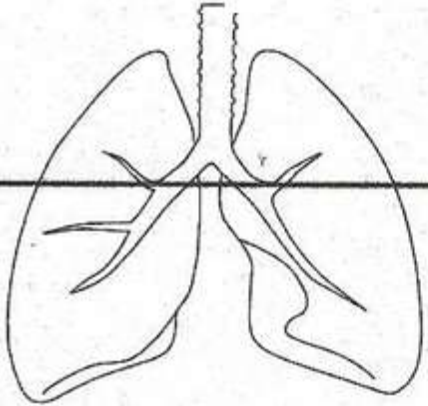
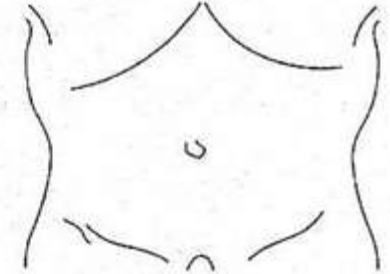
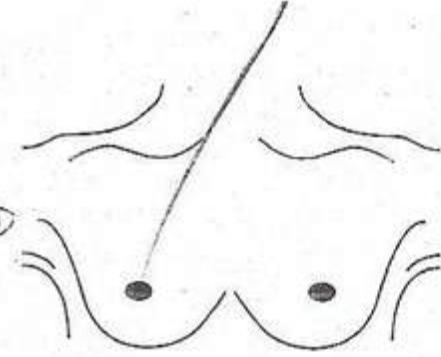

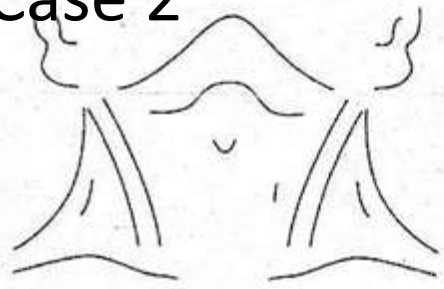
Total thyroidectomy - 23 g

Papillary carcinoma
Classic type

Case 2



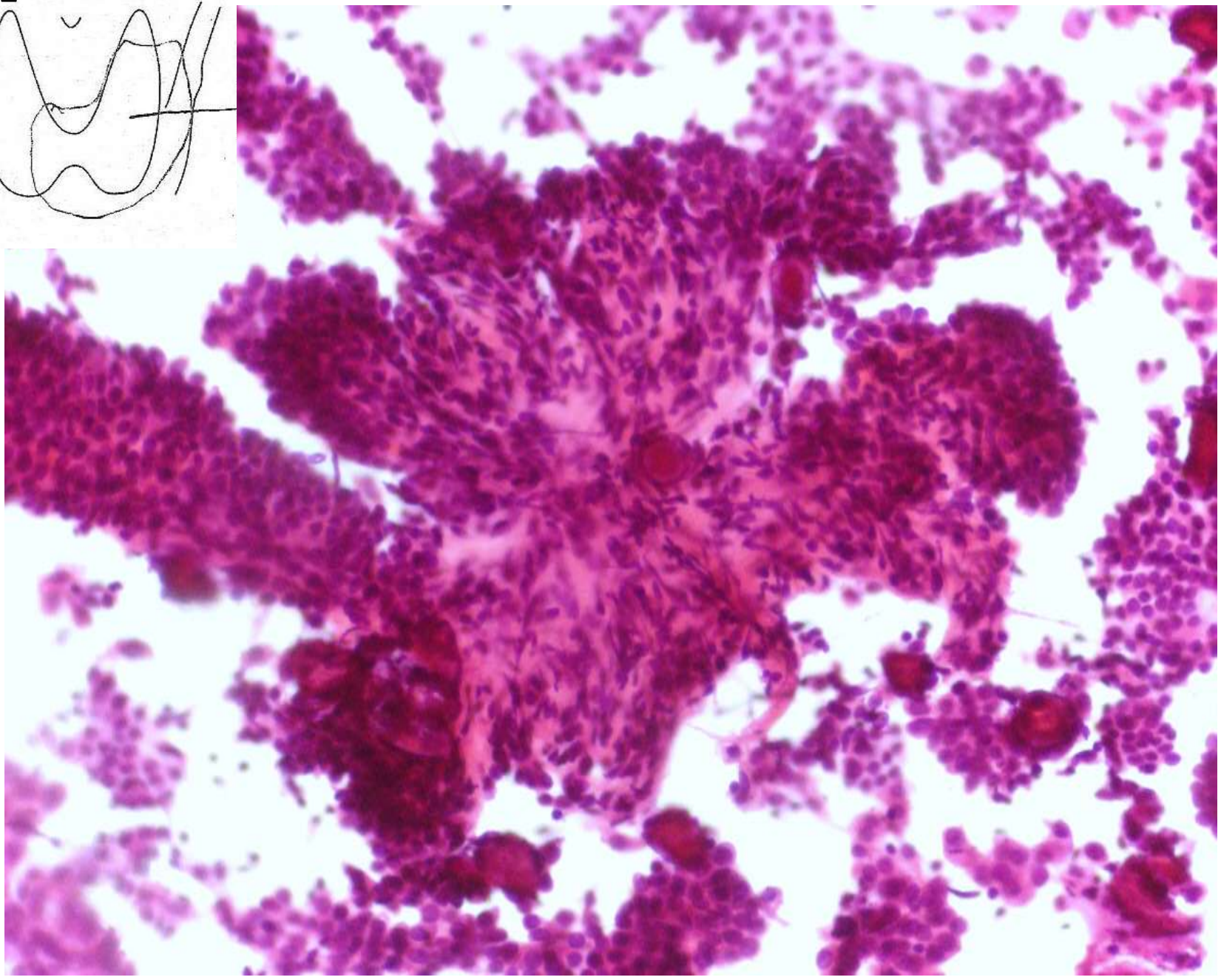

Case 2



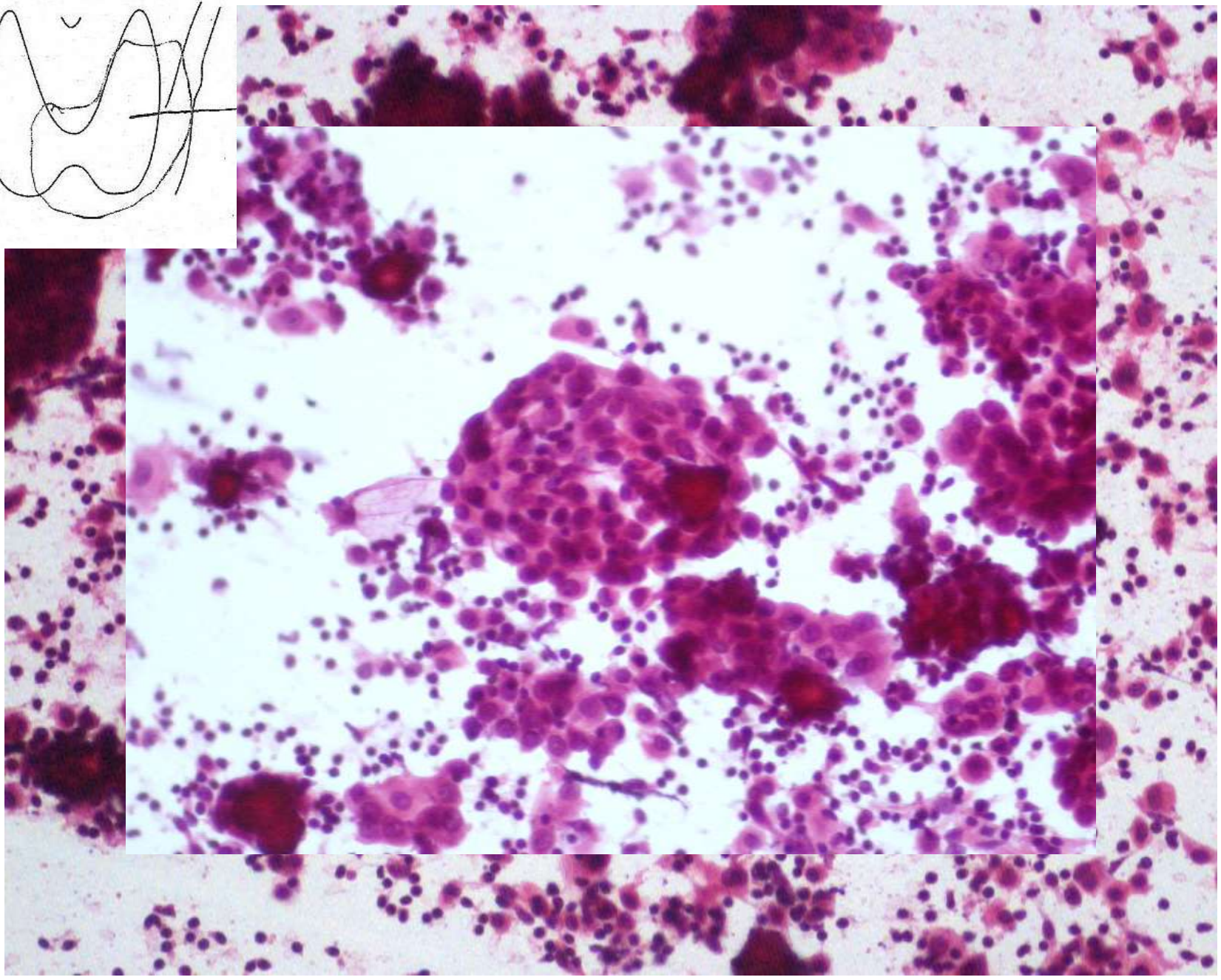

28 year-old male with a 40 mm nodule of the left lobe.

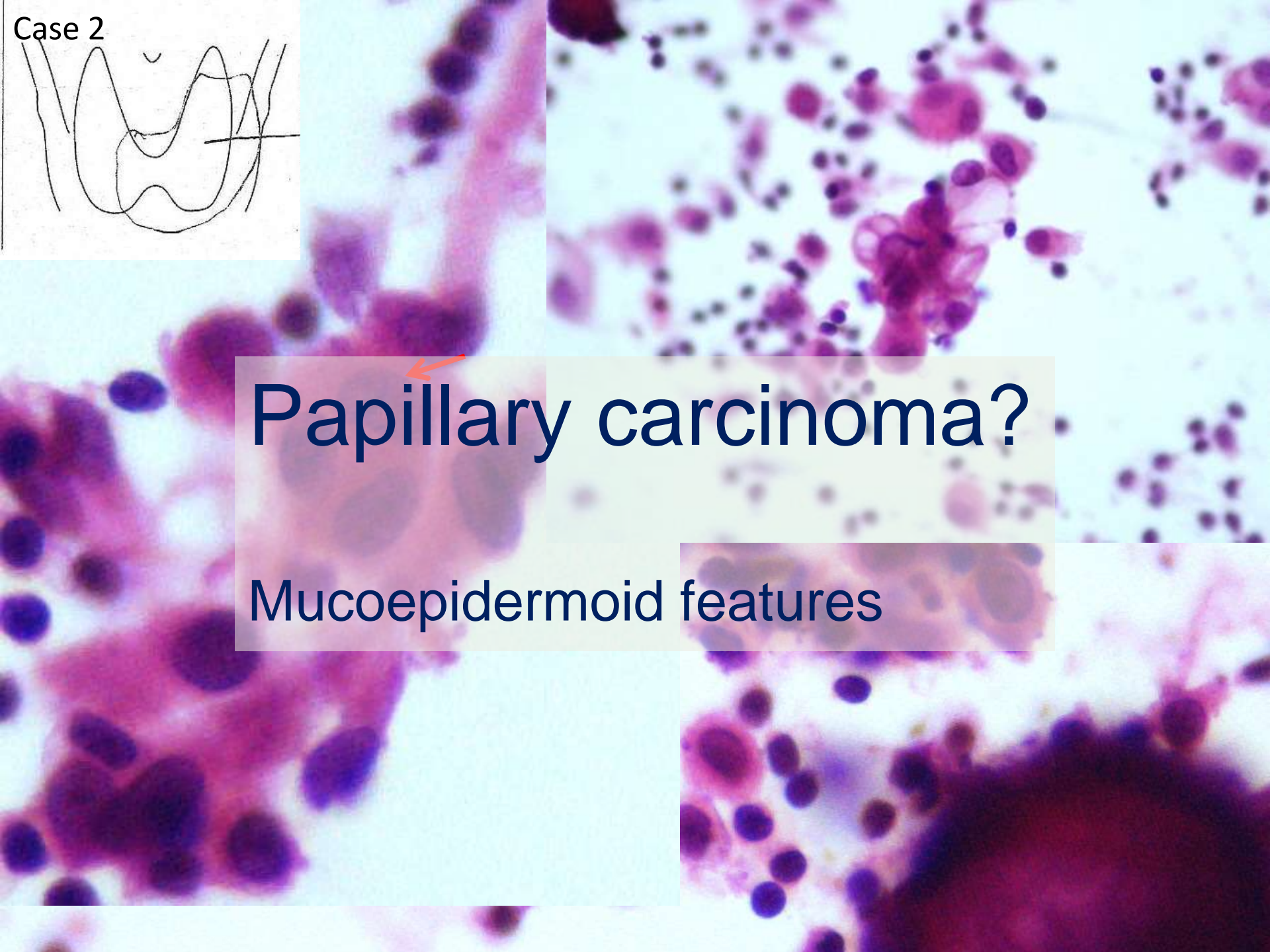

Fine needle aspiration performed

Case 2




Case 2





Papillary carcinoma?
Mucoepidermoid features

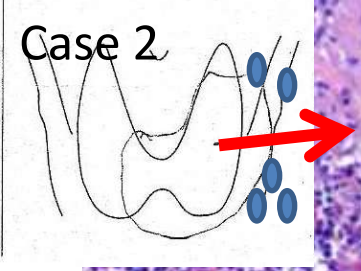


Bethesda

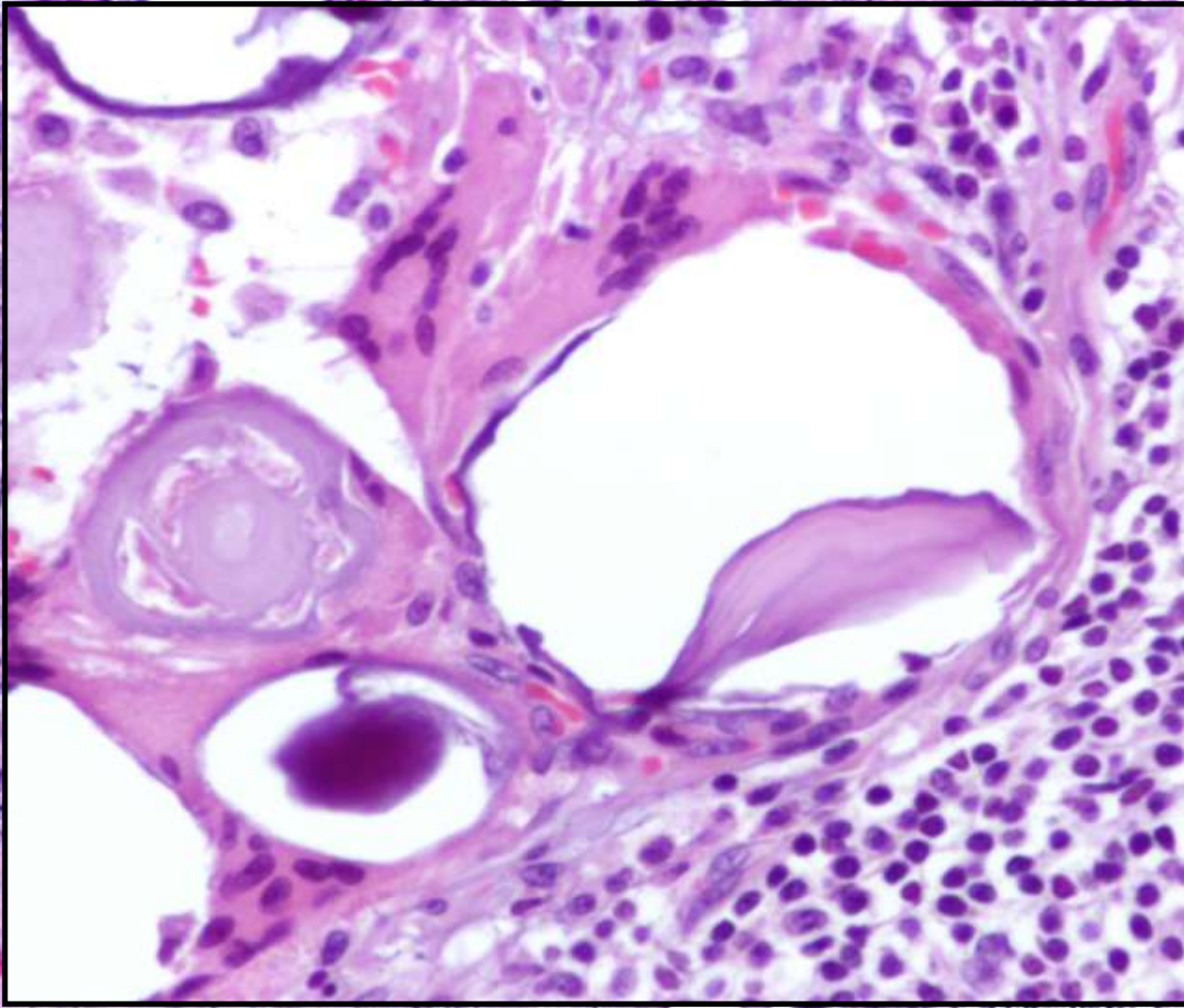
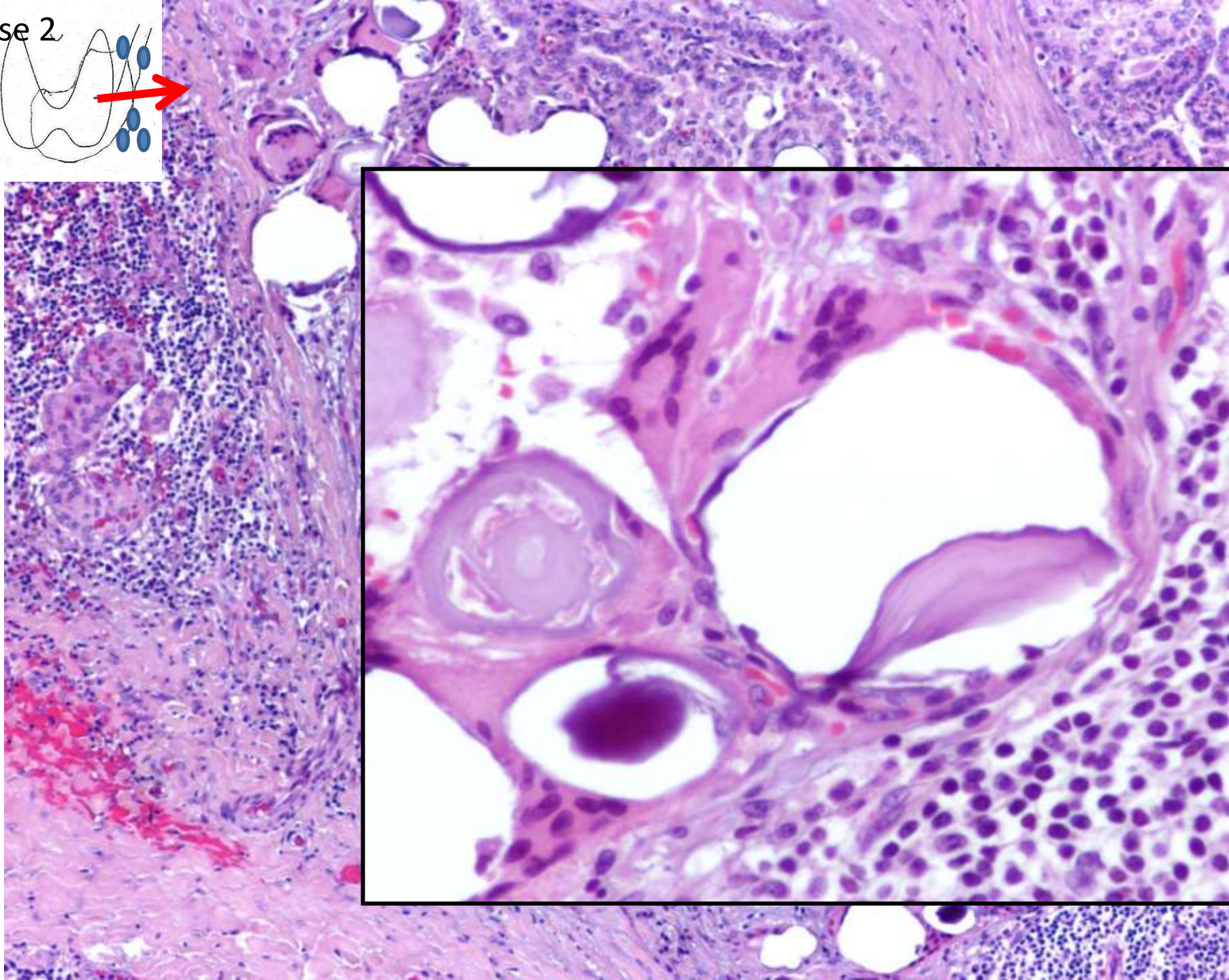
- NONDIAGNOSTIC or UNSATISFACTORY
- BENIGN
- ATYPIA OF UNDETERMINED SIGNIFICANCE or FOLLICULAR LESION OF UNDETERMINED SIGNIFICANCE
- FOLLICULAR NEOPLASM or SUSPICIOUS FOR A FOLLICULAR NEOPLASM
- SUSPICIOUS FOR MALIGNANCY
- MALIGNANT

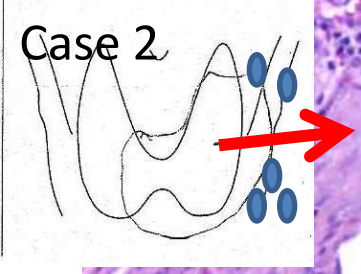
Papillary carcinoma

Diffuse sclerosing variant?

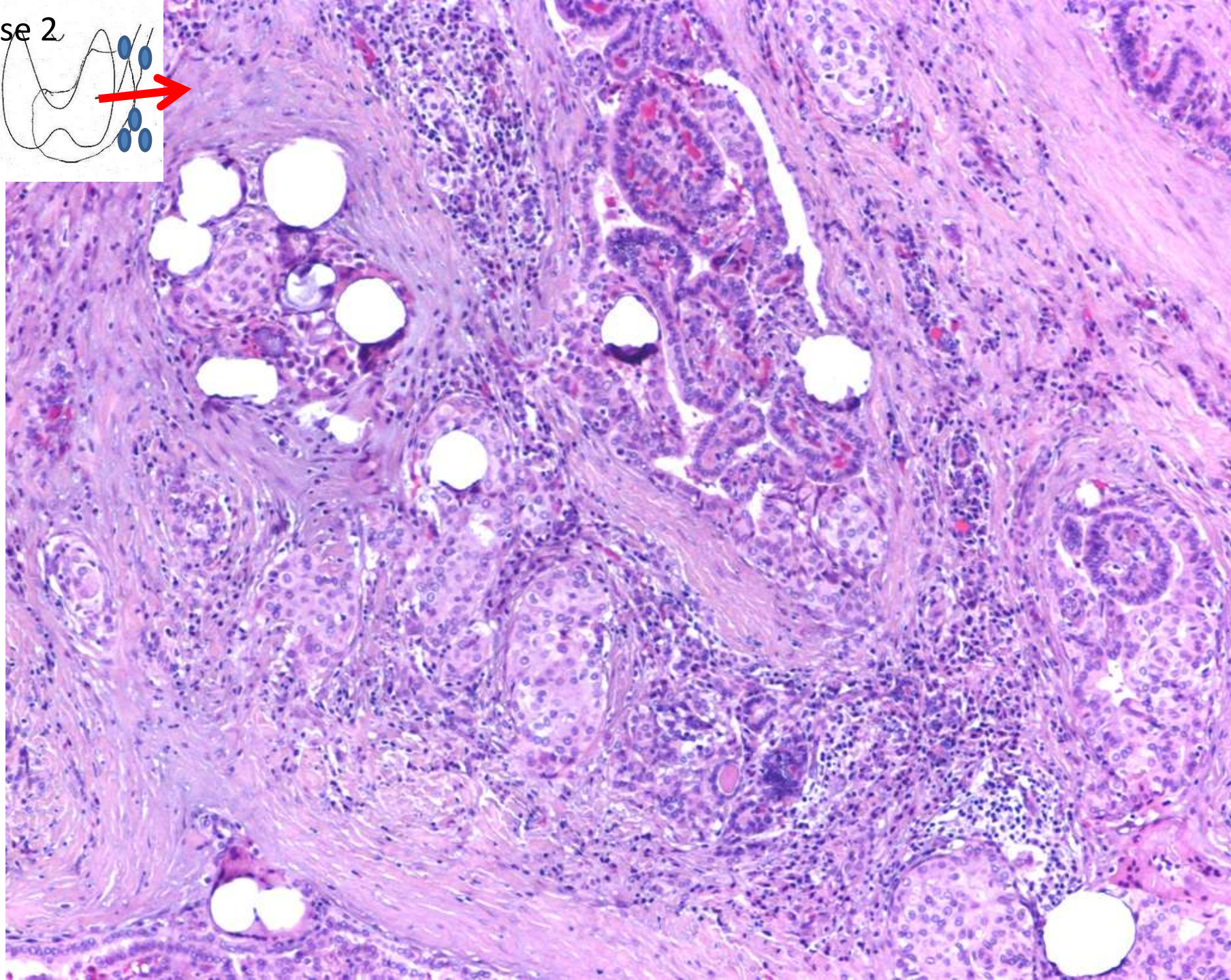


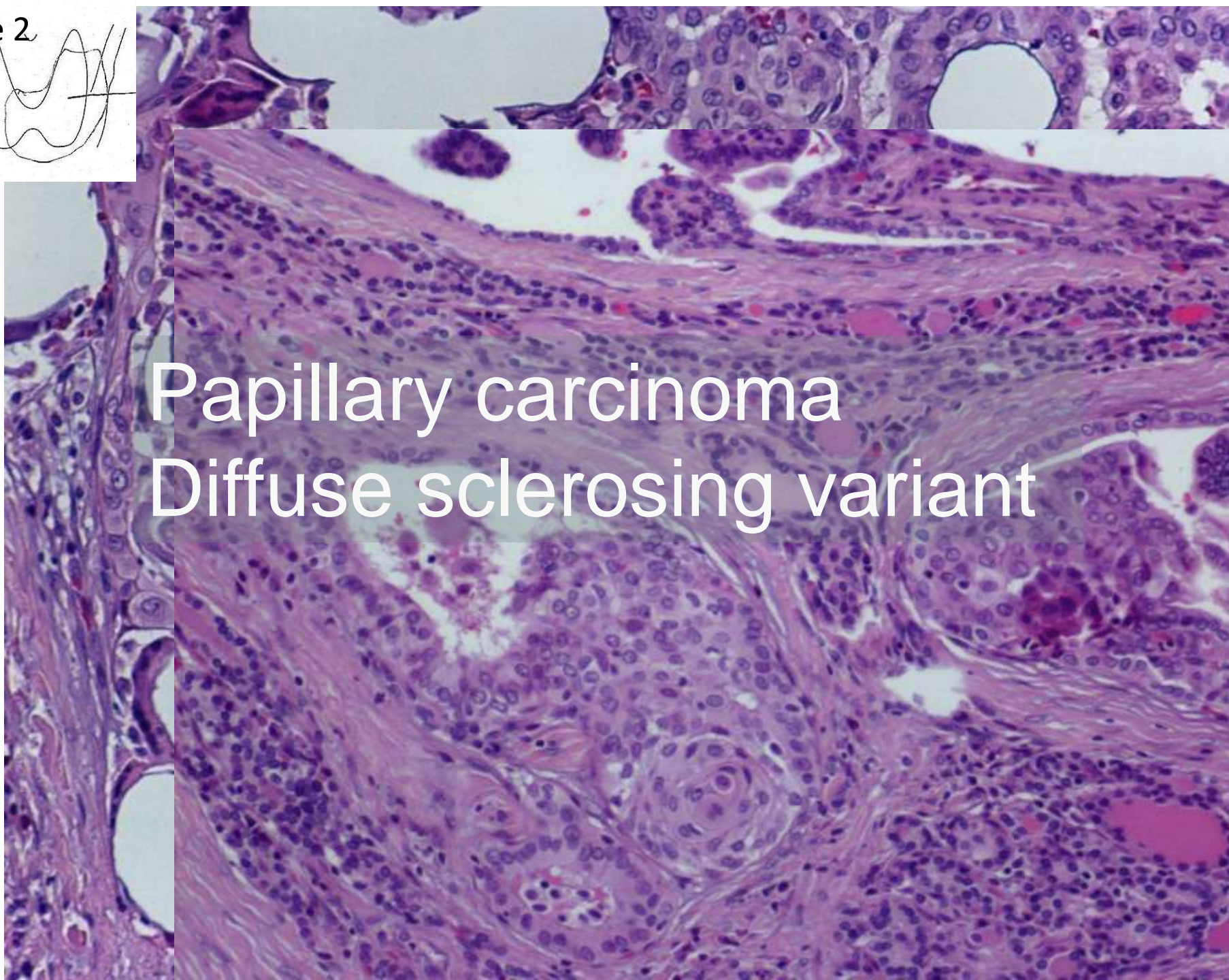

Total thyroidectomy - 30 g





Total thyroidectomy





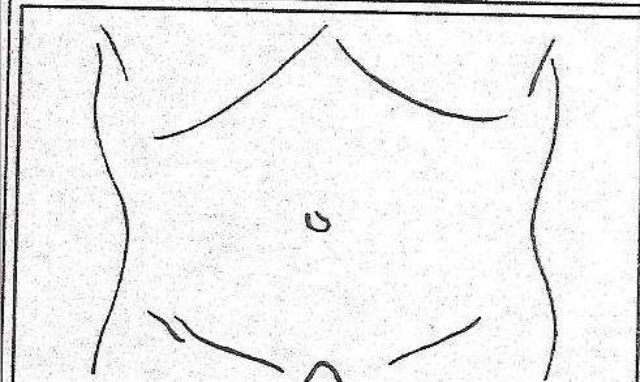
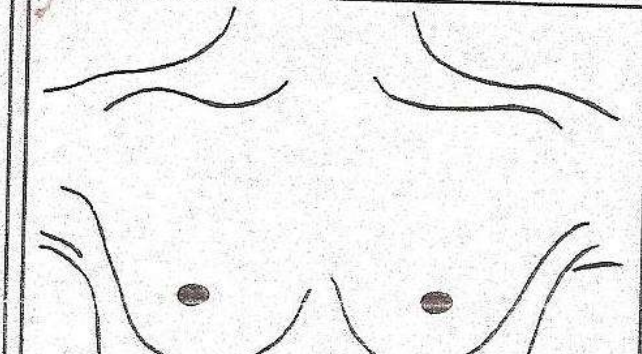
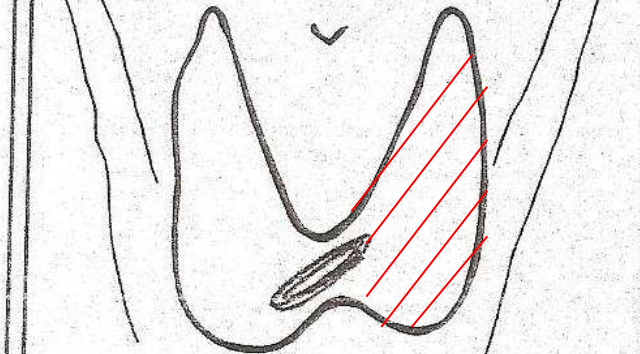
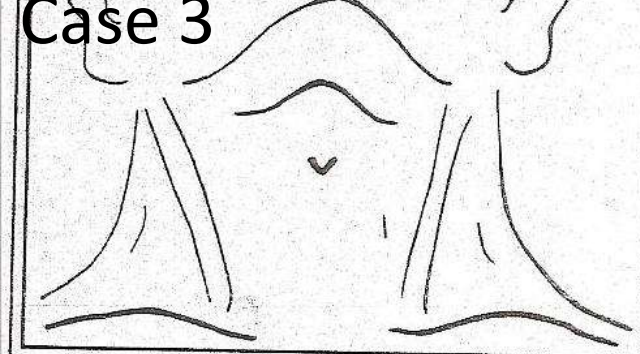
Papillary carcinoma
Diffuse sclerosing variant

Case 3

Pan y Mantequilla y Caviar

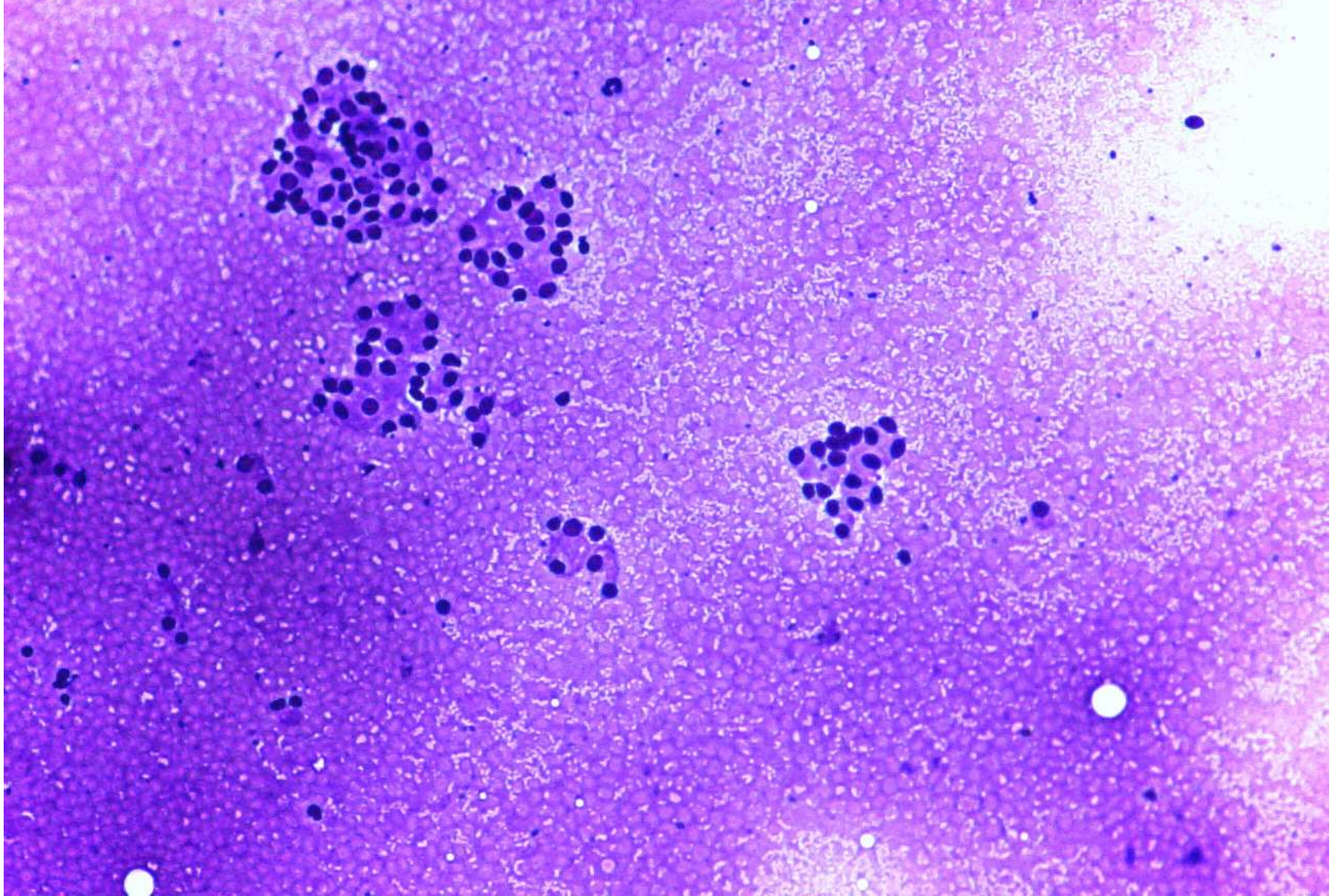
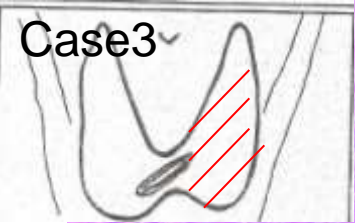


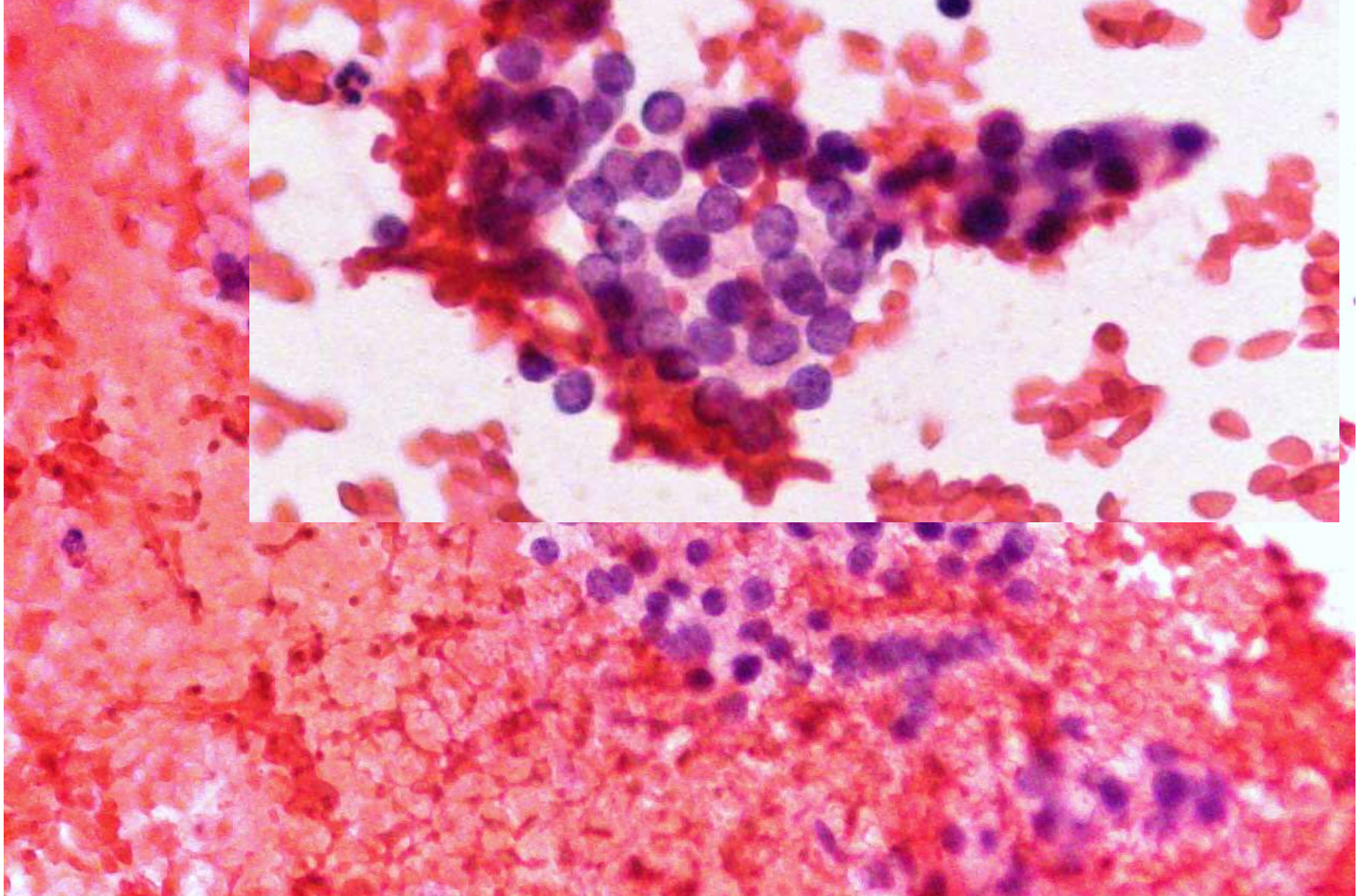
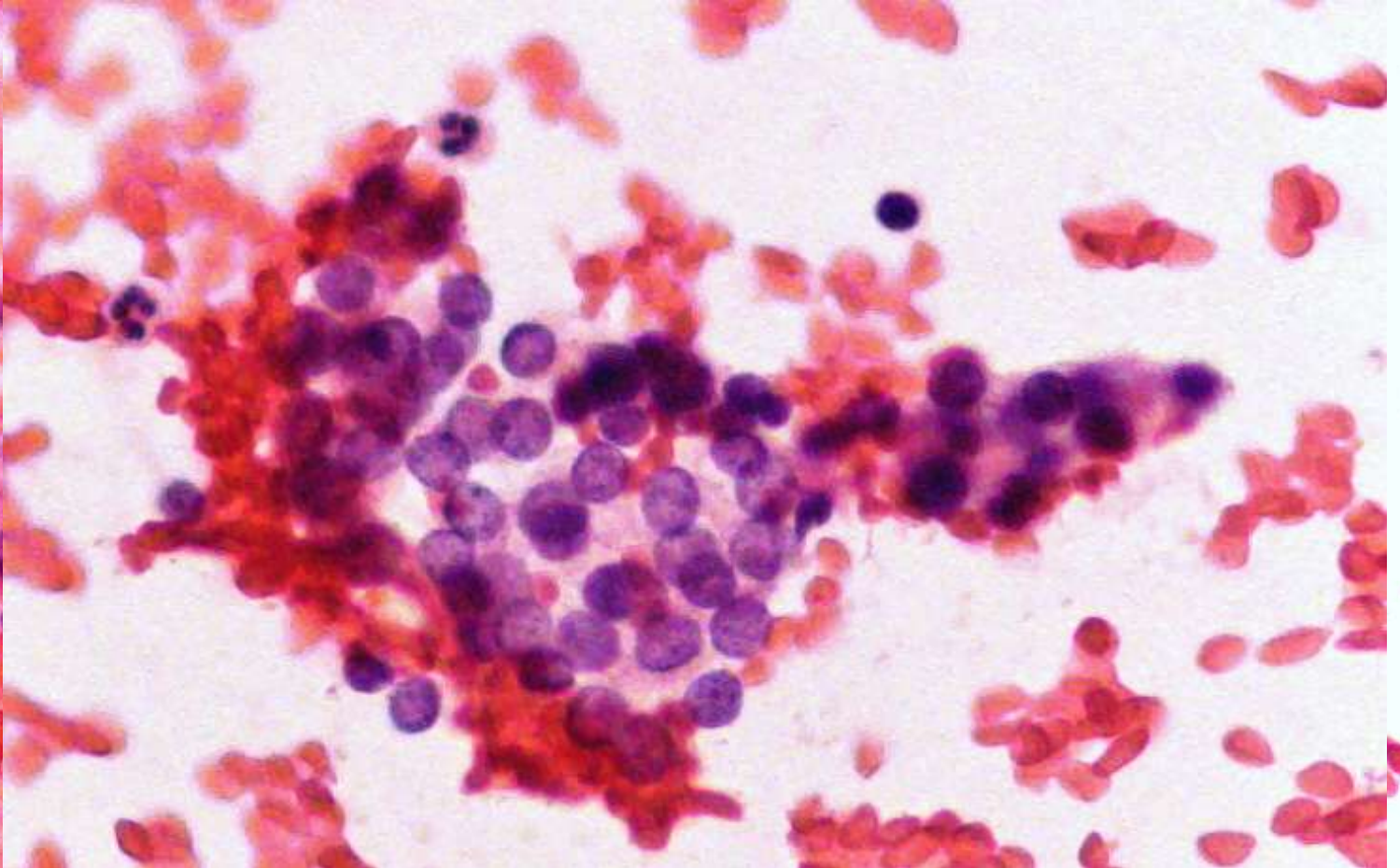
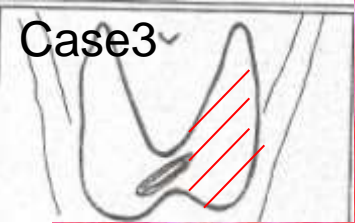
Case 3

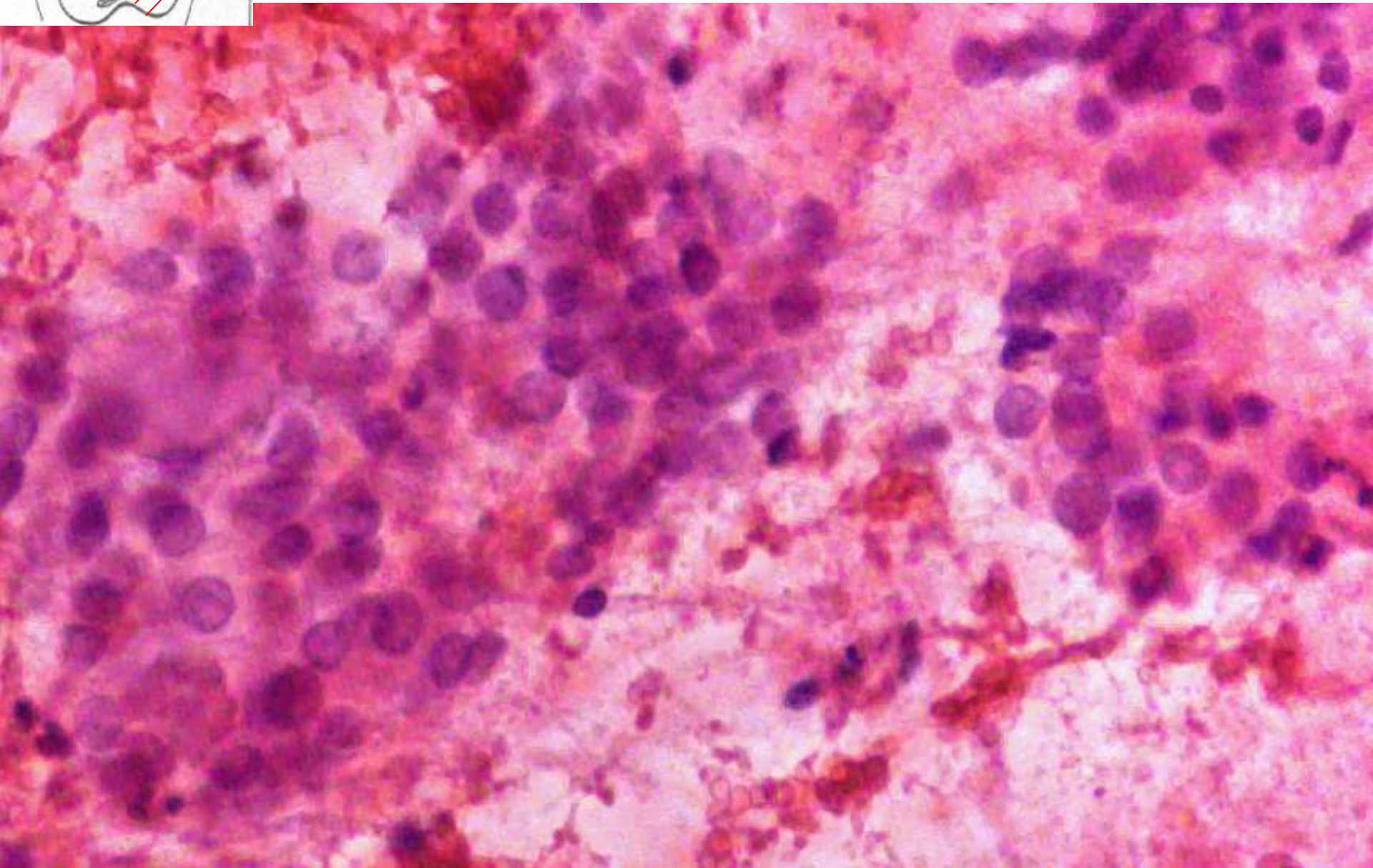
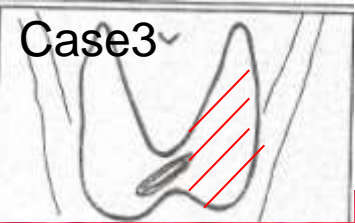


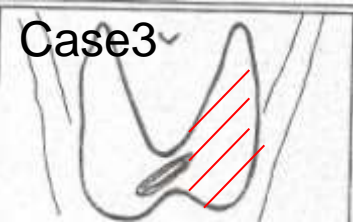
50 year- old male with a 9 mm nodule of the right lobe.

Previous left lobectomy for follicular carcinoma
Fine needle aspiration performed





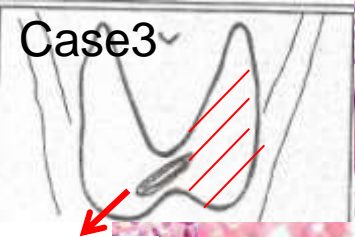




Bethesda

- NONDIAGNOSTIC or UNSATISFACTORY
- BENIGN
- ATYPIA OF UNDETERMINED SIGNIFICANCE or FOLLICULAR LESION OF UNDETERMINED SIGNIFICANCE
- FOLLICULAR NEOPLASM or SUSPICIOUS FOR FOLLICULAR NEOPLASM
- SUSPICIOUS FOR MALIGNANCY
- MALIGNANT

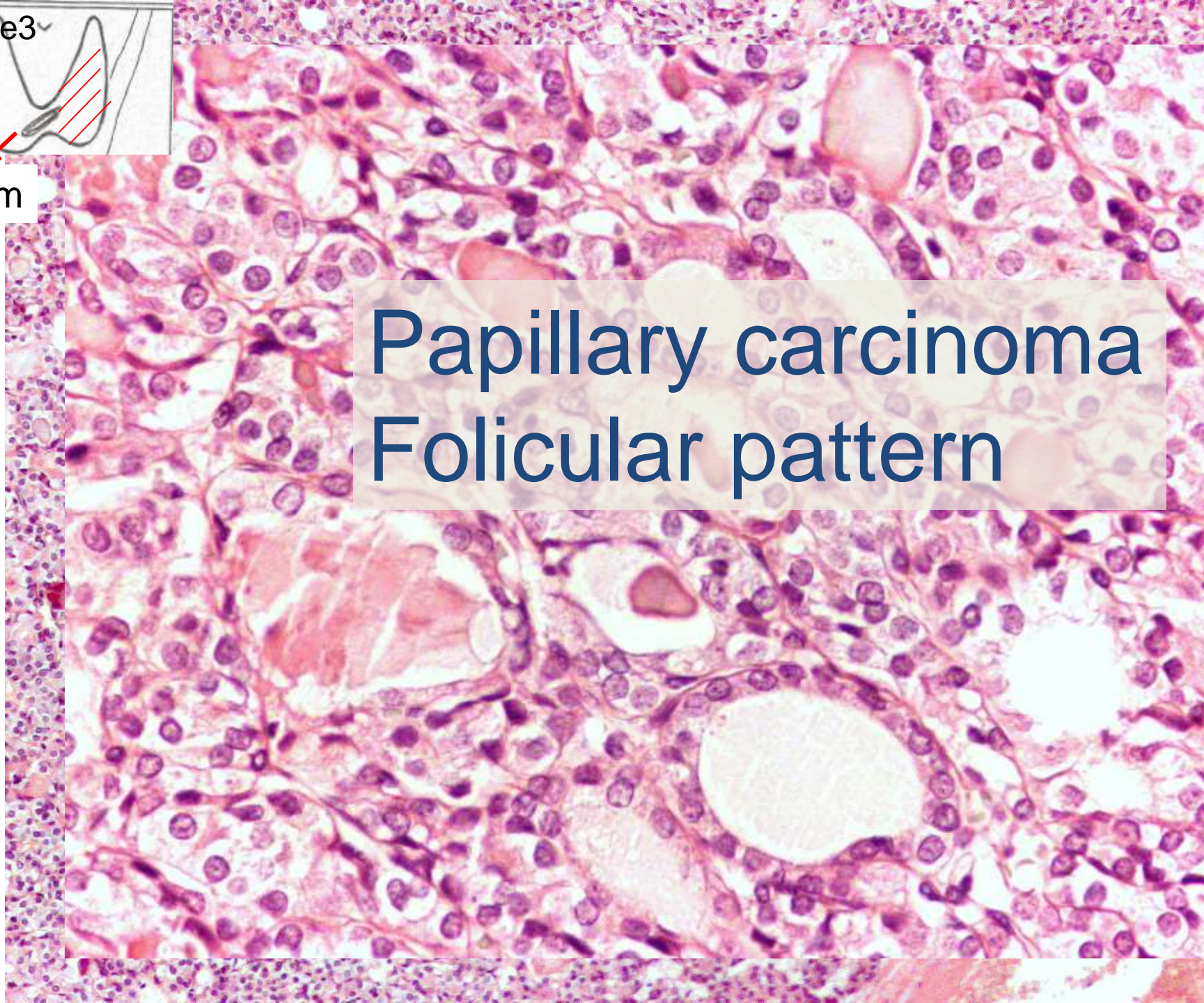
Follicular
variant of
Papillary
carcinoma
?



9mm

Right Lobectomy - 11 g

Papillary carcinoma
Follicular pattern

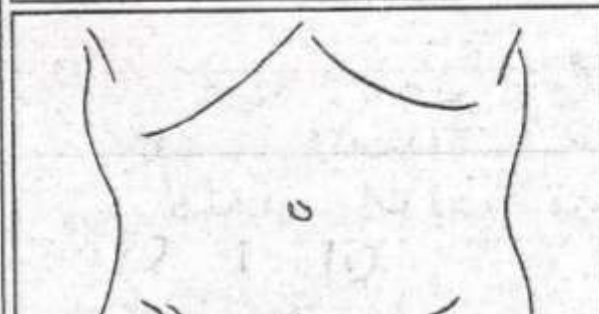
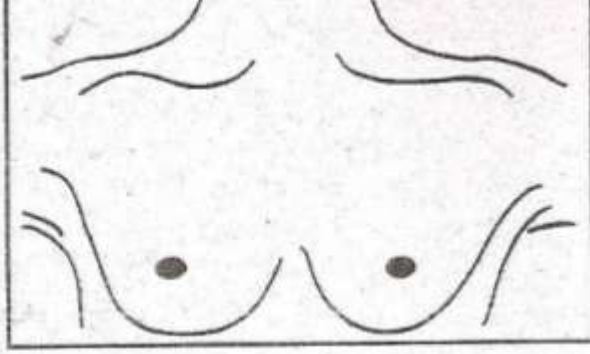
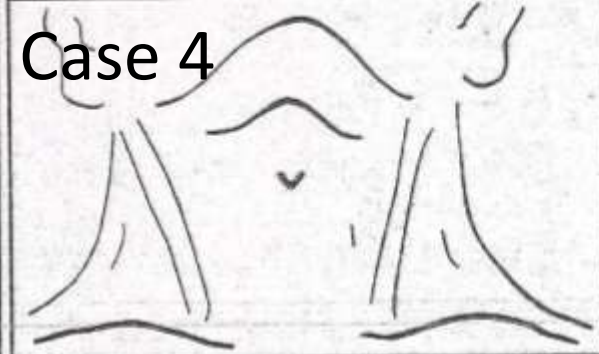



Case 4

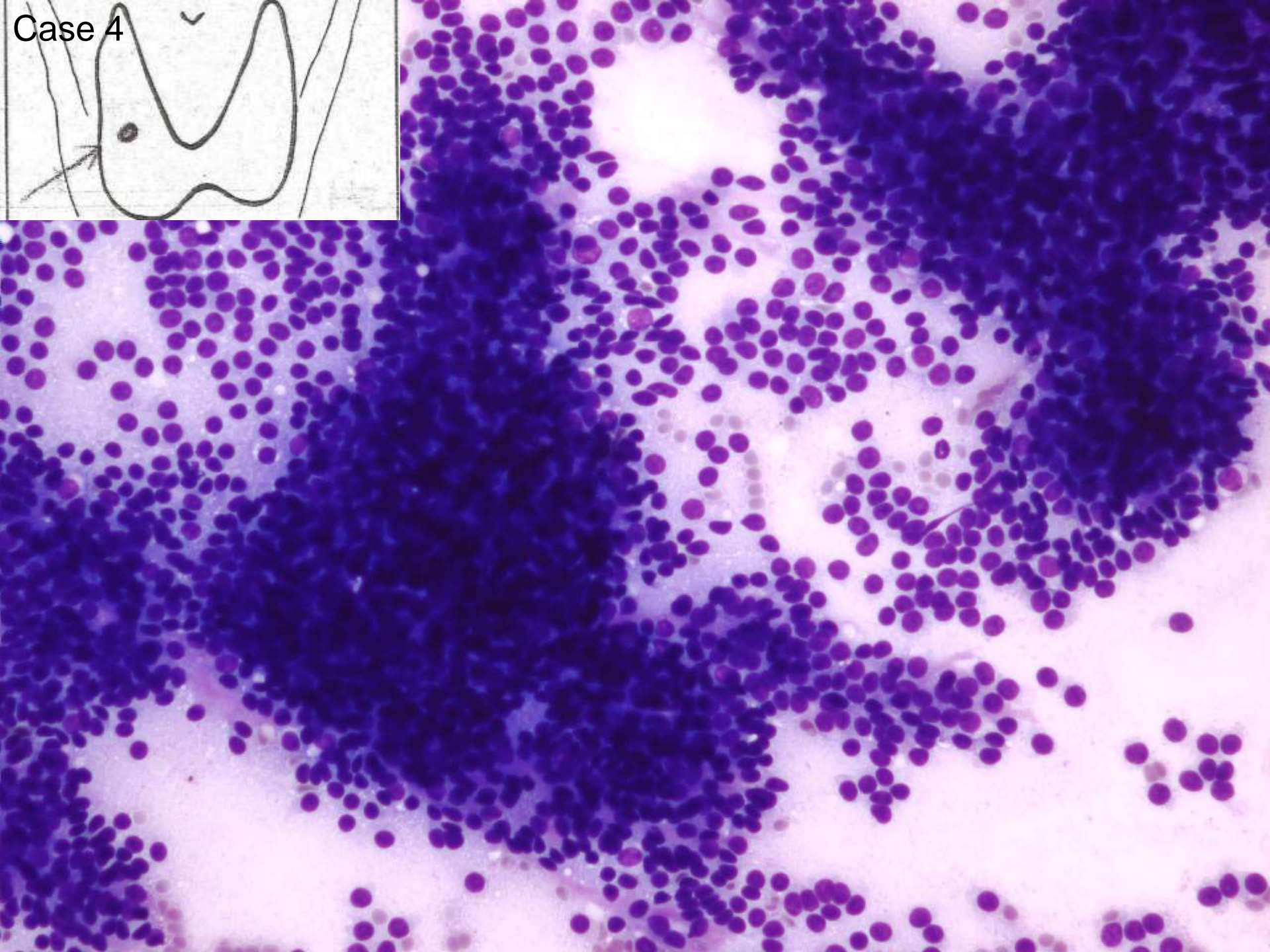

Caviar

Case 4

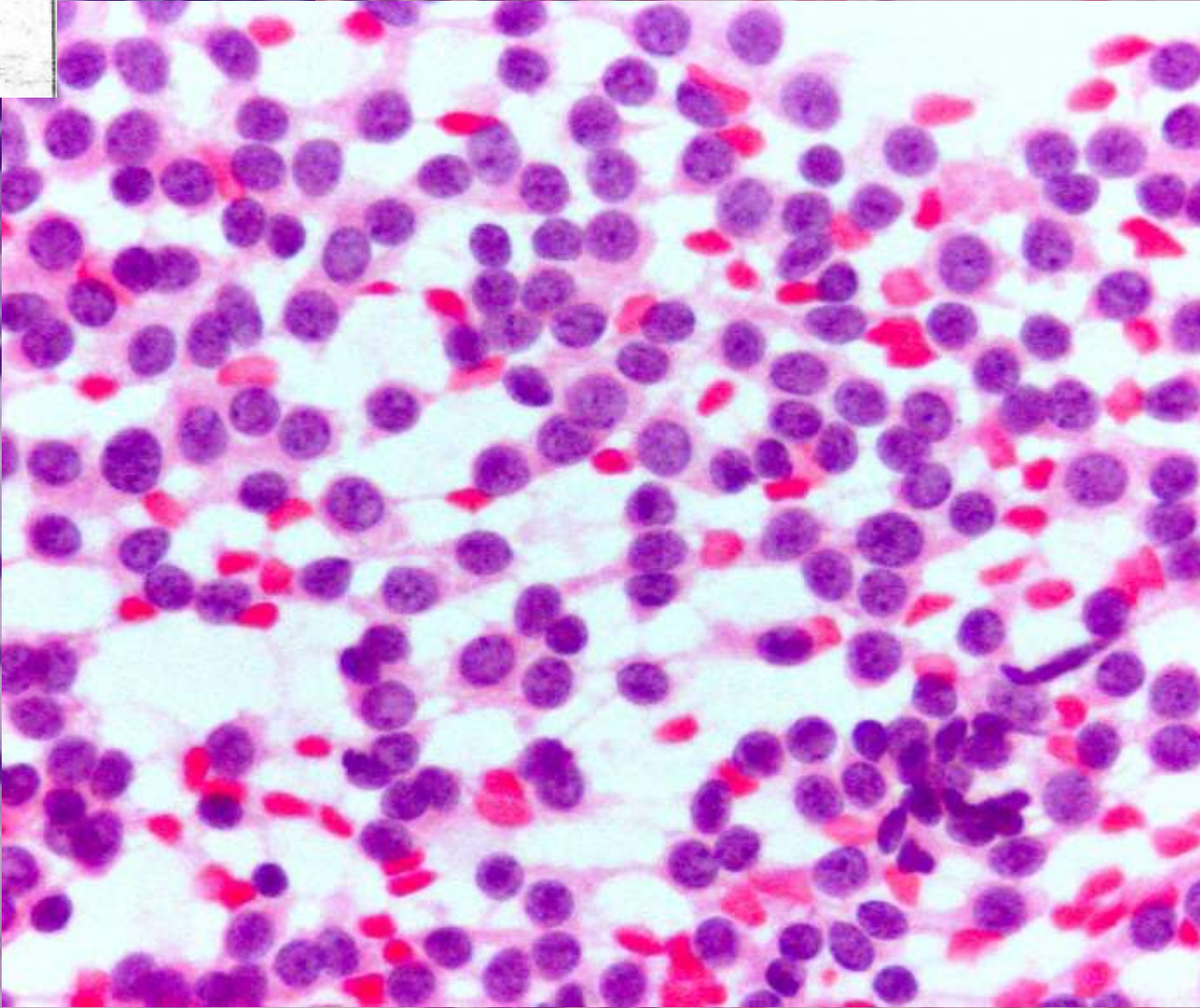
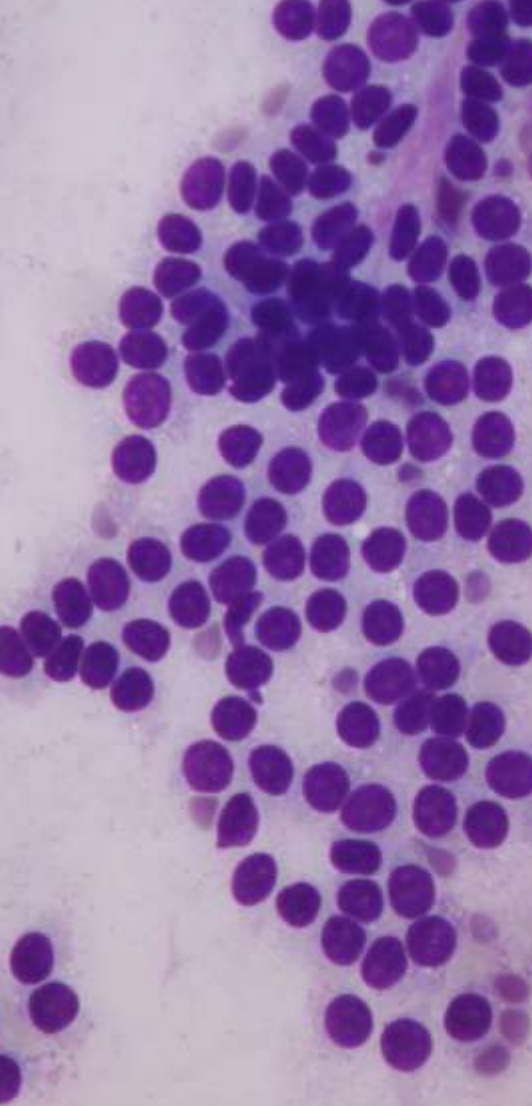
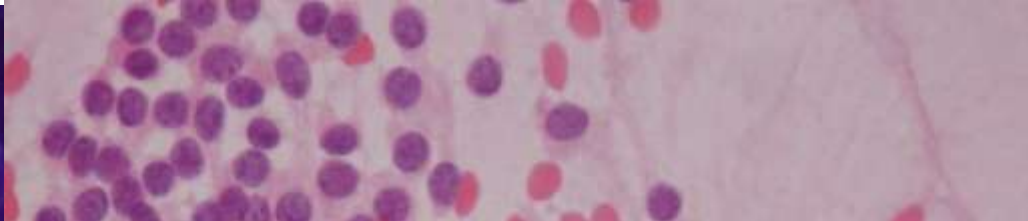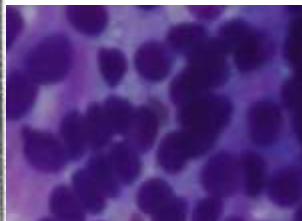



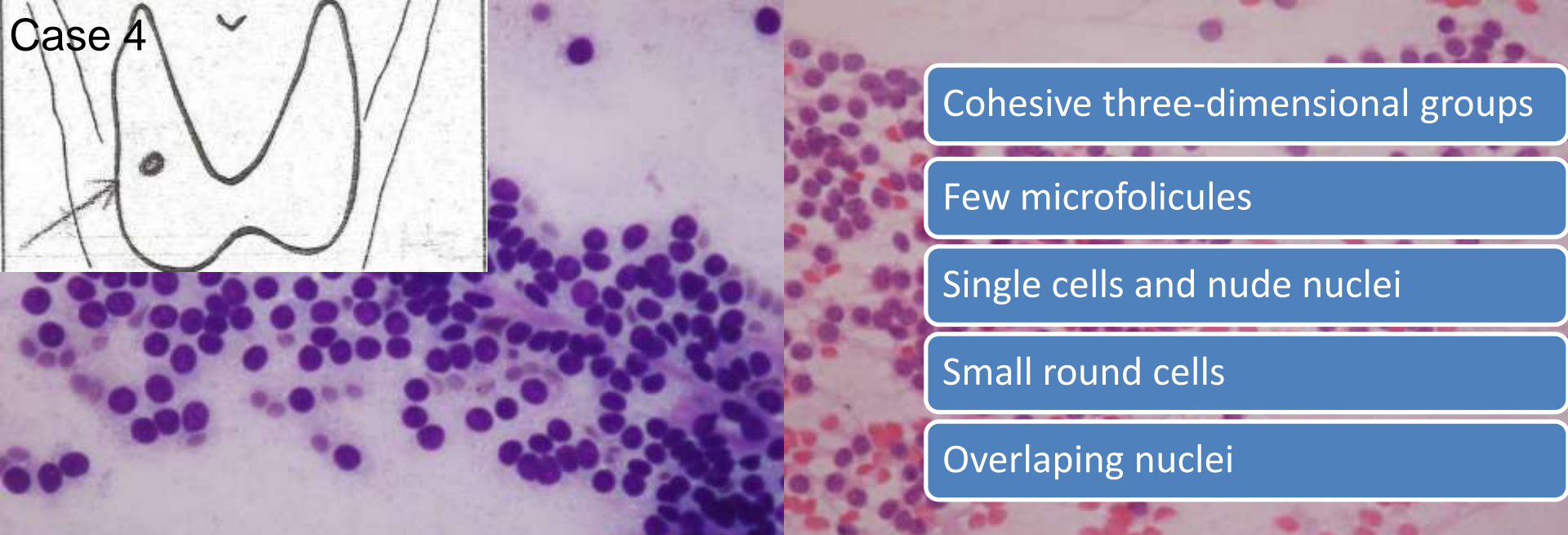
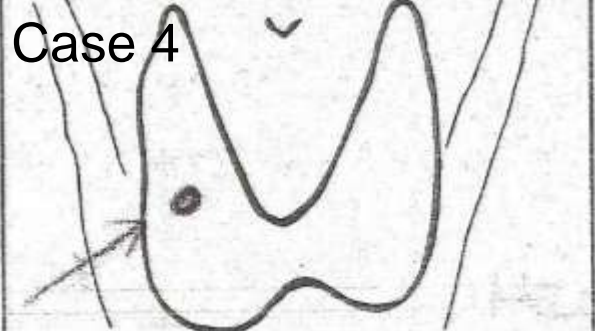
30 year- old female with a 16mm nodule of the right lobe.

Fine needle aspiration performed



Case 4





Cohesive three-dimensional groups

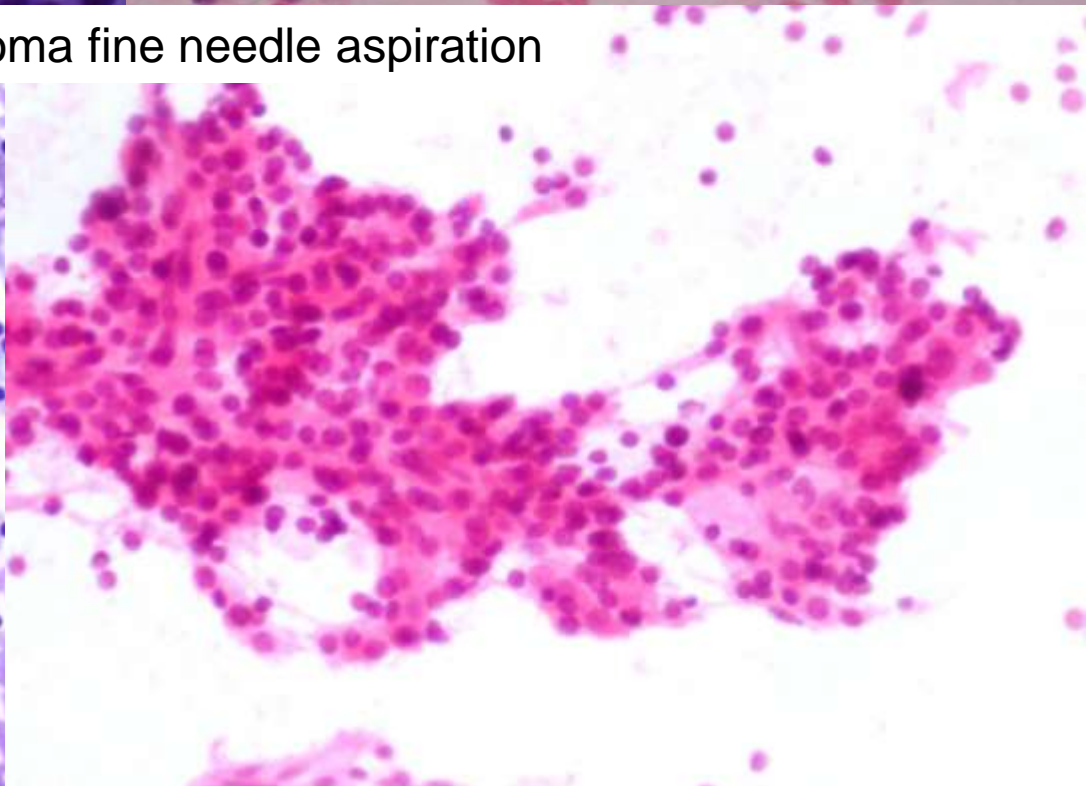
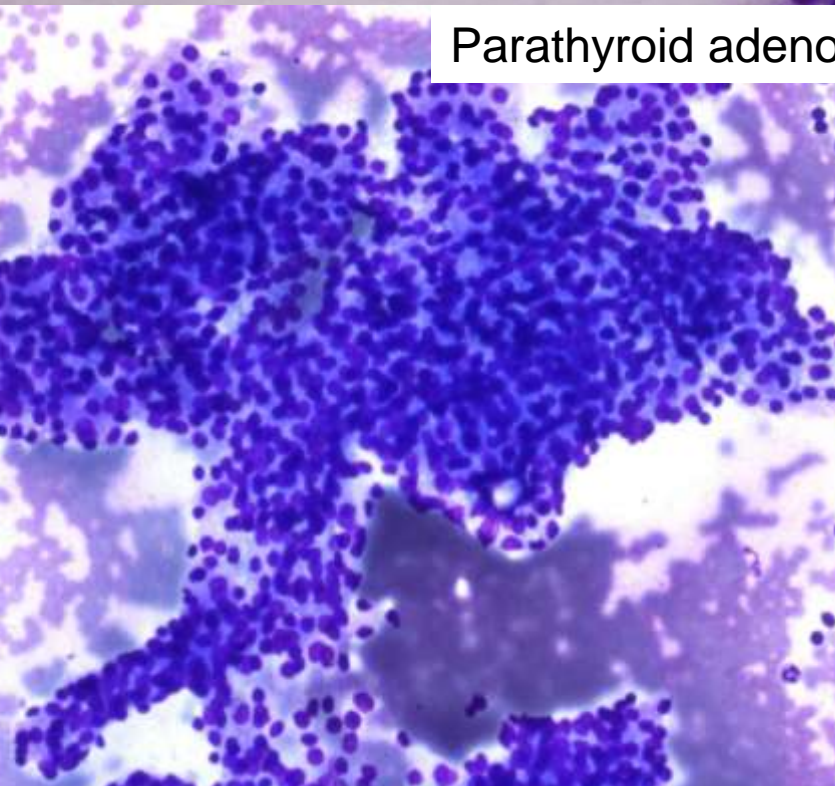
Few microfollicles


Single cells and nude nuclei

Small round cells

Overlapping nuclei

Parathyroid adenoma fine needle aspiration





Case 4

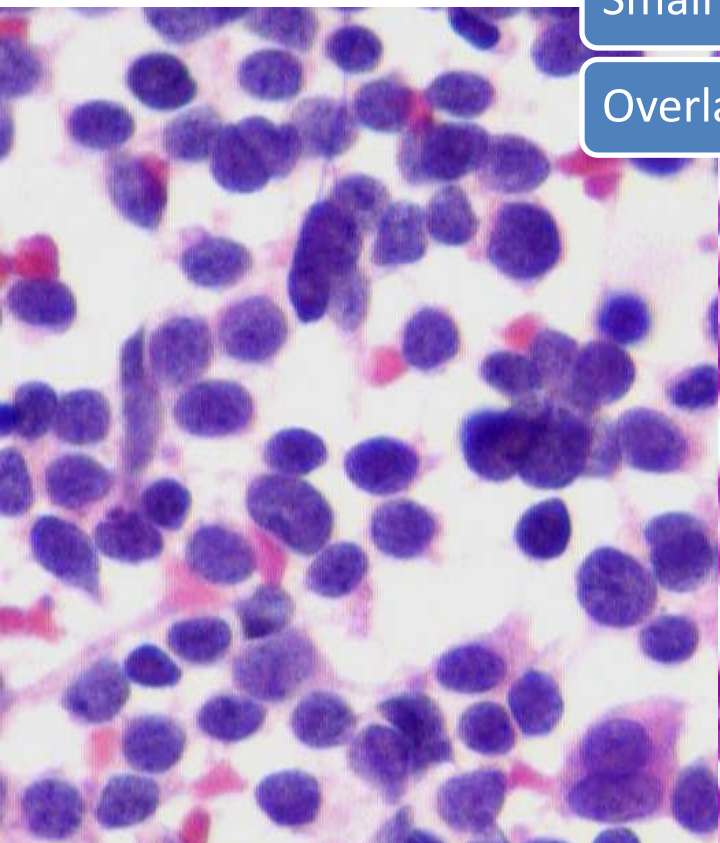
Cohesive three-dimensional groups

Few microfollicles

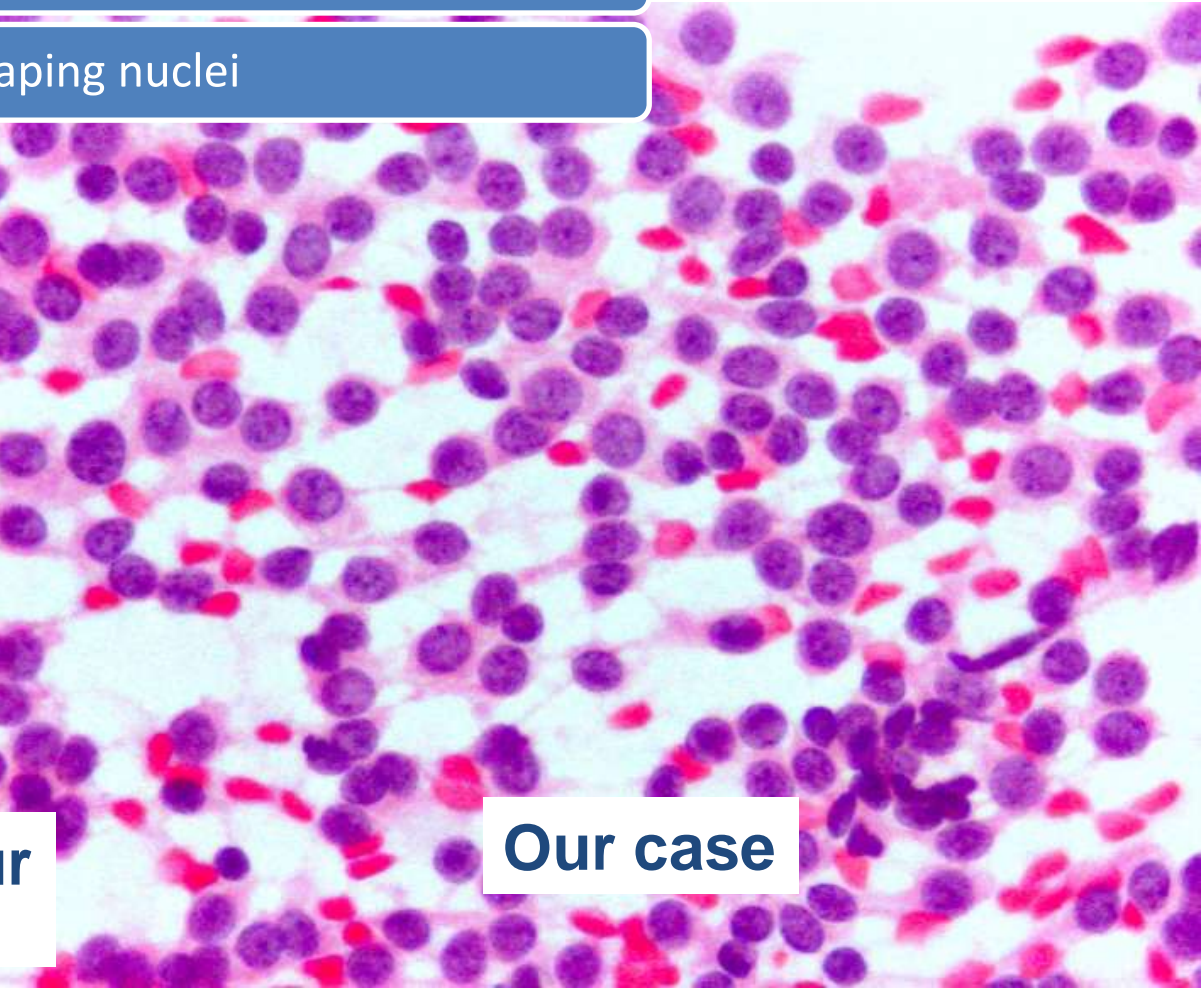
Single cells and nude nuclei

Small round cells

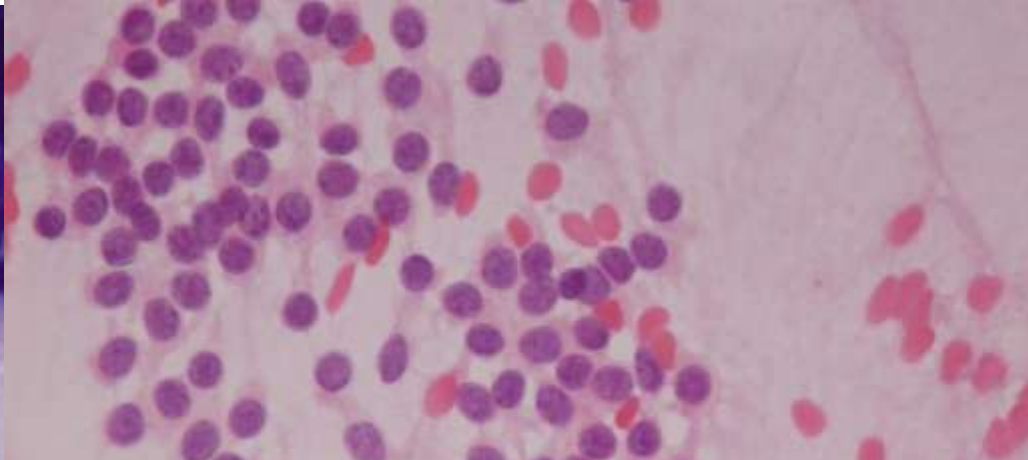
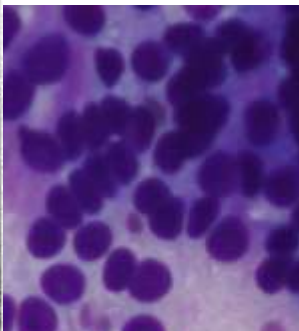
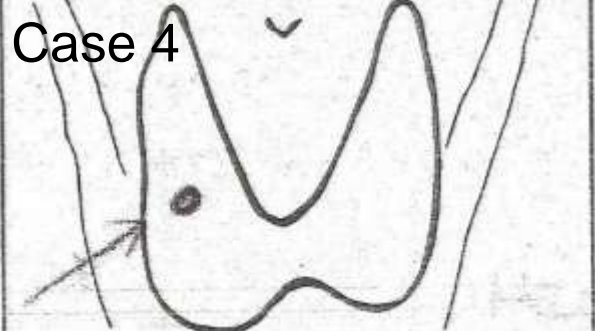
Overlapping nuclei



**Neuroendocrine tumour
metastasis**

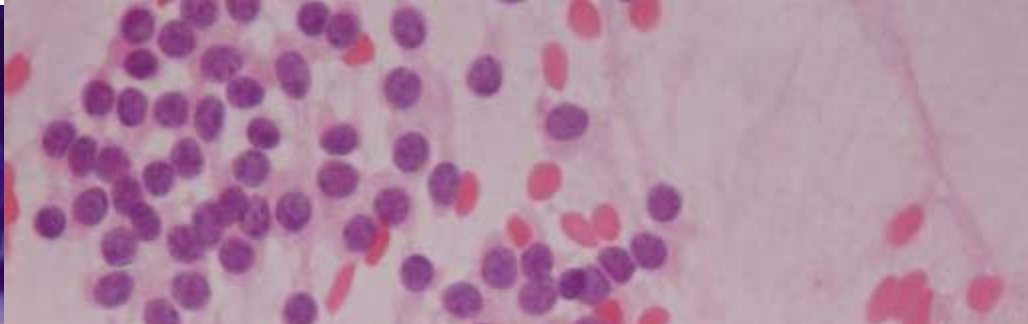
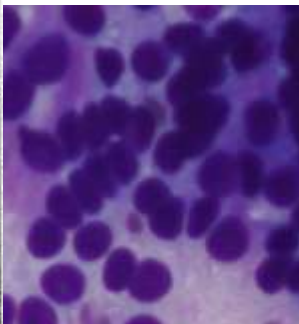
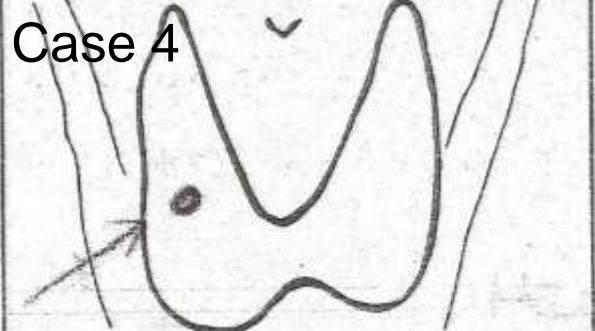


Our case

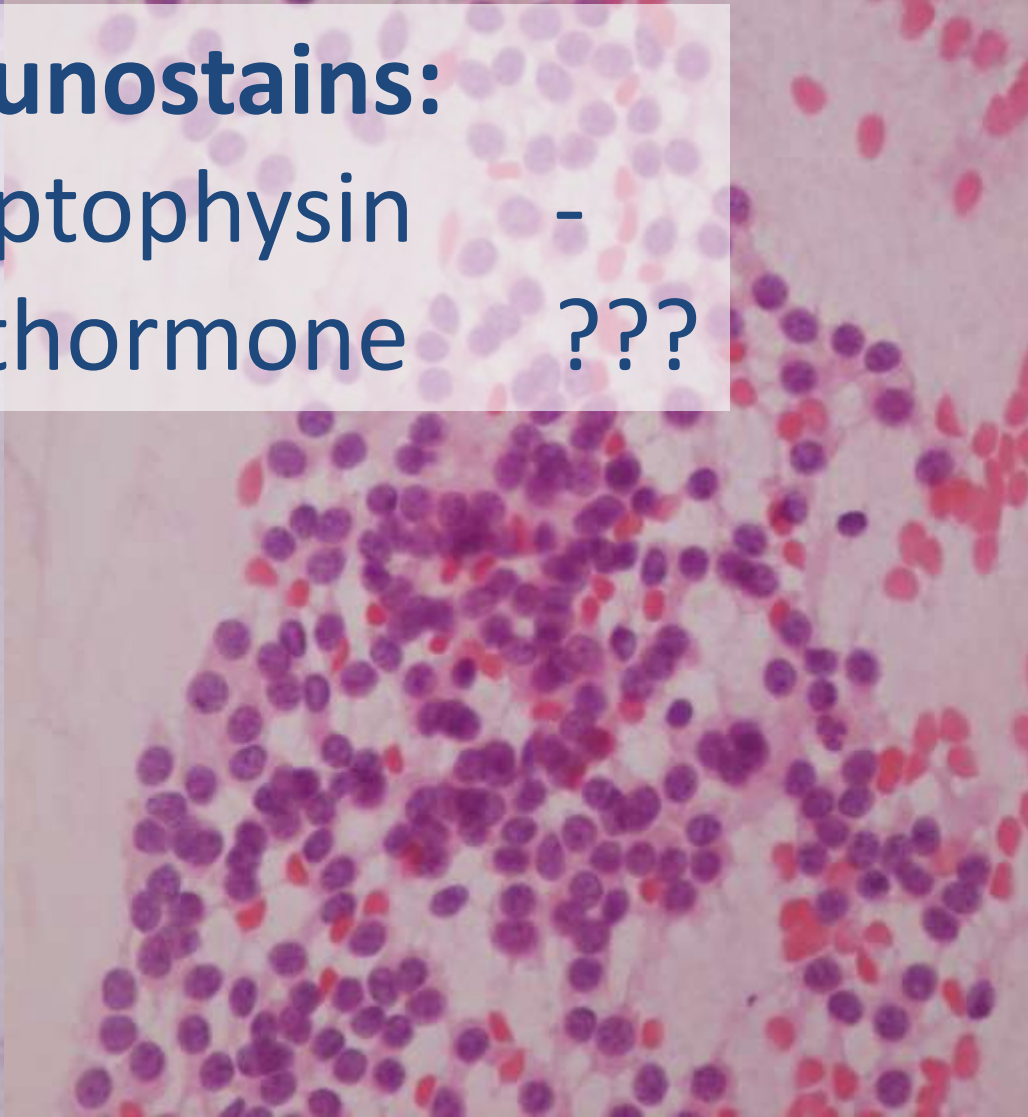
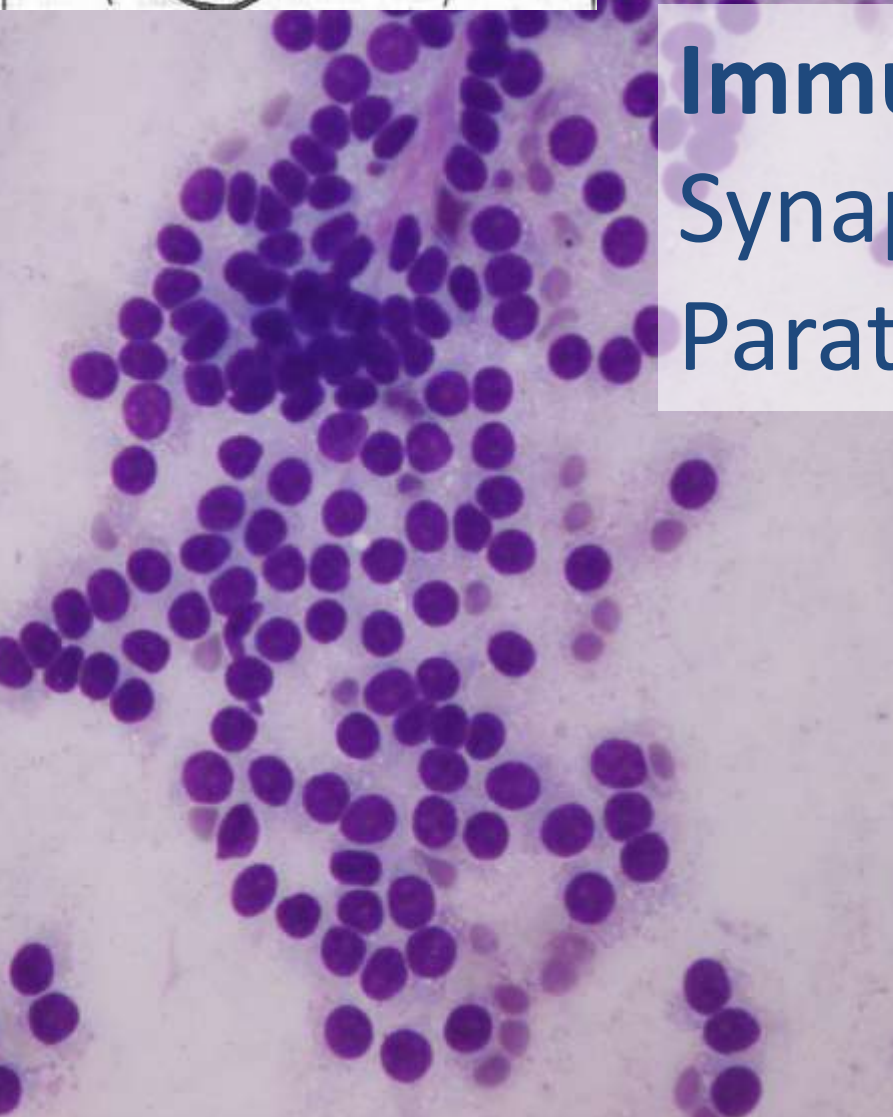


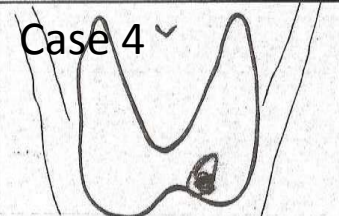
Cytology- diagnosis

- Follicular/acinar tumour
- Thyroid?
- Parathyroid?
- Other? (Neuroendocrine Tumour-metastasis?)

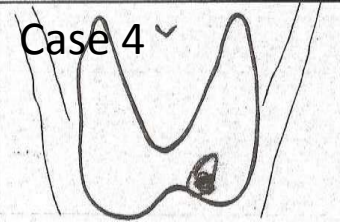


Immunostains:
Synaptophysin -
Parathormone ???





SANGUE	Data Pedido	Unidade	V. referência
ENDOCRINOLOGIA	Resultado		
2010-08-12 11:14			
CALCITONINA			
Resultado	<2.0	pg/mL	< 5.0
PTH-I (PARATHORMONA-I)			
Resultado.	36.3	pg/mL	10.0 - 65.0
T3 LIVRE			
Resultado.	2.82	pg/mL	1.71 - 3.71
T4 LIVRE			
Resultado.	1.07	ng/dL	0.70 - 1.48
TSH			
Resultado.	2.04	«u»UI/mL	0.35 - 4.94
25-OH-VITAMINA D			
25-OH-Vitamina D3	10	ng/ml	
		Adolescente e adulto:	
		Valor recomendável: 30 - 80	
		Deficiencia: < 15	
		Factor de conversão: ng/mL x 2.496 = nmol/L	



Bethesda

- NONDIAGNOSTIC or UNSATISFACTORY
- BENIGN
- ATYPIA OF UNDETERMINED SIGNIFICANCE or FOLLICULAR LESION OF UNDETERMINED SIGNIFICANCE
- FOLLICULAR NEOPLASM or SUSPICIOUS FOR A FOLLICULAR NEOPLASM
- SUSPICIOUS FOR MALIGNANCY
- MALIGNANT

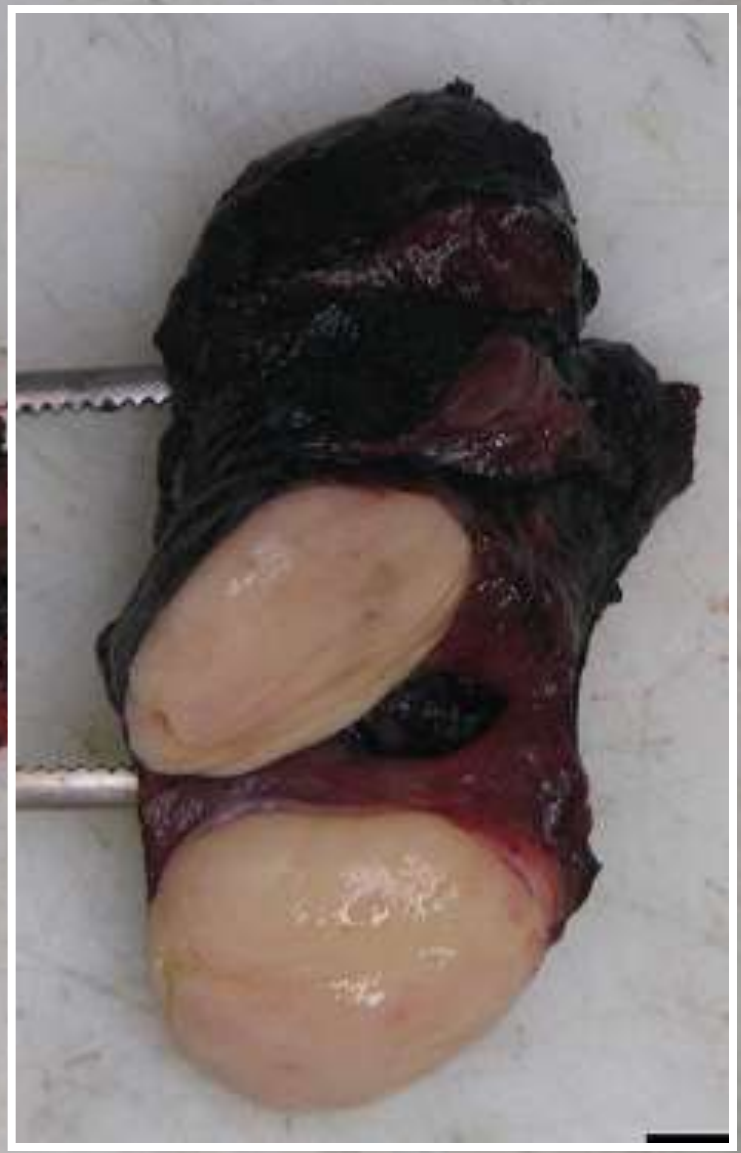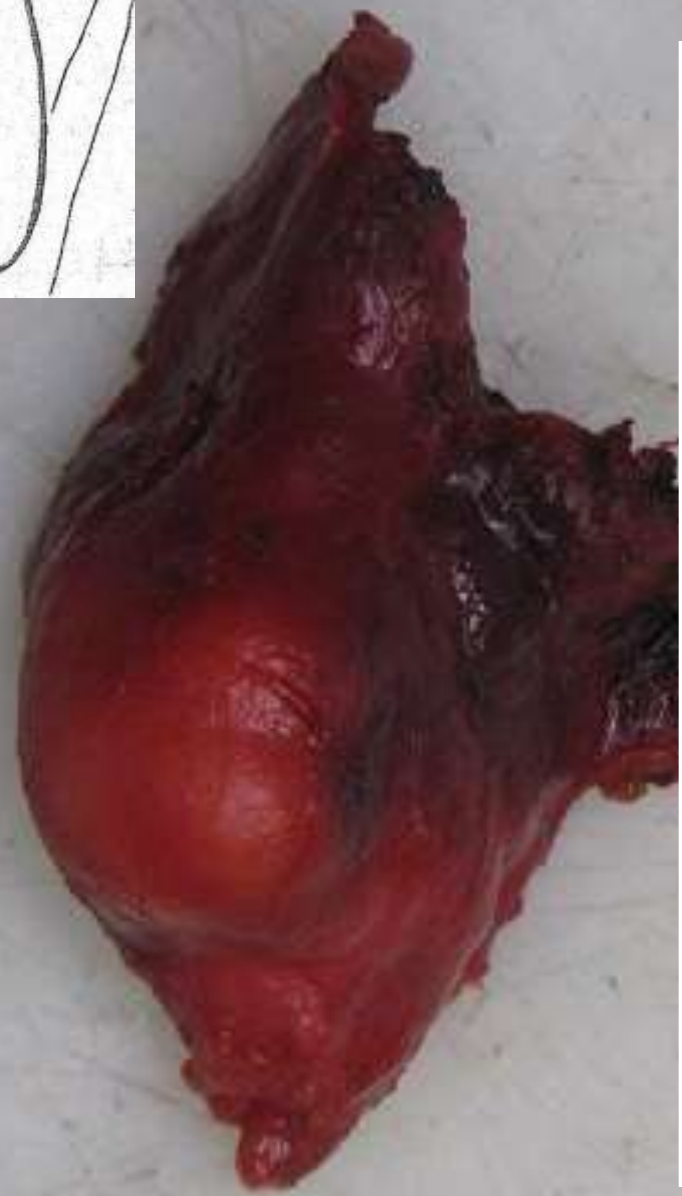

~~Parathyroid~~

?

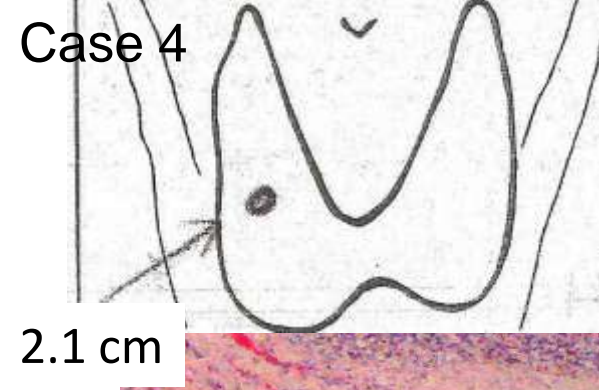
Case 4

2.1 cm

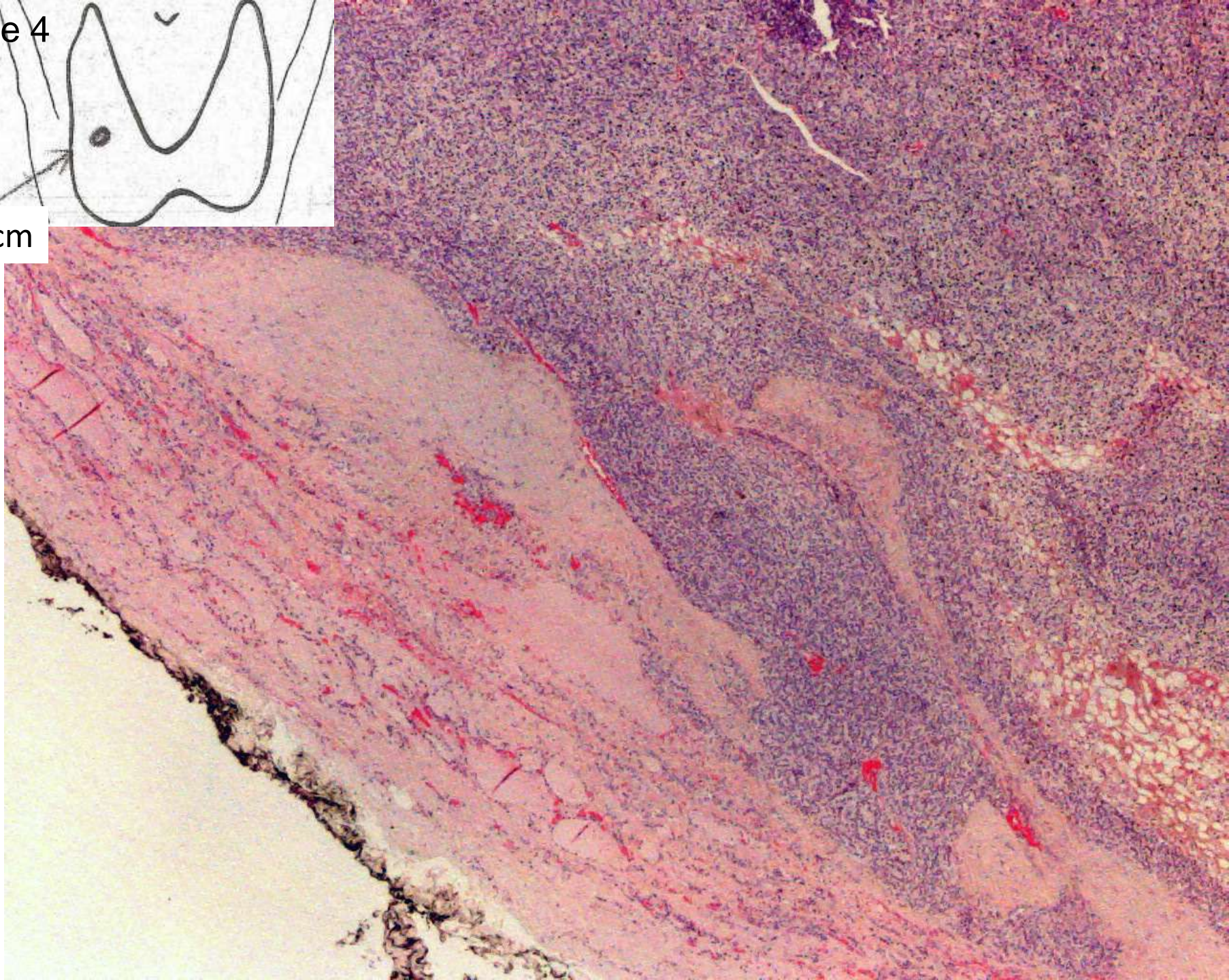
Right lobectomy -7g

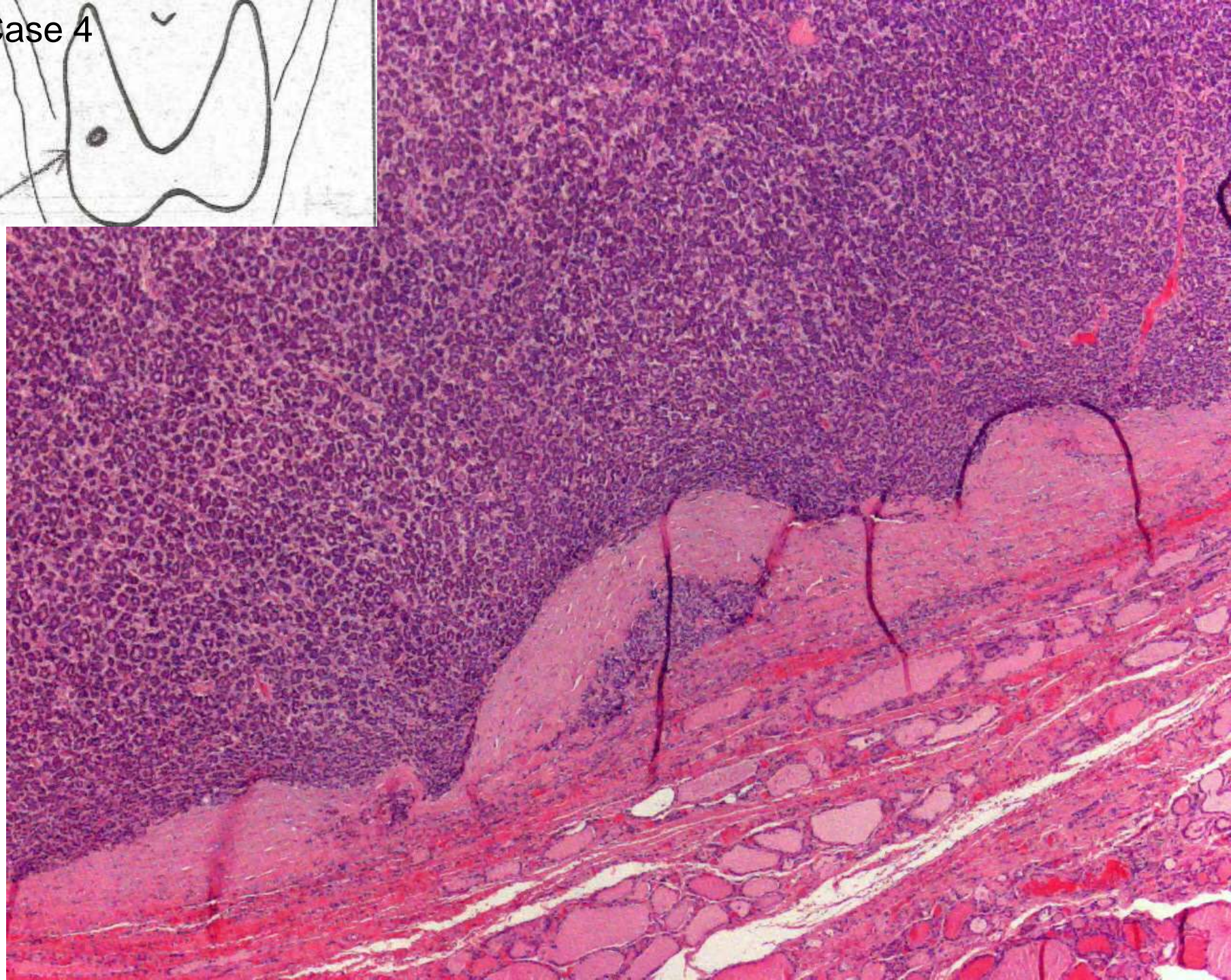



H10.21858

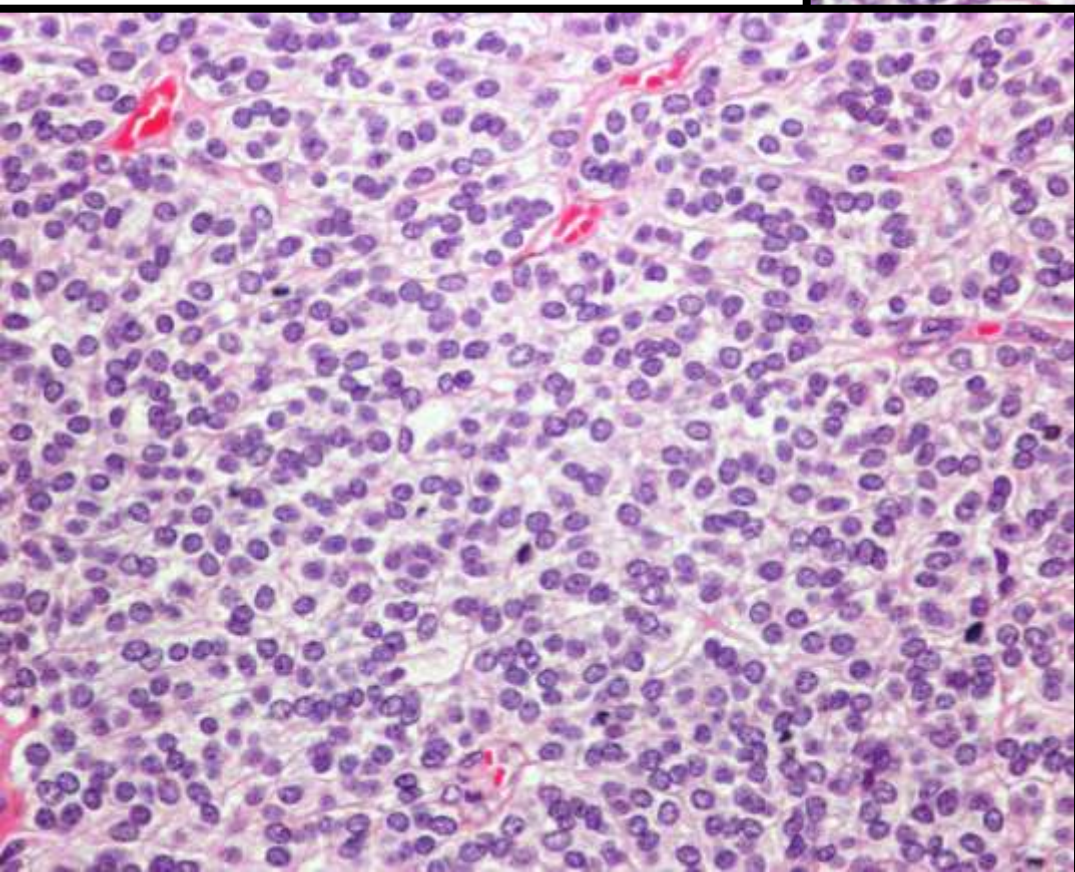
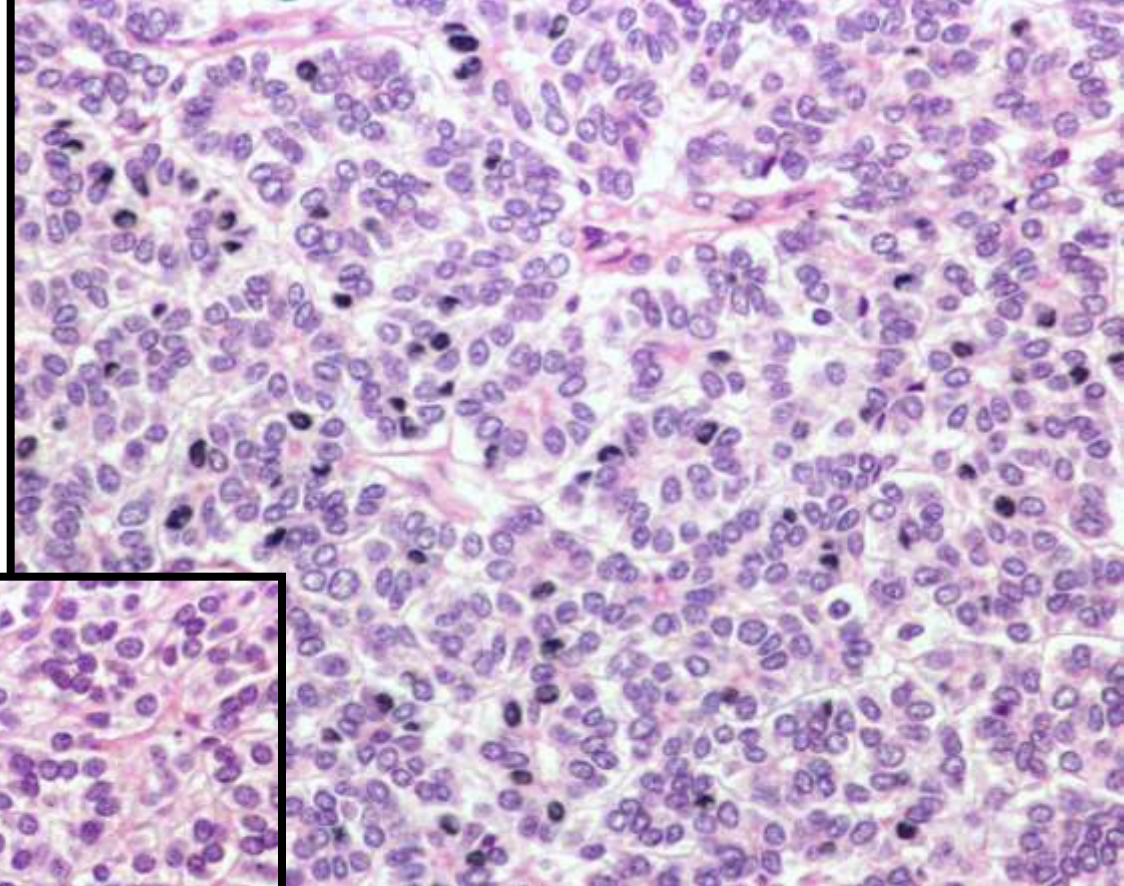
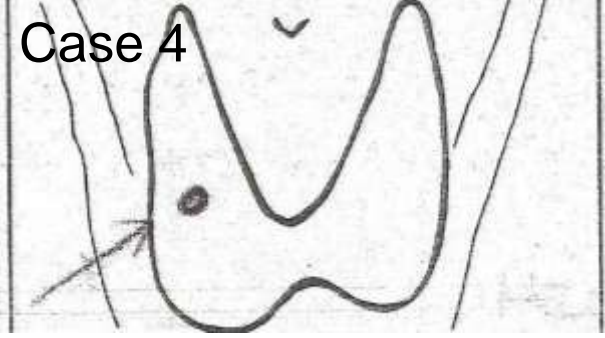


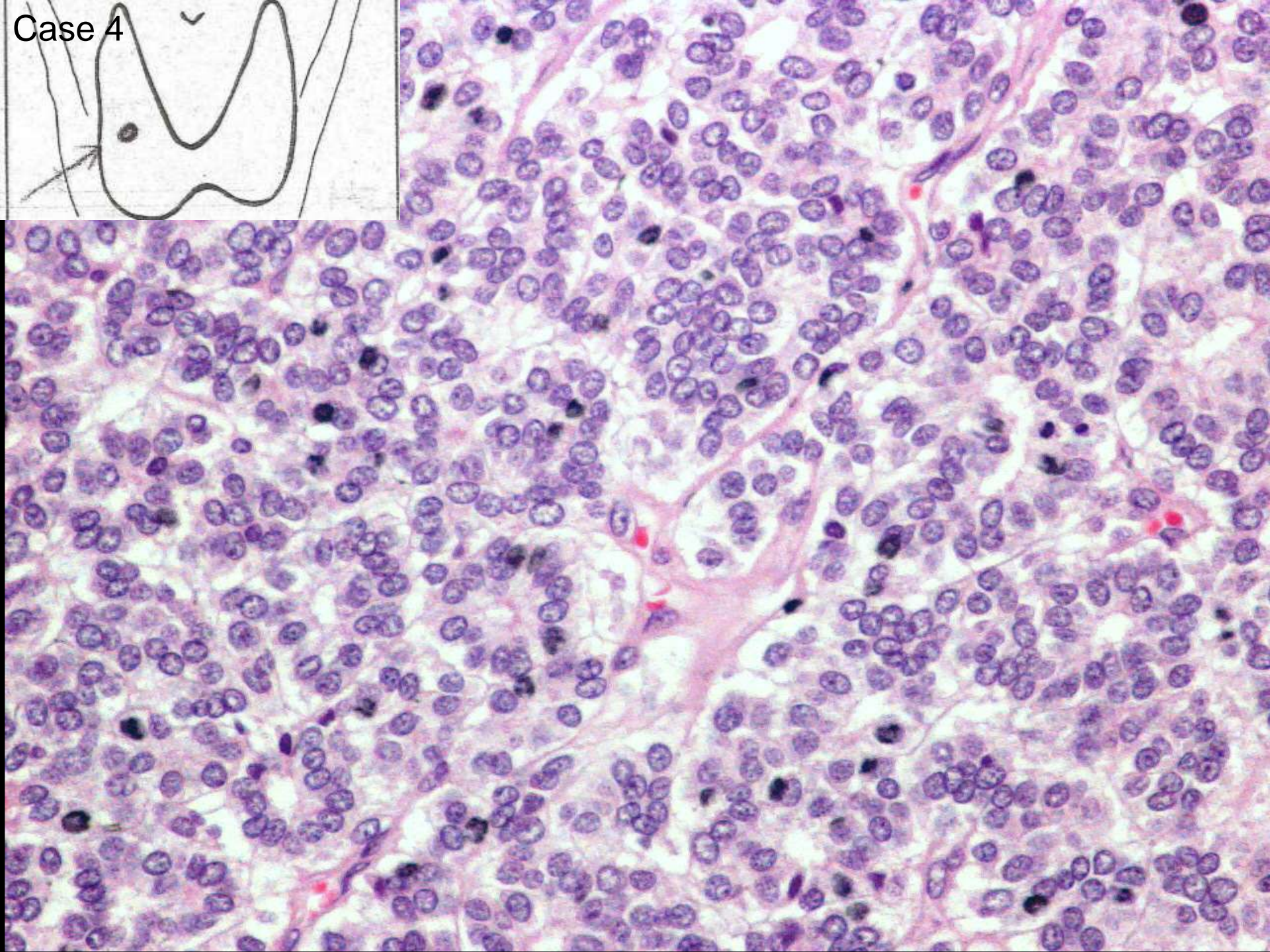

Right lobectomy -7g





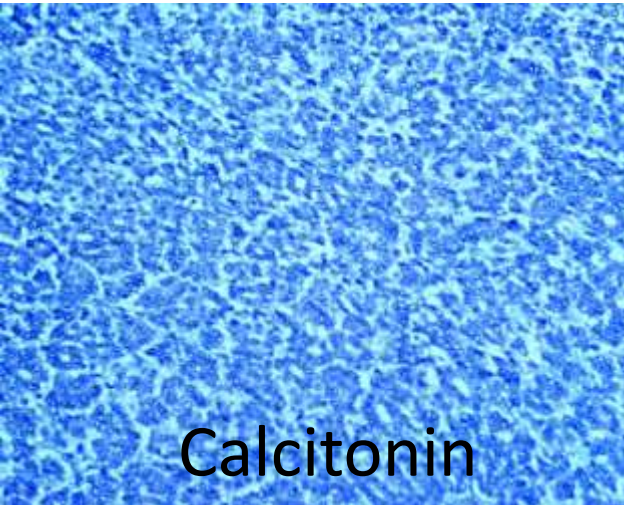
Case 4



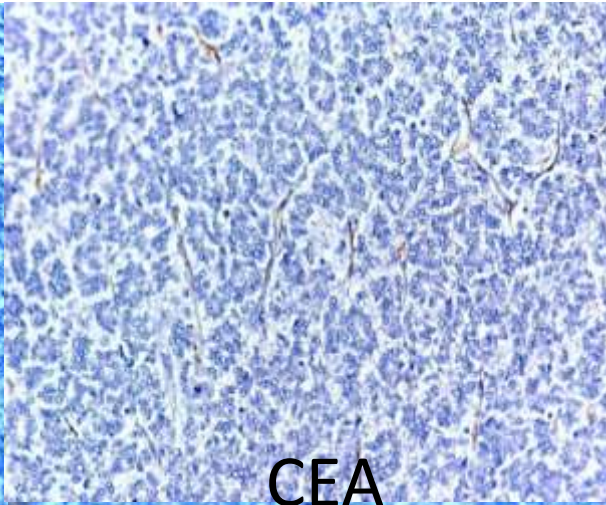




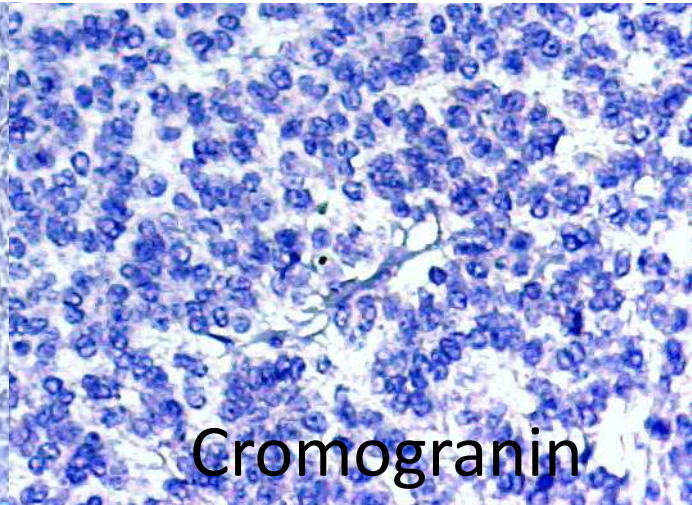
IMMUNOSTAINS



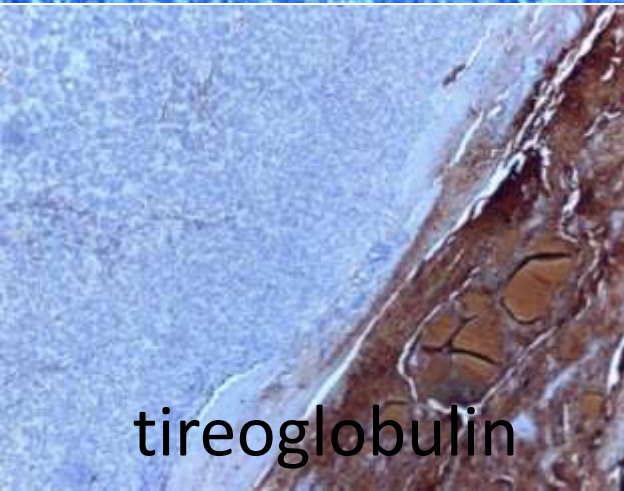Calcitonin



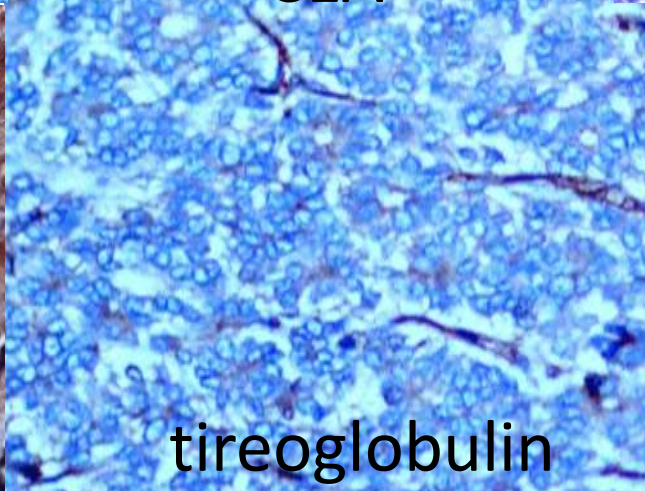
CEA



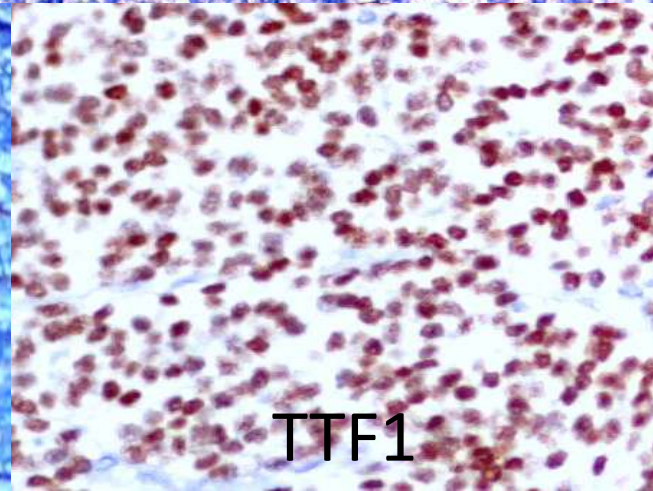
Chromogranin




tireoglobulin



tireoglobulin



TTF1



Histology Diagnosis

Follicular carcinoma with minimal invasion

In any case impossible to diagnose by cytology; in this particular case the situation was even worse, due to a probable mutation in a gene involved in Tg synthesis

Caviar

