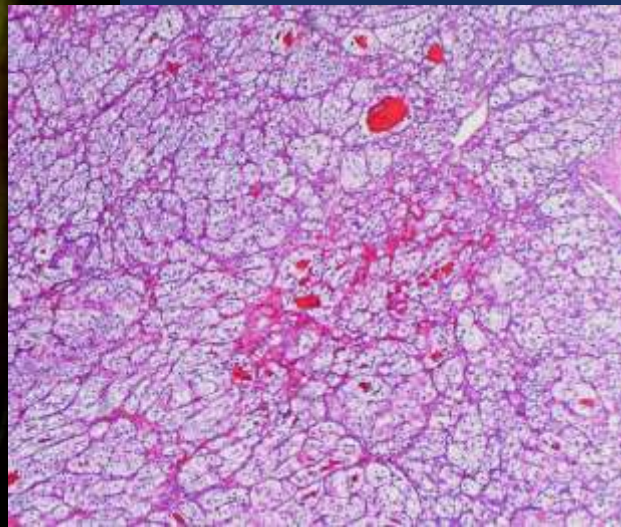
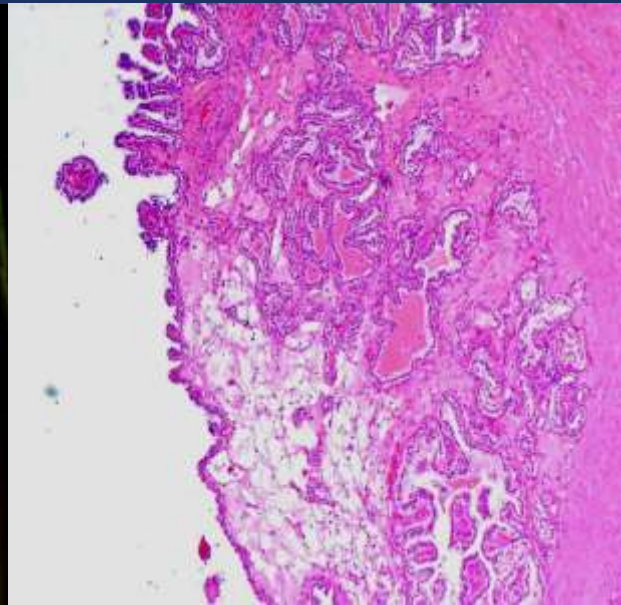
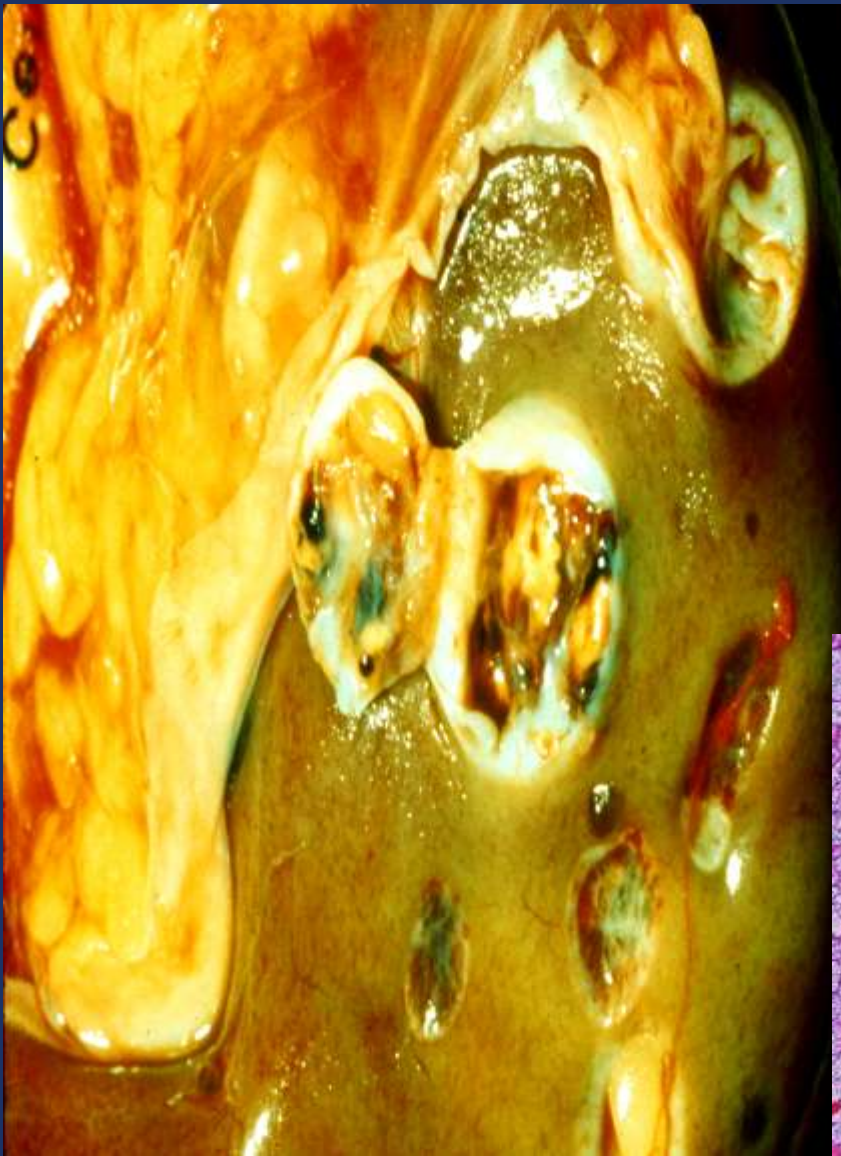


# Que hay de nuevo en Patologia Renal


**Maria J Merino MD**  
**NCI**




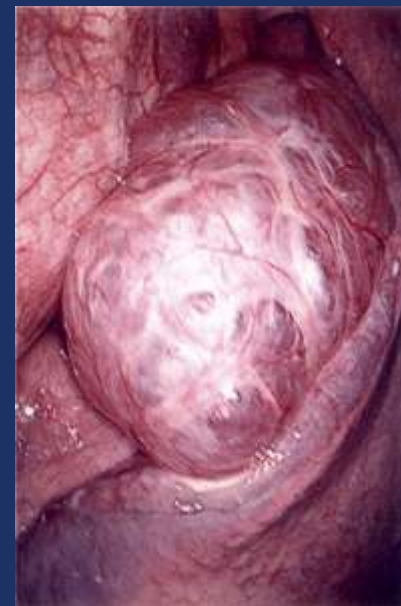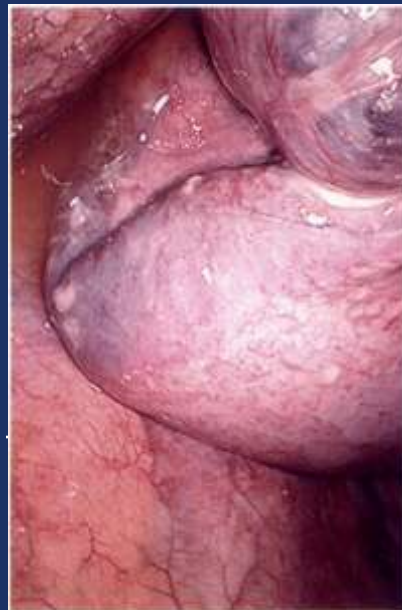
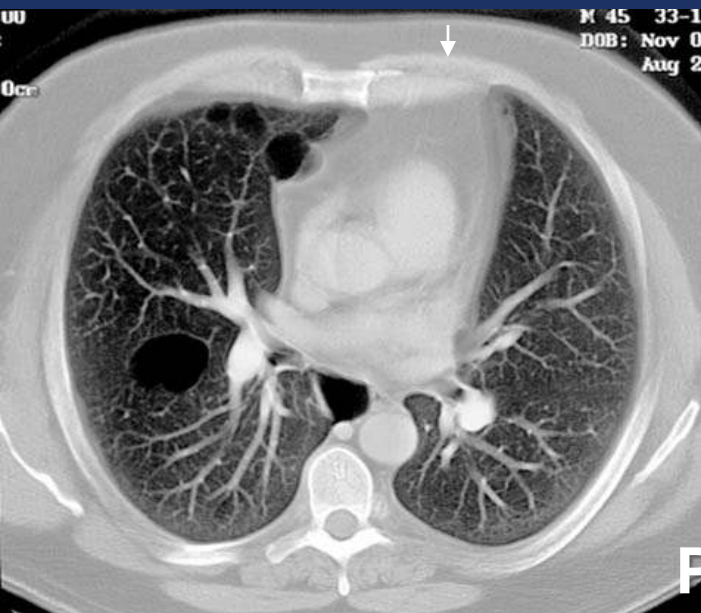
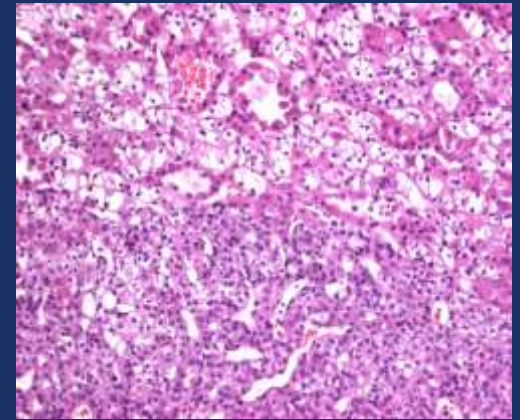
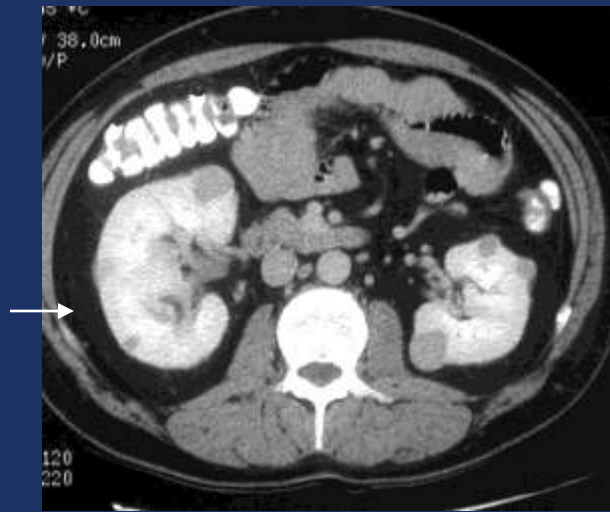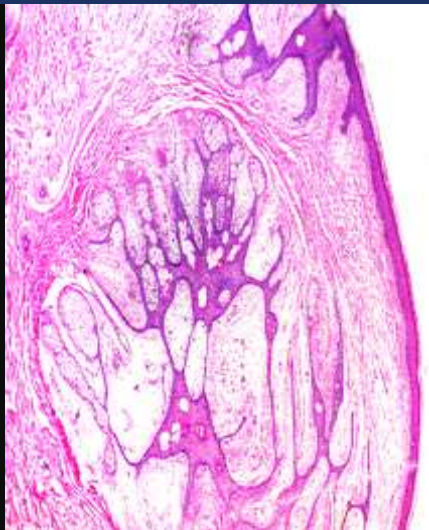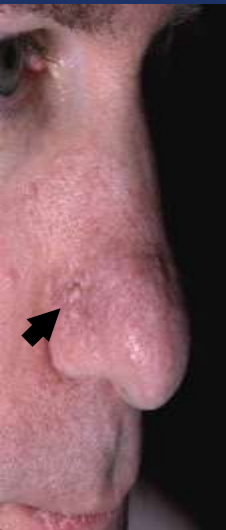# von Hippel-Lindau (VHL) Multiple Lesions



## Ideogram

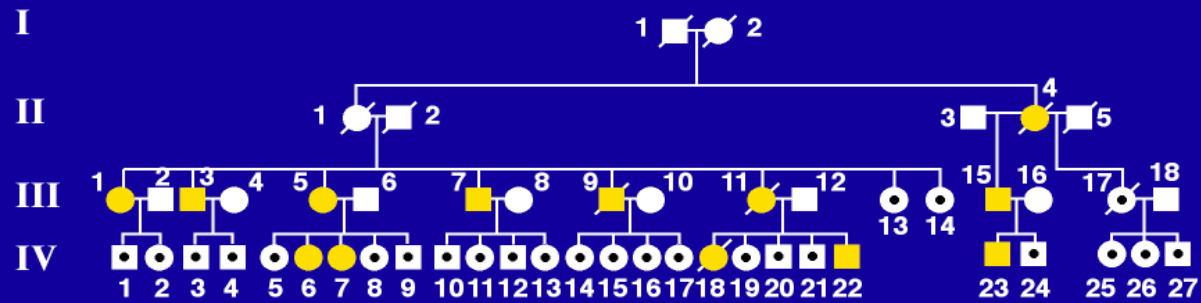
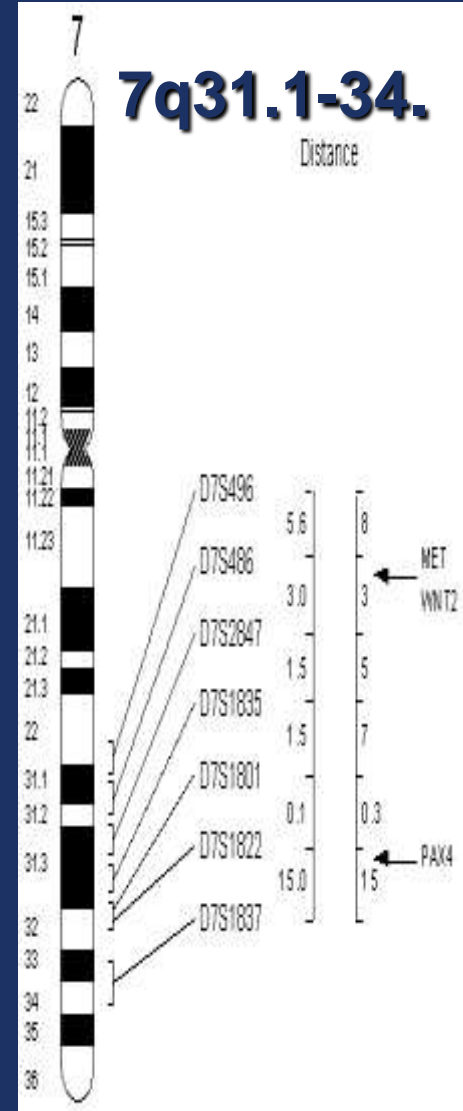
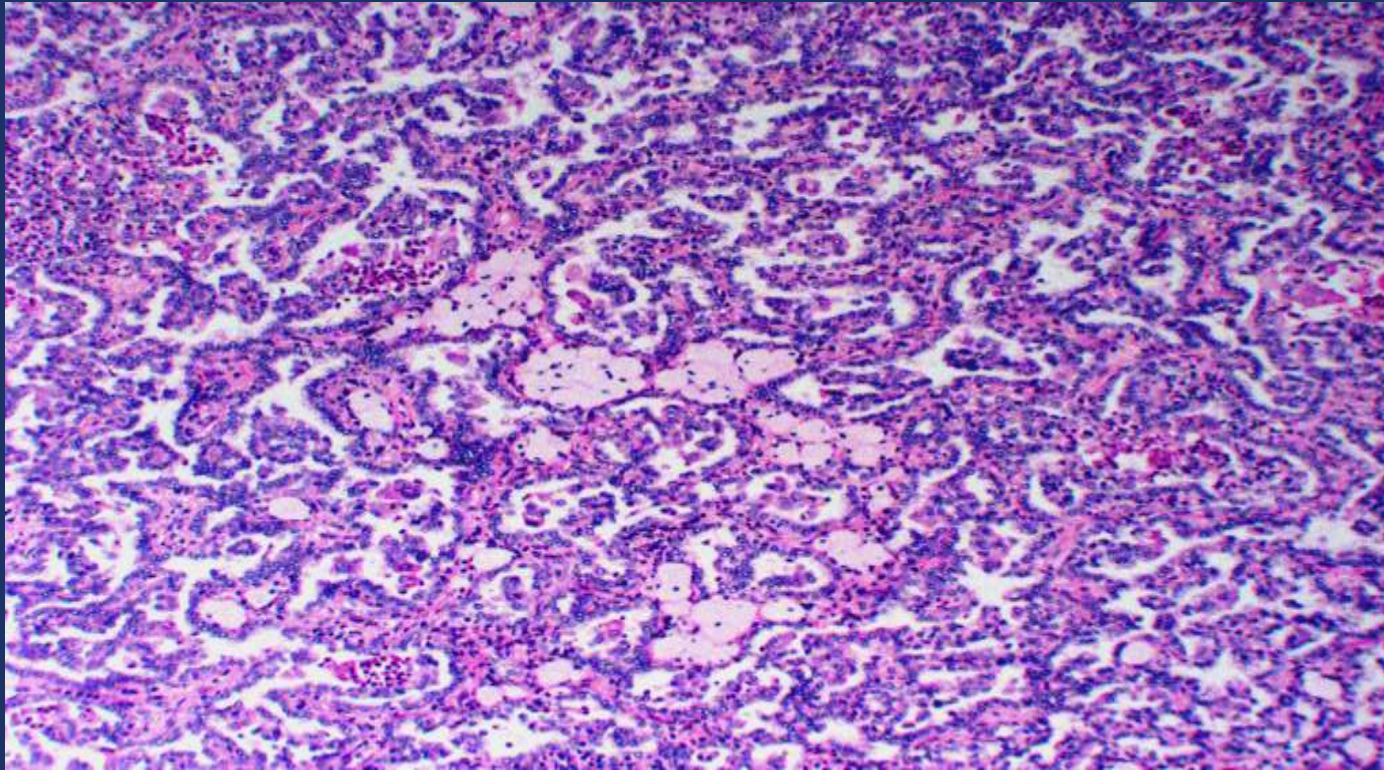


# Birt-Hogg-Dubé syndrome

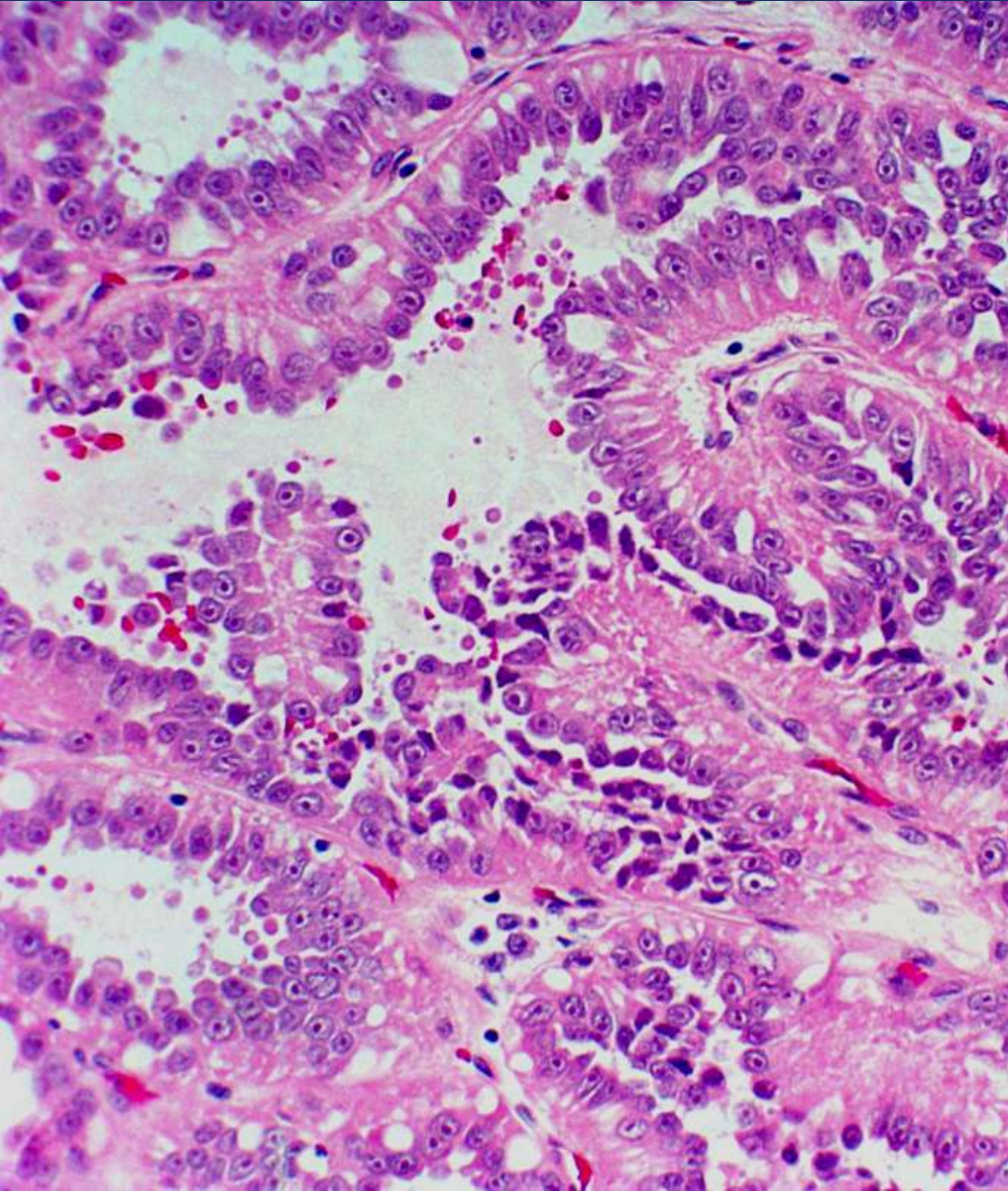


Pavlovich CP Merino MJ: AJSP

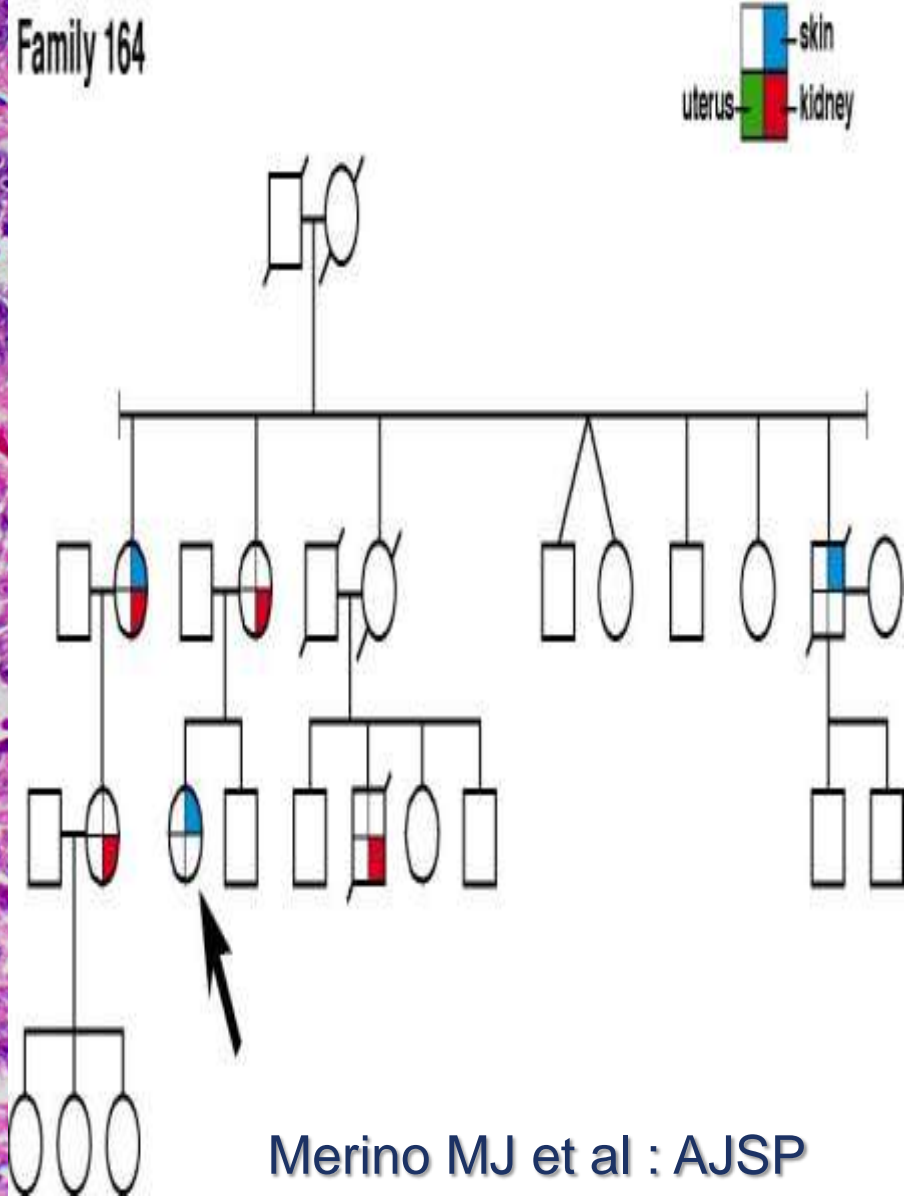
# Papillary RCC type I.



# HEREDITARY LEIOMYOMATOSIS AND RENAL CELL CARCINOMA SYNDROME



Family 164



# Therapy (Hereditary)

- Morphology...genetic testing.....
- Patients with Tumors smaller than 3-4 cm have excellent prognosis with prolonged survivals. (10-15)
- Partial nephrectomy for tumors less than 3 cm with removal of cysts and smaller lesions.
- Close follow up of small lesions.
- Evaluation of family members, genetic testing and counseling.
- HLRCC New molecular targets, longer survival

## Therapy (Sporadic)

Surgery, IL2, new molecular targets

Fig 8

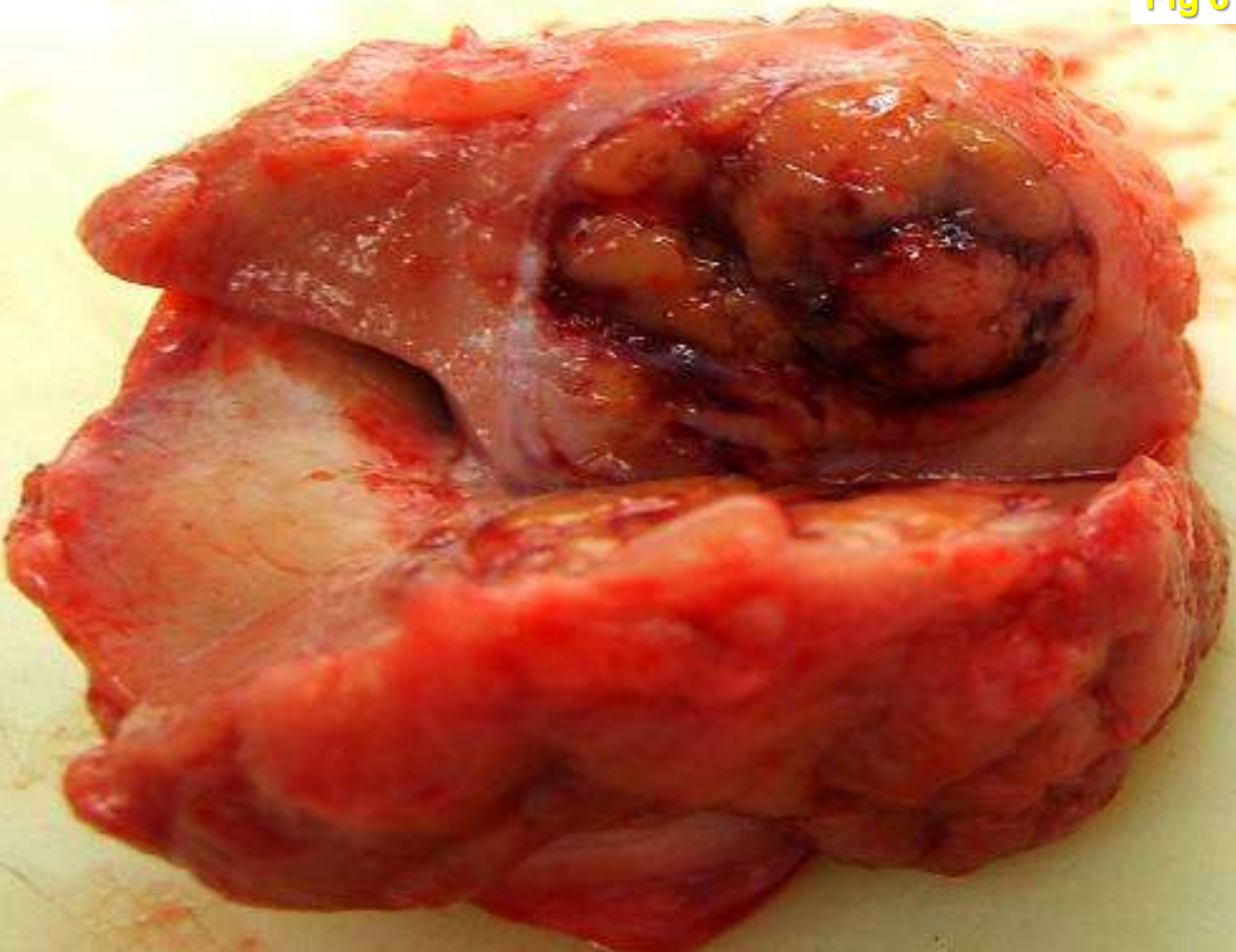
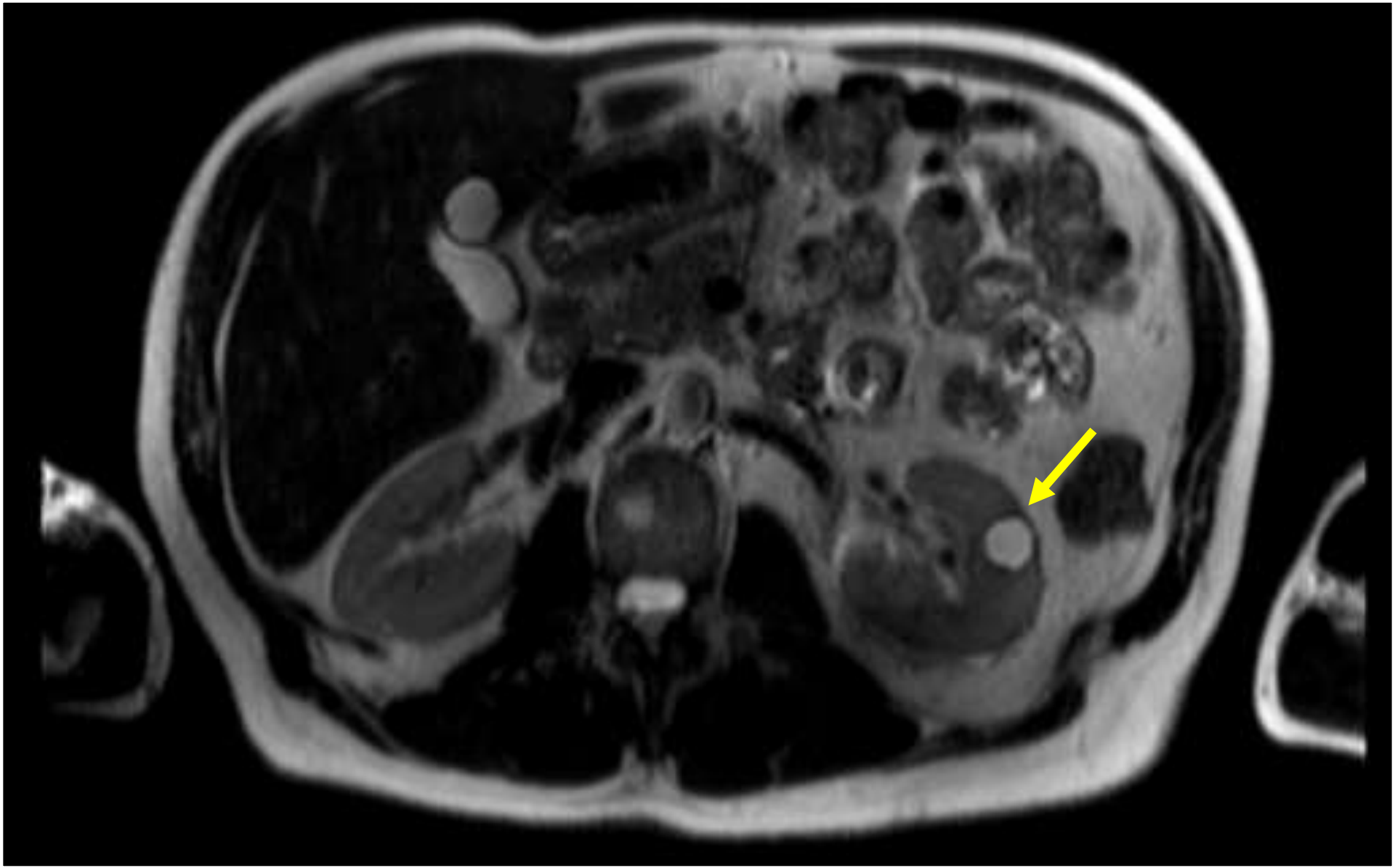
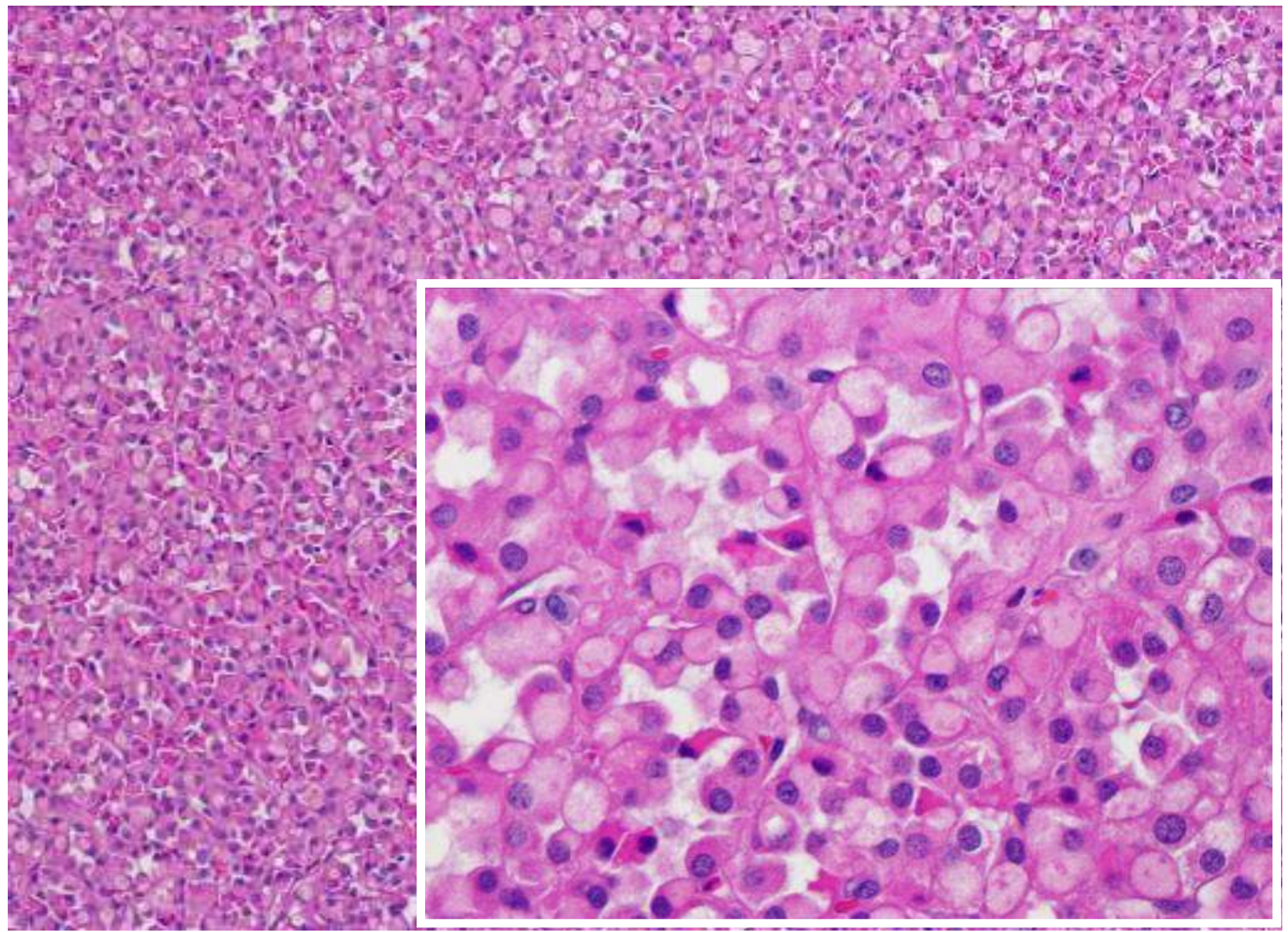


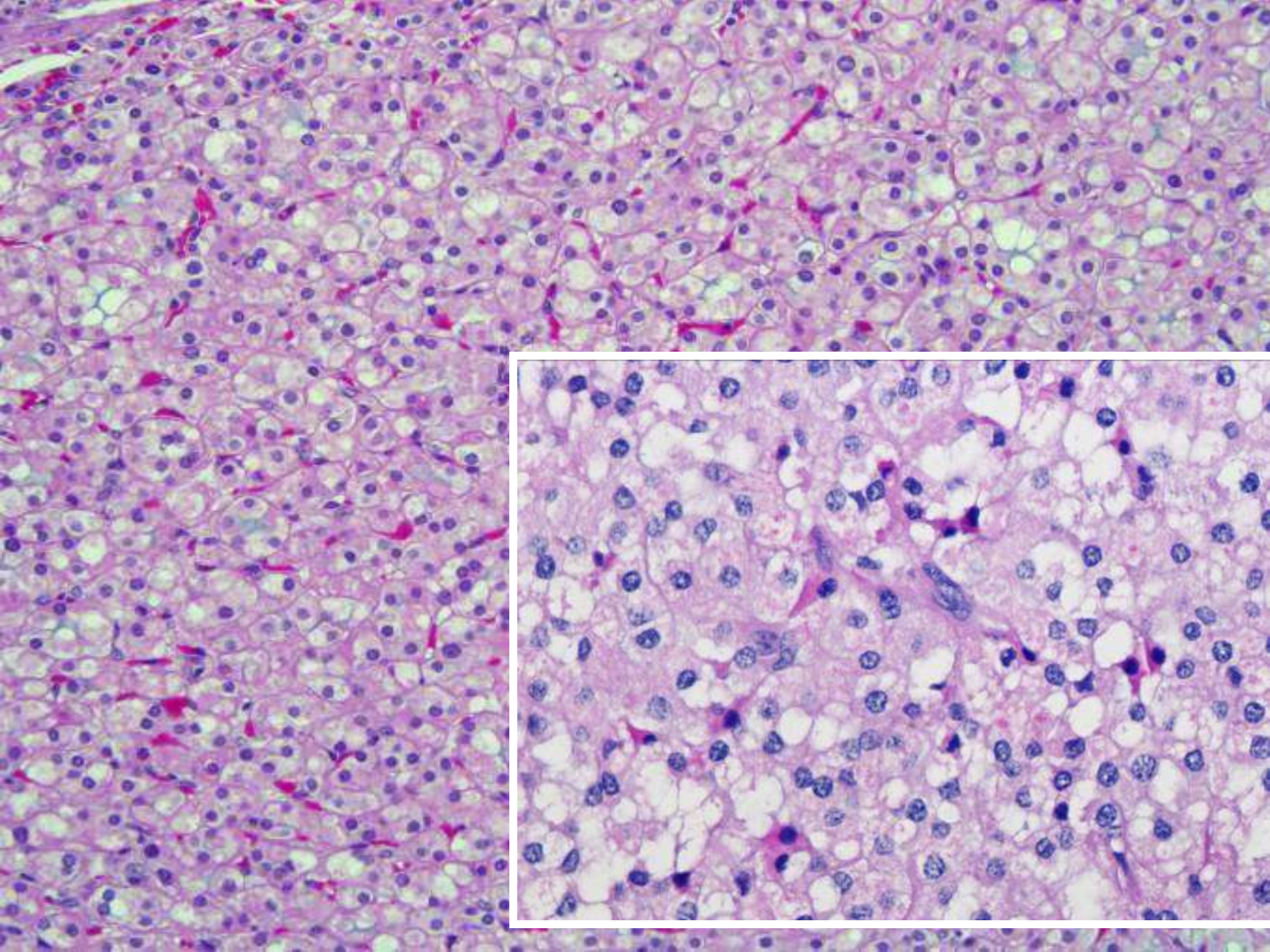
Fig 4

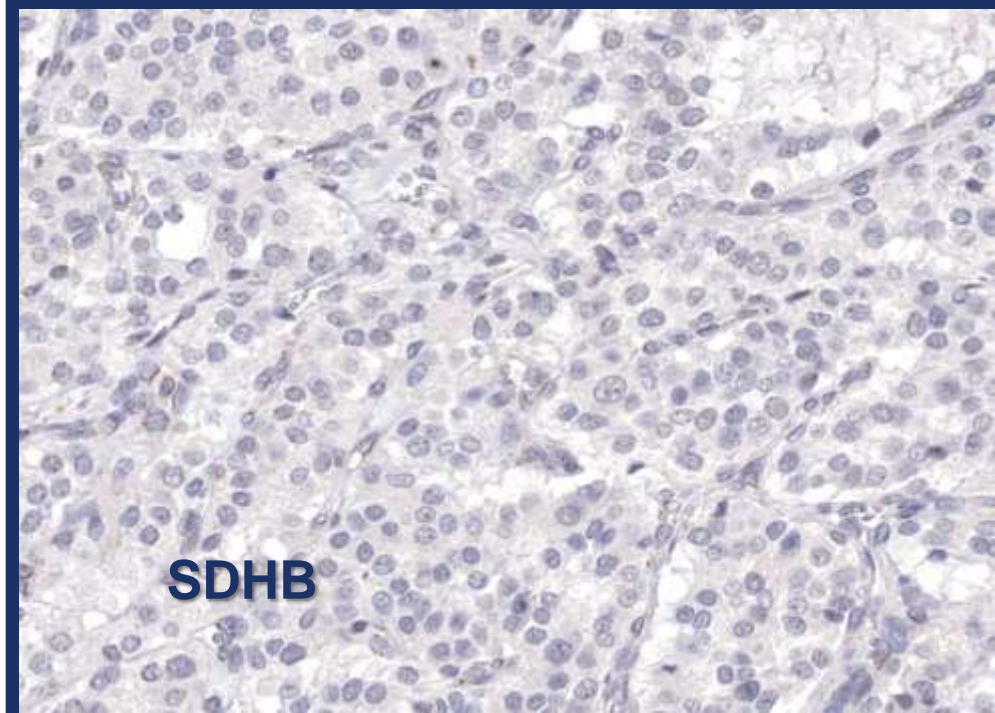
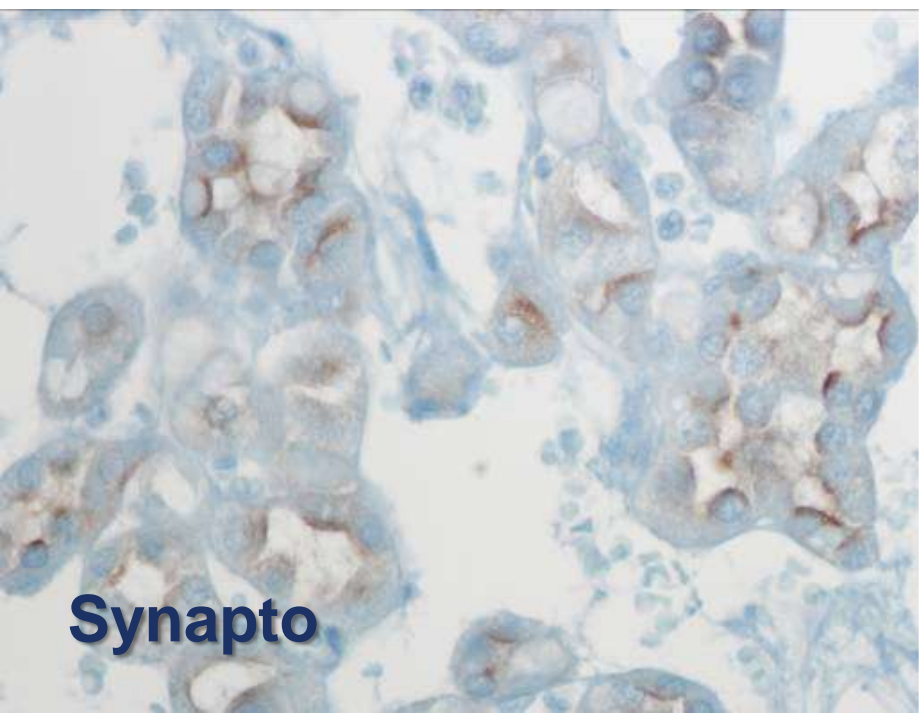
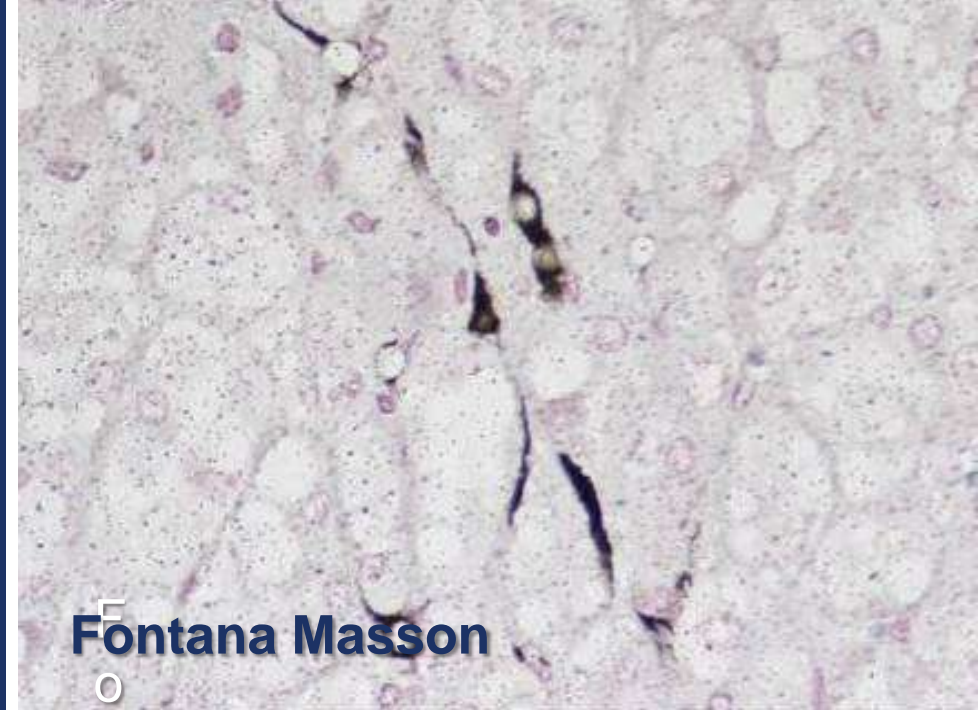
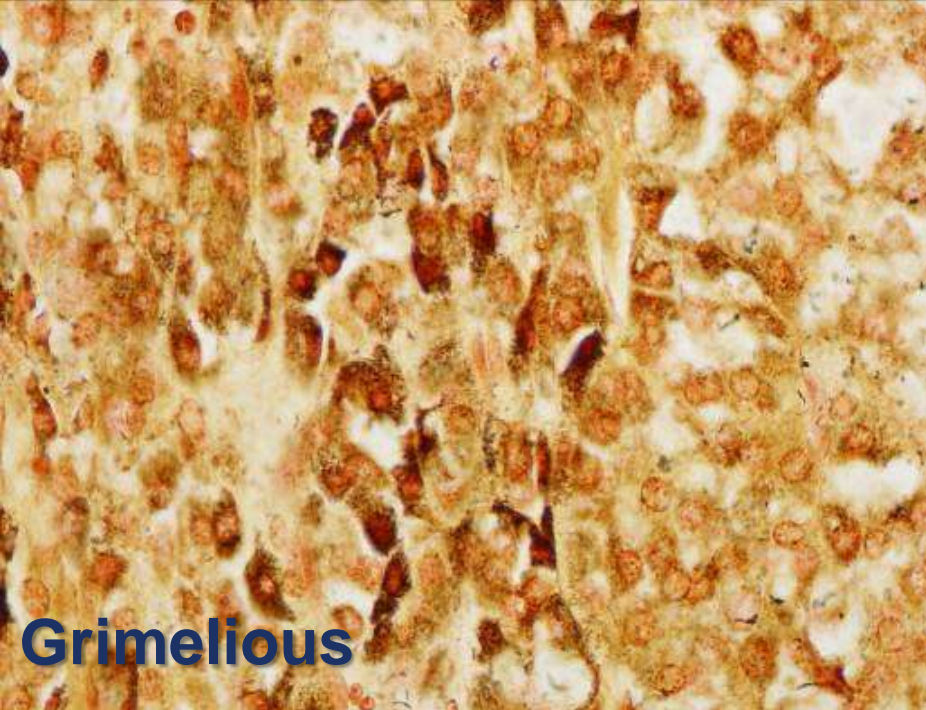


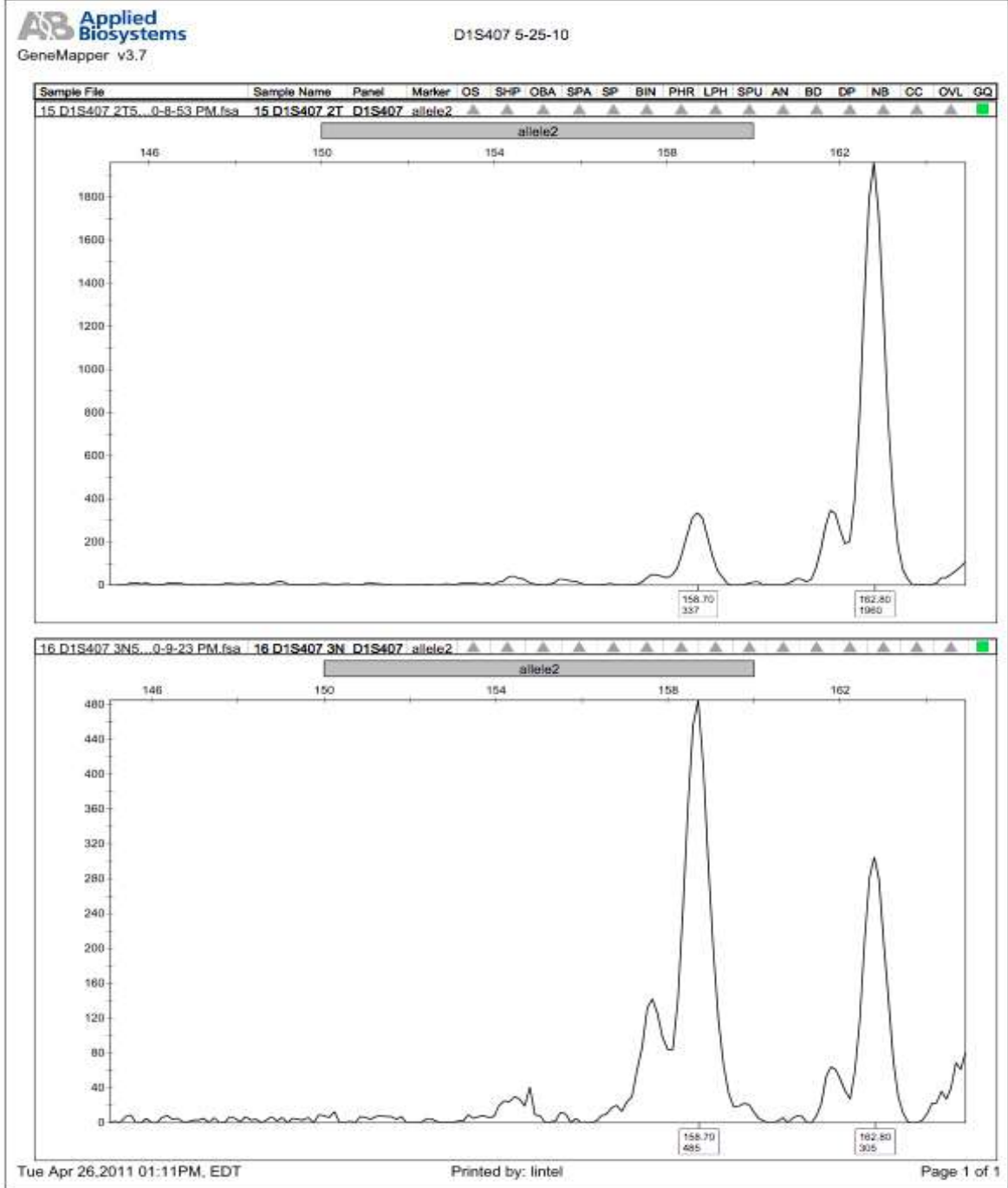
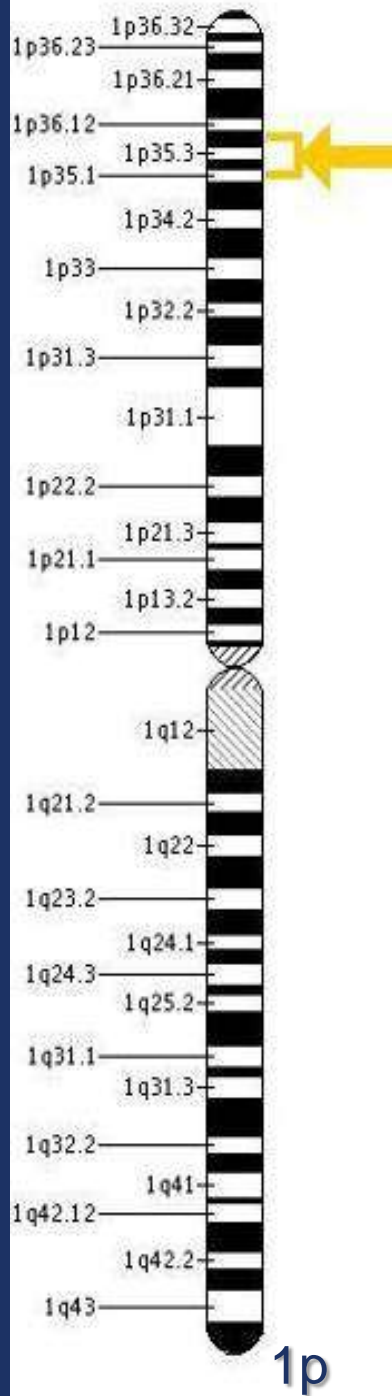


A renal mass was found in a 56 year old male while he was being evaluated for hypertension. The patient was referred to the UOB for evaluation and consideration of acceptance in protocol. He could not remember any one in his family with kidney cancer.







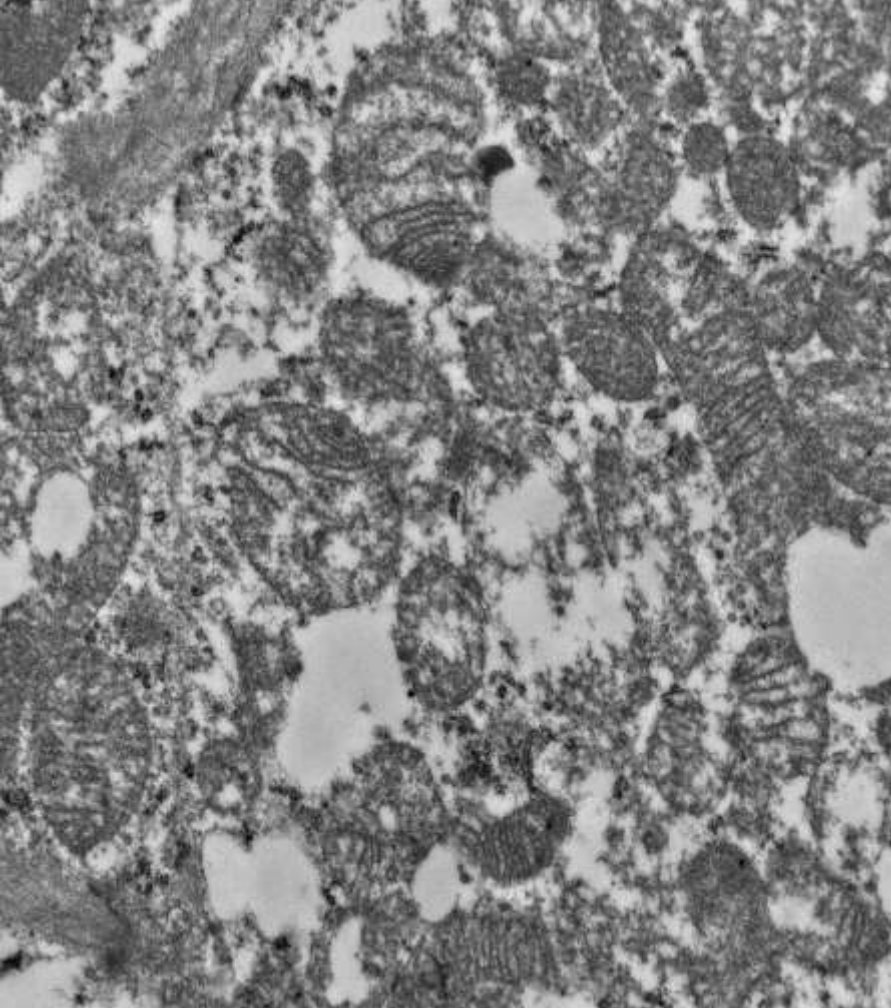


# Diagnosis:

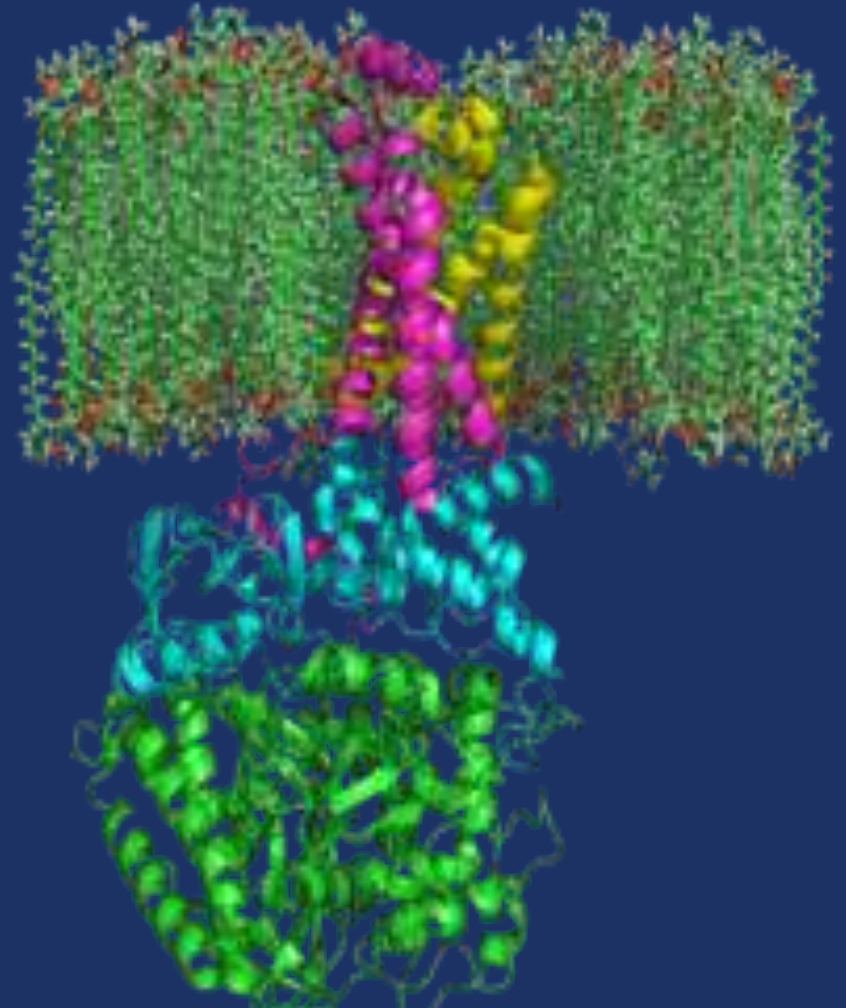
## SDHB related Renal cell Carcinoma

### SDH

The location of the gene in humans is on the first chromosome at locus p36.1-p35. The gene is coded in 1162 base pairs, partitioned in 8 exons. The expressed protein has 280 amino acids.



The gene that codes for the SDHB protein is nuclear. However, the protein is located in the inner membrane of the mitochondria.



The structure of Complex II in a phospholipid membrane. **SdhA**, **SdhB**, **SdhC** and **SdhD**.

# Clinical manifestations related to SDH

- **SDHA:** Leigh syndrome, encephalopathy, optic atrophy. Chromosome 5q
- **SDHB:** HPPGL syndrome, frequently malignant, decreased life span. Renal cancer. GIST Chromosome 1p35. (PGL4)
- **SDHC:** HPPGL syndrome, frequently benign, Renal cancer (PGL3)
- **SDHD:** HPPGL syndrome, benign, Chromosome 11. (PGL1)



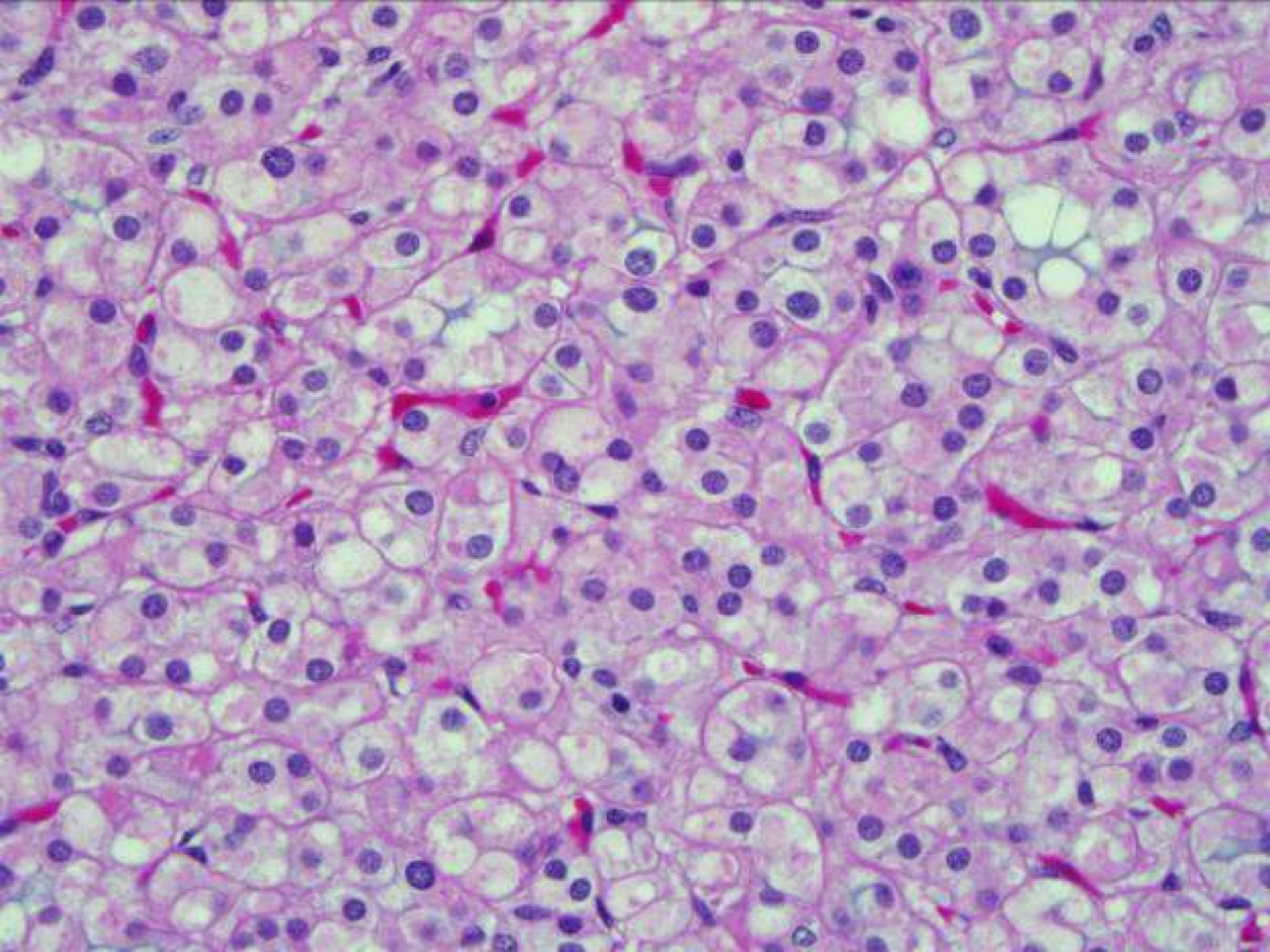
# SDHB (PGL4)

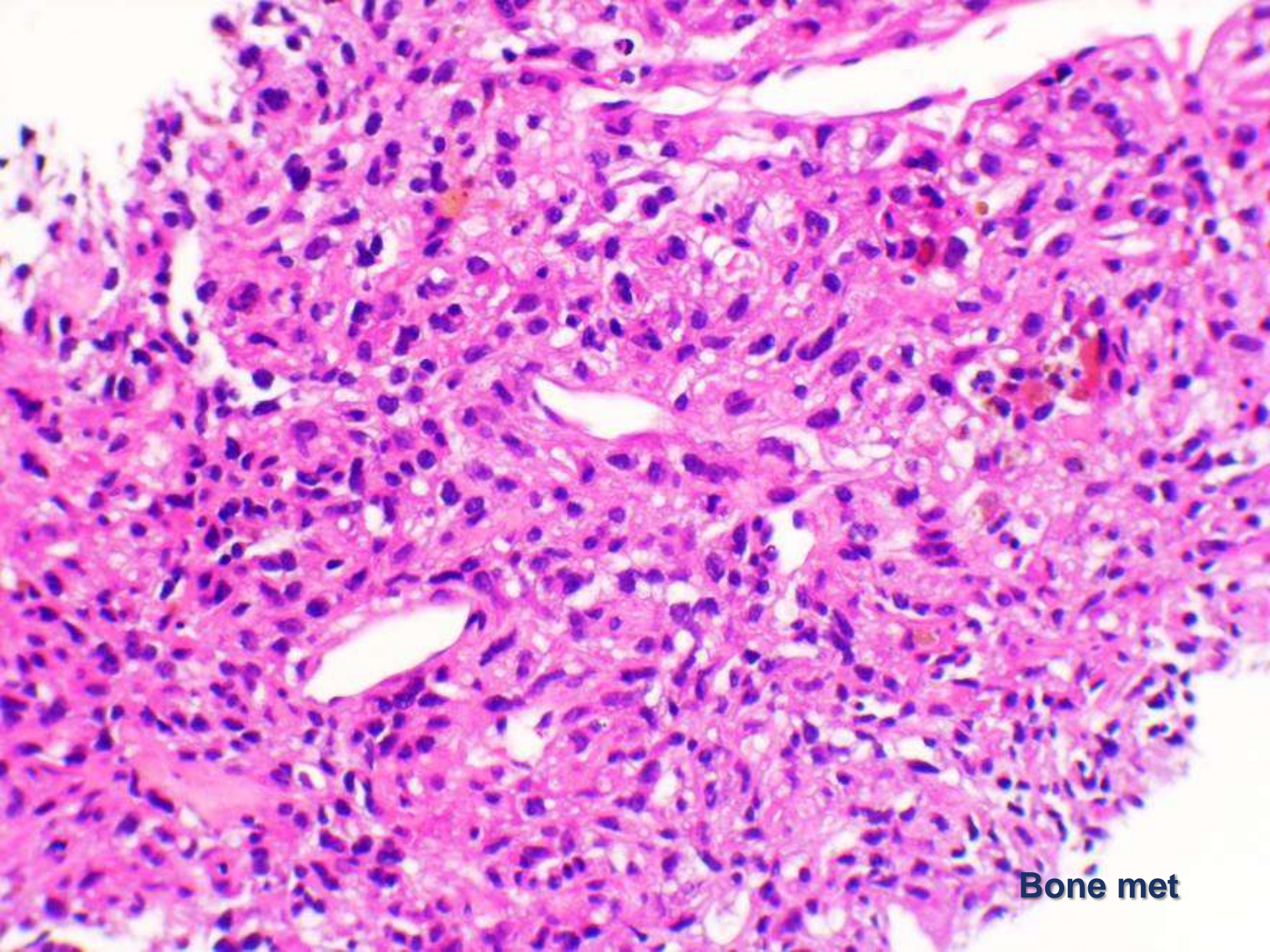
- The penetrance of the gene is often reported as 77% by age 50. The average age of onset is approximately the same for SDHB vs non-SDHB related disease (approximately 36 years).
- Paragangliomas caused by SDHB mutations have several distinguishing characteristics:
- Malignancy is common, ranging from 38%-83% in carriers with disease.
- Sporadic paragangliomas are malignant in less than 10% of cases.
- Malignant paragangliomas caused by SDHB are usually (perhaps 92%) extra-adrenal. Sporadic Pheo/PGL are extra-adrenal in less than 10% of cases.
- Mutations have been described in exons 1-7

# Renal Cancer in SDH

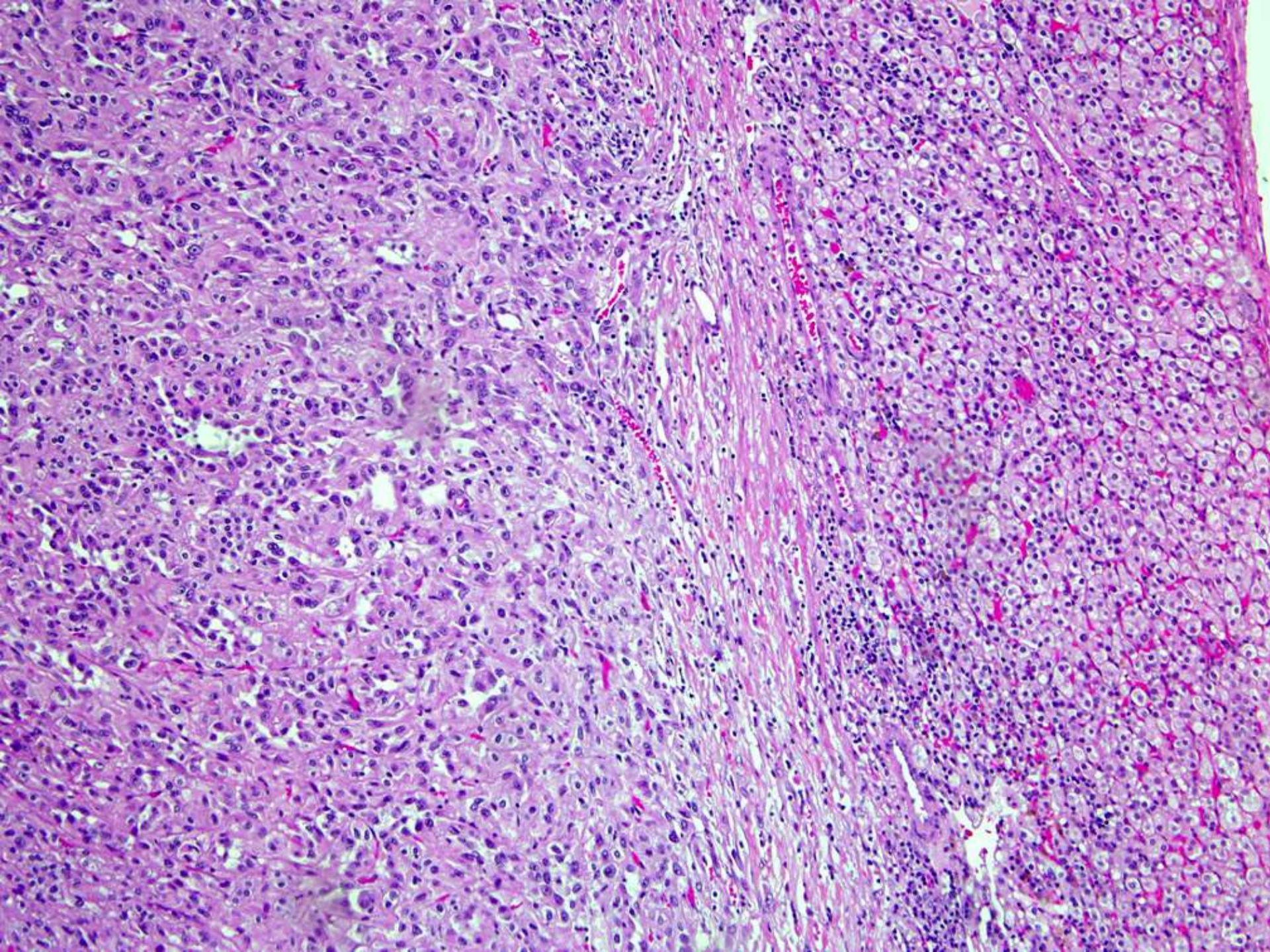
- Rarely recognized if no family history of PH/PGL is obtained.
- Few cases have been reported
- Solitary tumors, however bilateral tumors can rarely occur.
- Frequently diagnosed as Oncocytoma, chromophobe RCC or clear cell

<b>Family ID</b>	<b>KS Onset</b>	<b>Organ</b>	<b>Procedure</b>	<b>Pos Mutation</b>	<b>LOH 1p</b>
4042	61	Kidney	Left Biopsy	Yes	
4042	61	Kidney	Robotic Lap Left Partial Nephrectomy	Yes Ex 3	LOH
1527	52	Kidney	Left Total Nephrectomy	Yes Ex 7	
4046	19	Kidney	Robotic Lap Left Partial Nephrectomy	Yes Ex 5	LOH
4098	37	Kidney	Lap Right Radical Nephrectomy	Yes Ex 3	
4111	32	Kidney	Lap Left Radical Nephrectomy	Yes Ex 2	LOH
4181	27	Kidney	Robotic Lap Left Partial Nephrectomy	Yes Ex 1	LOH
4165	28	Kidney	Open Right Partial Nephrectomy	Yes Ex 6	
	42	Kidney	Left Partial Nephrectomy	Yes	LOH
	33	Kidney	Right Partial Nephrectomy	Yes	LOH
	59	Kidney	Lap Right Partial Nephrectomy	Being Done	LOH

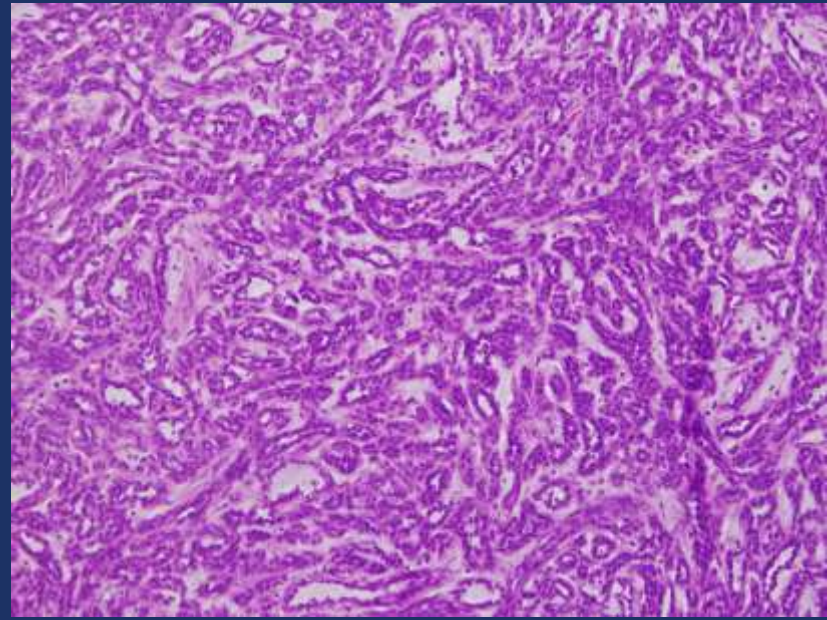
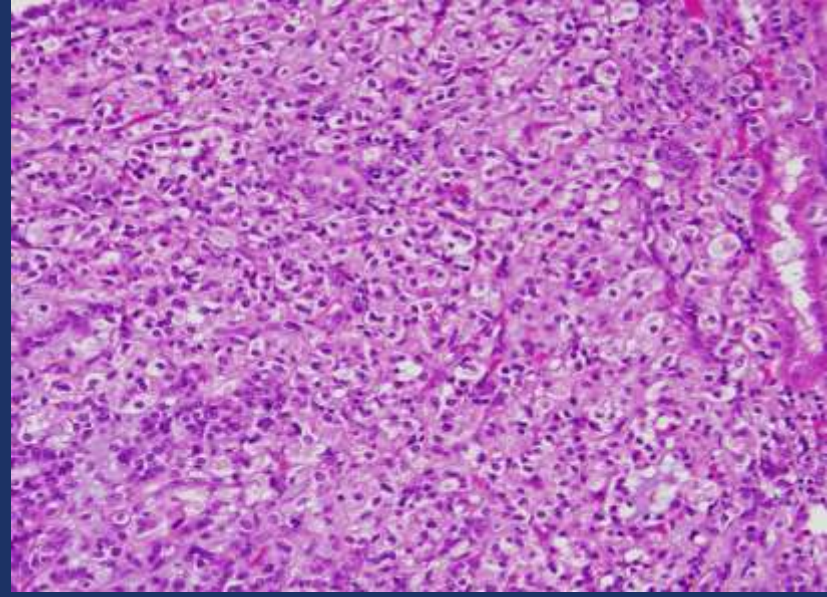
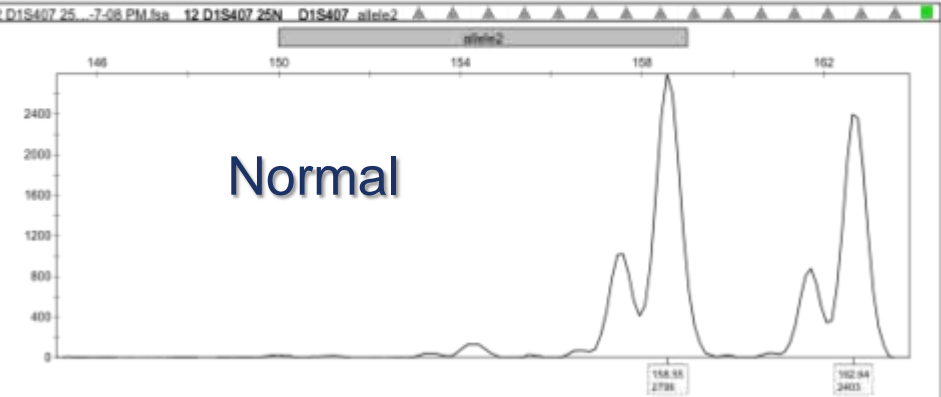
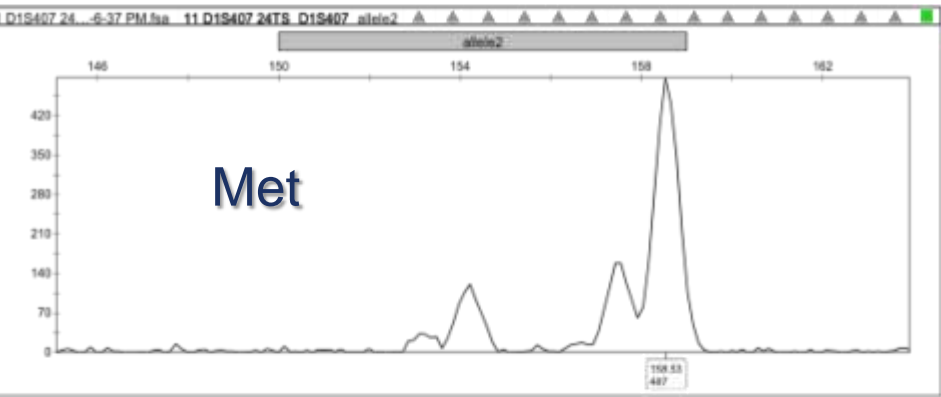
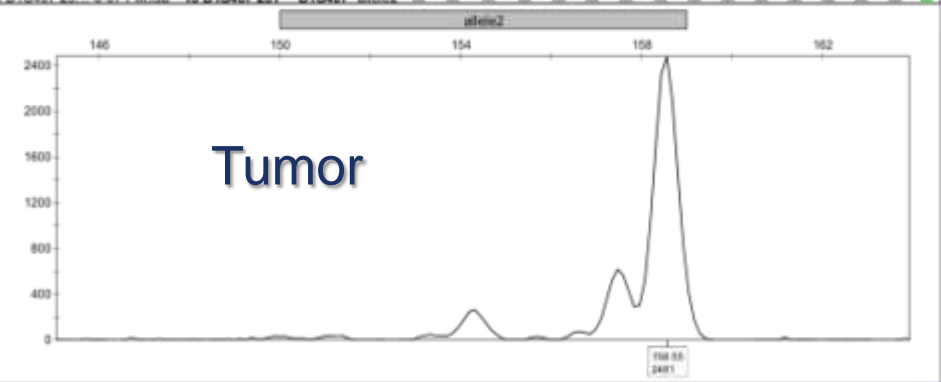




**Bone met**



Sample File	Sample Name	Panel	Marker	OS	SHP	OSA	SPA	SP	BN	PHR	LPH	SPU	AN	BD	DP	NR	CC	OVL	GO
-------------	-------------	-------	--------	----	-----	-----	-----	----	----	-----	-----	-----	----	----	----	----	----	-----	----

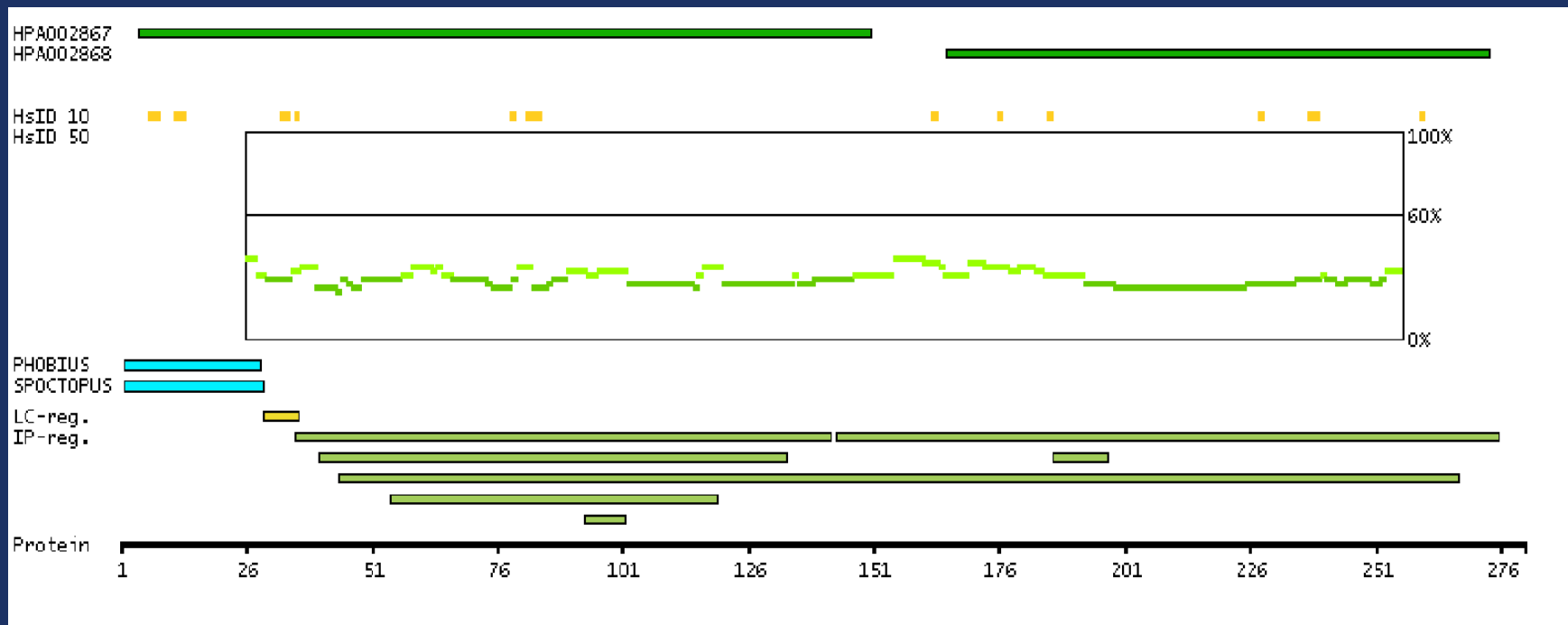
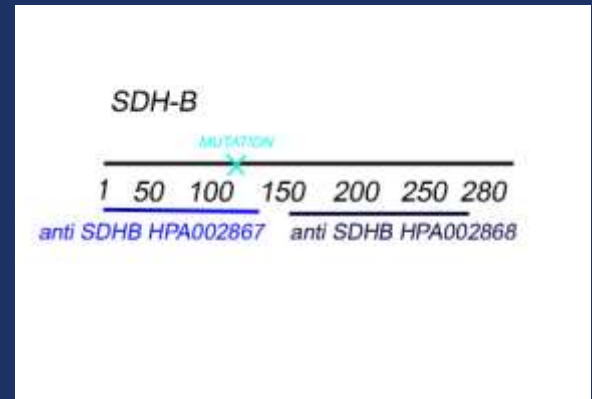


1p35

# IHC SDHB protein

HPA002867 antibody

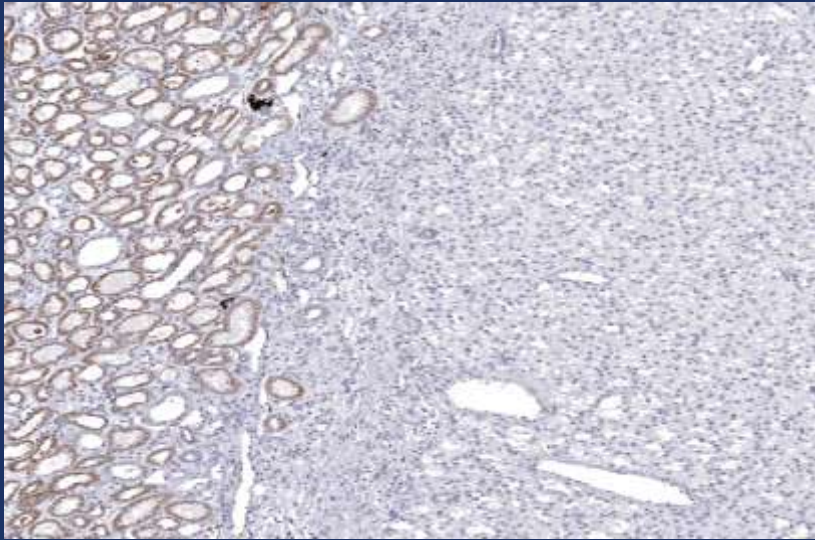
HPA002868 antibody



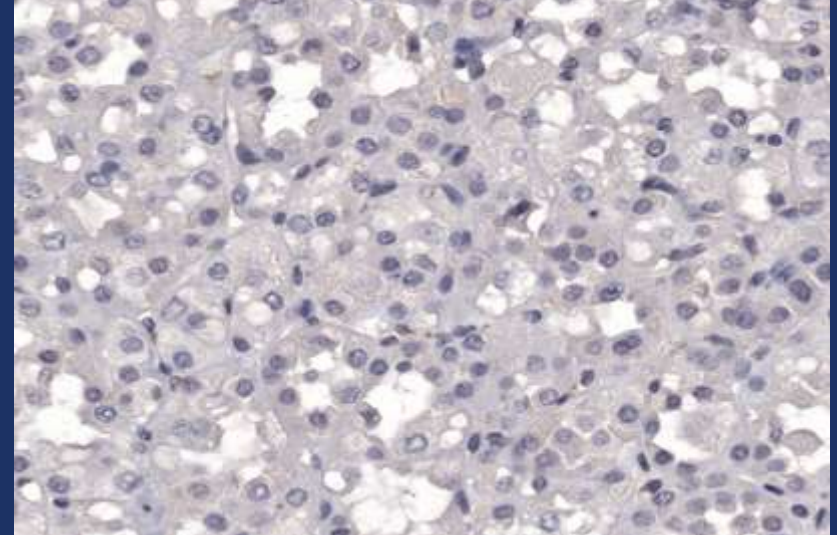
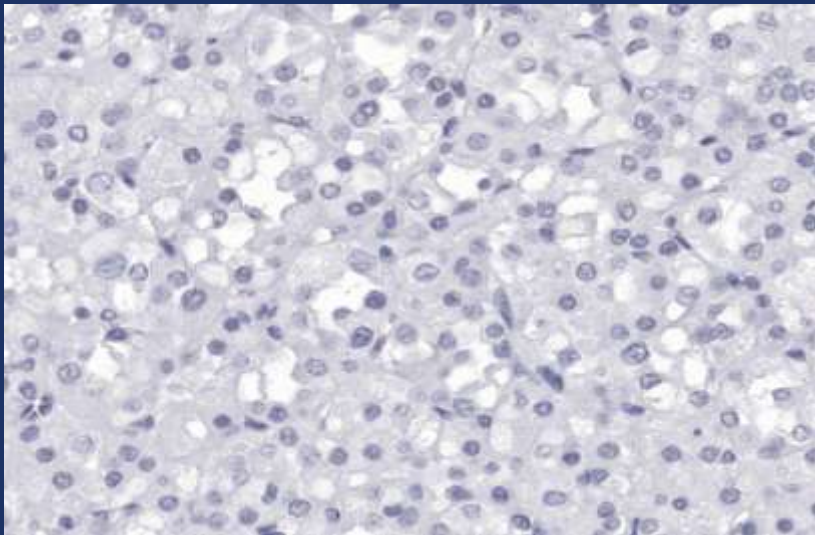
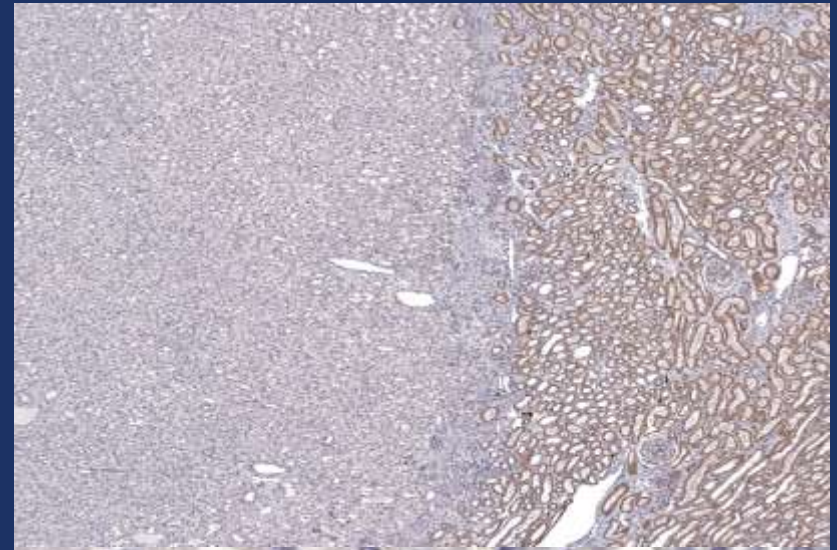


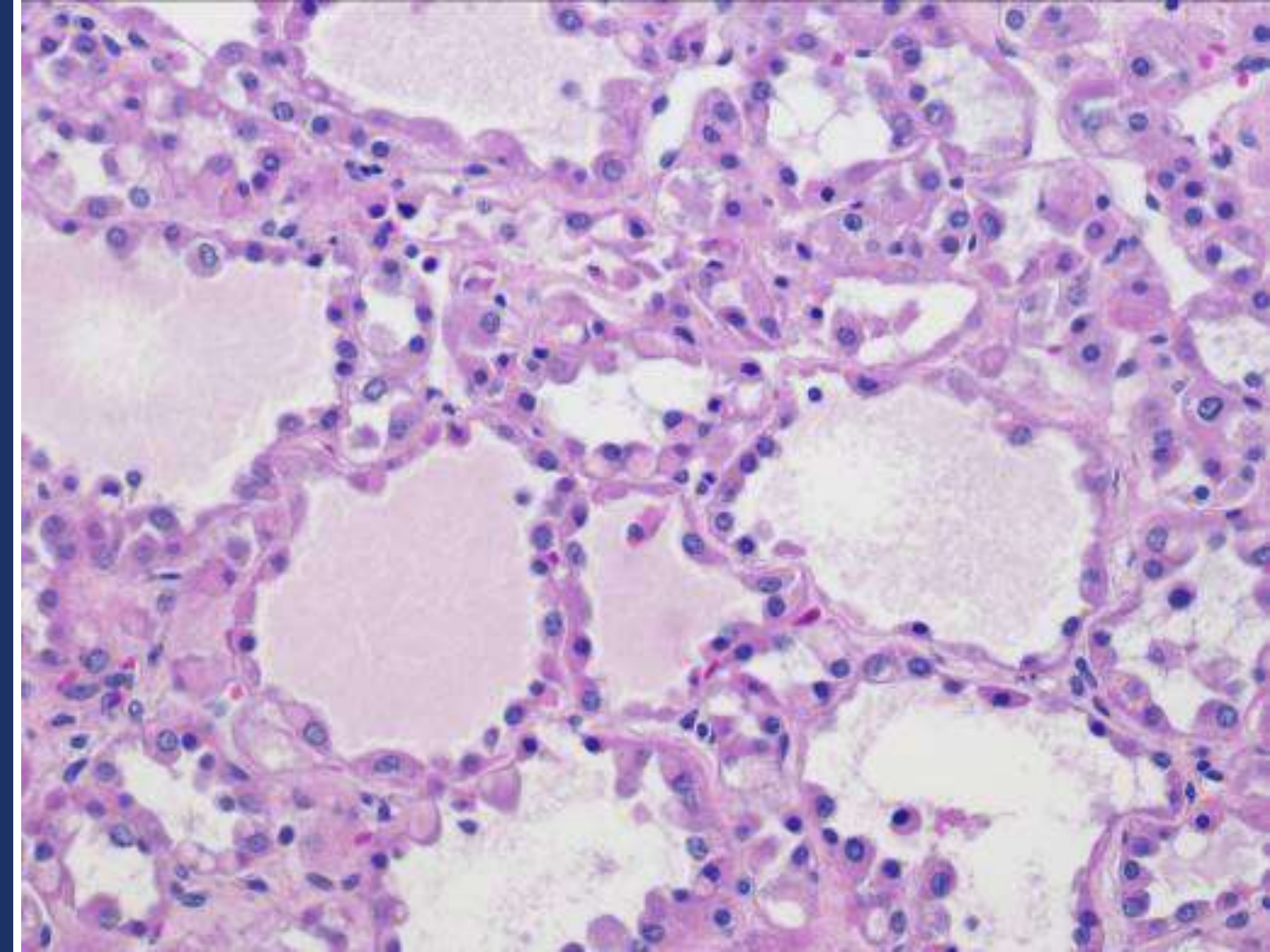
# SDHB protein expression in SDHB tumors

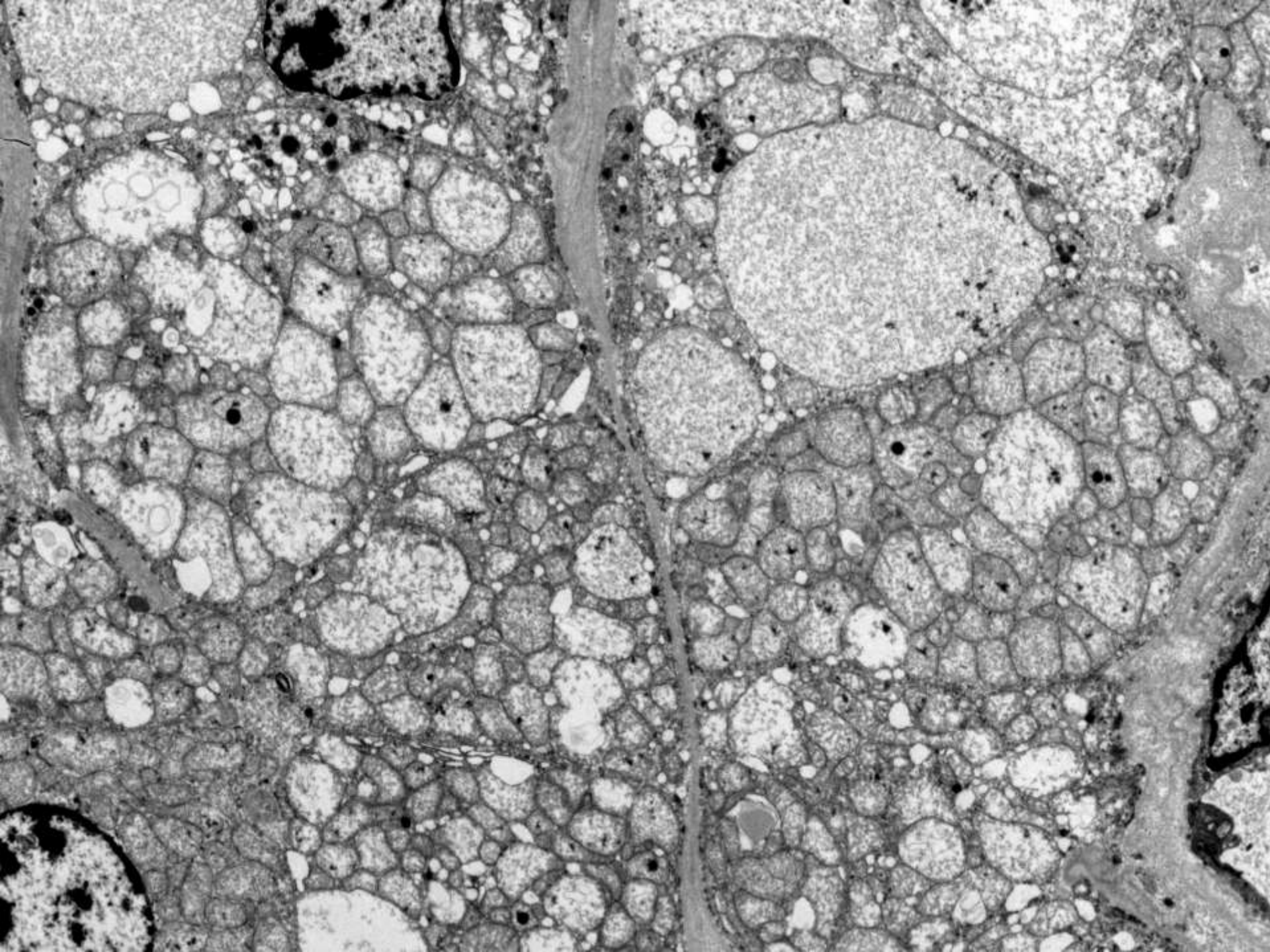
HPA002867



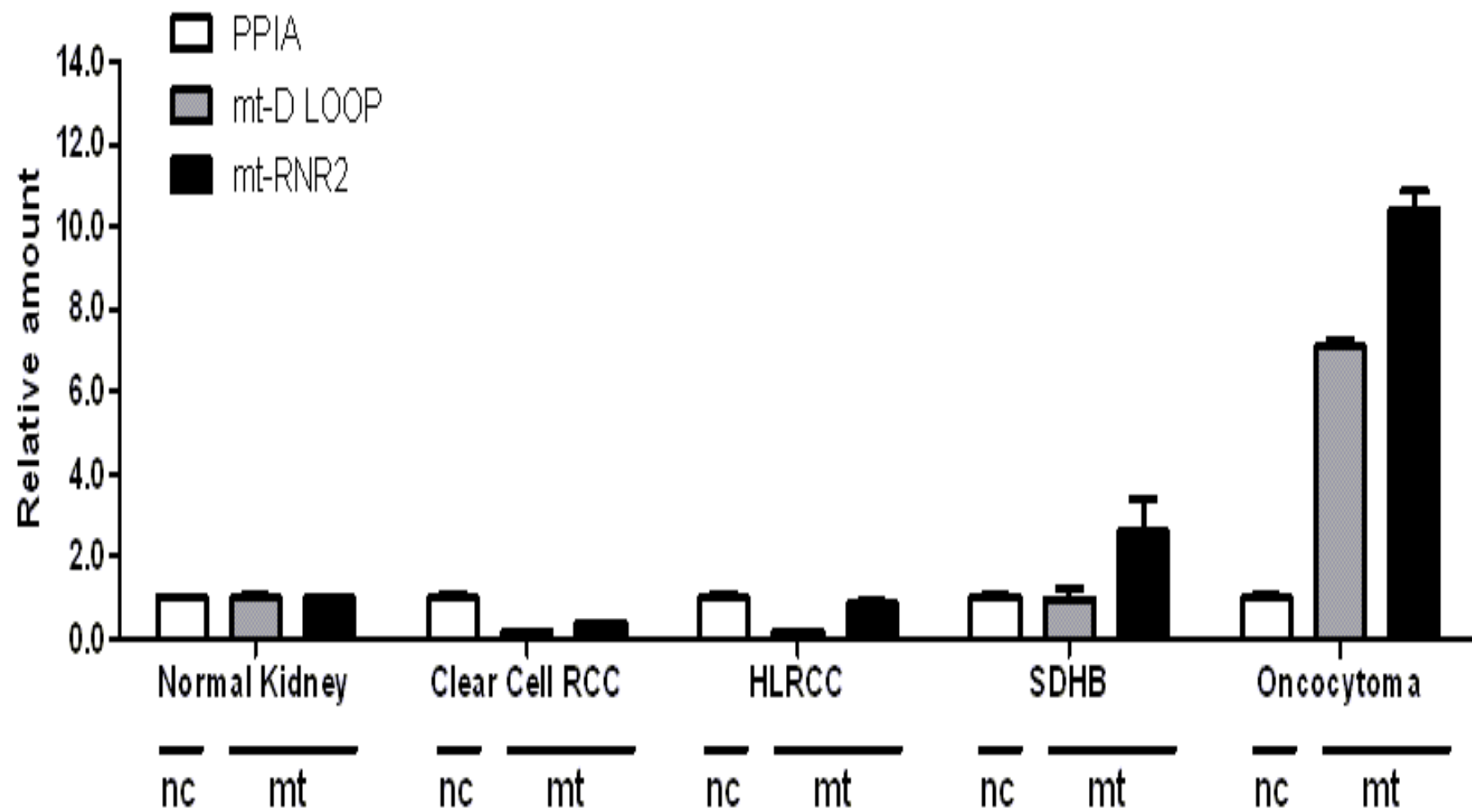
HPA002868





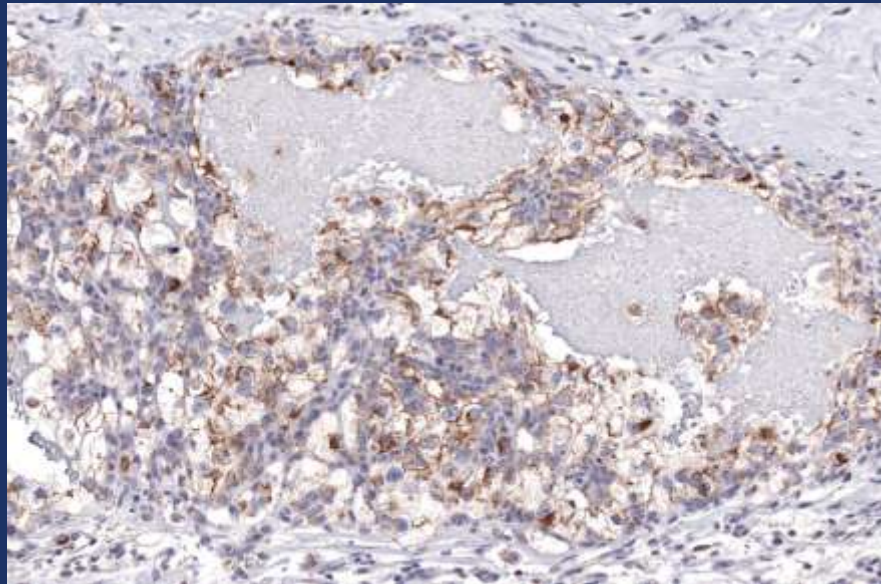



## All histologies

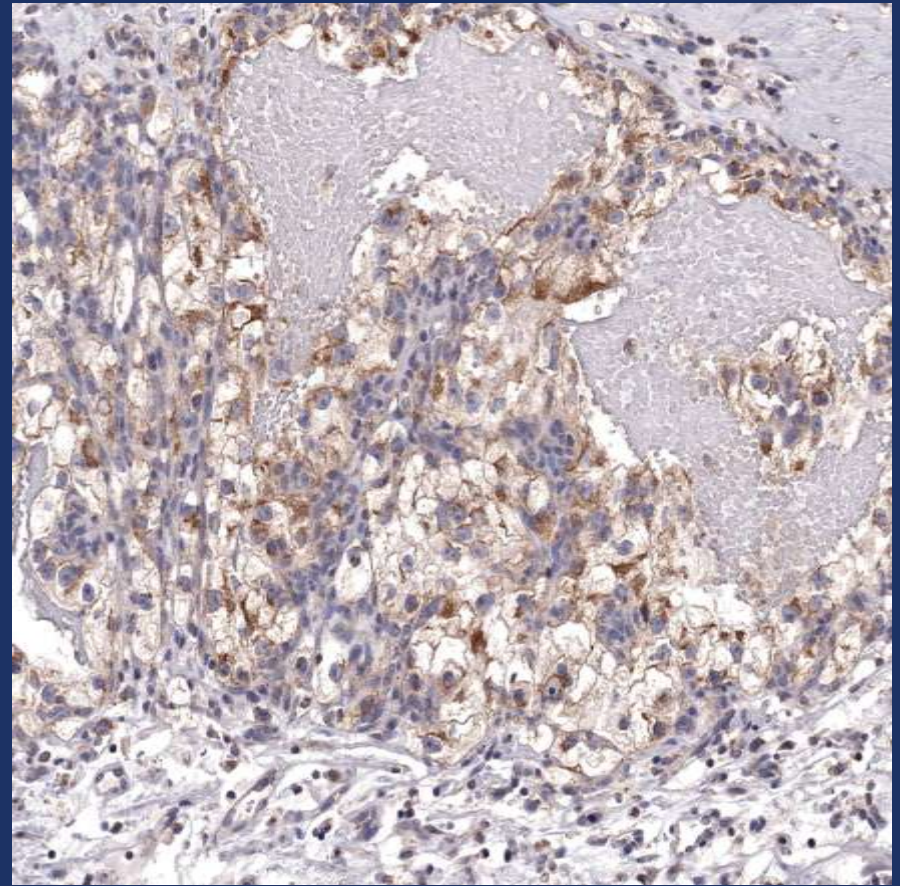


Age at Presentation	Gender	History of PGL/Pheo	
		Personal	Familial
52	Female	No	No
49	Female	No	No
43	Female	No	No
52	Female	No	No
46	Male	No	No
48.4	= Average age at presentation for NCI-UOB SDHC families (years)		
39.3	= Average age at presentation for all SDHB/C families (years)		

■ Case 7 SDH-C



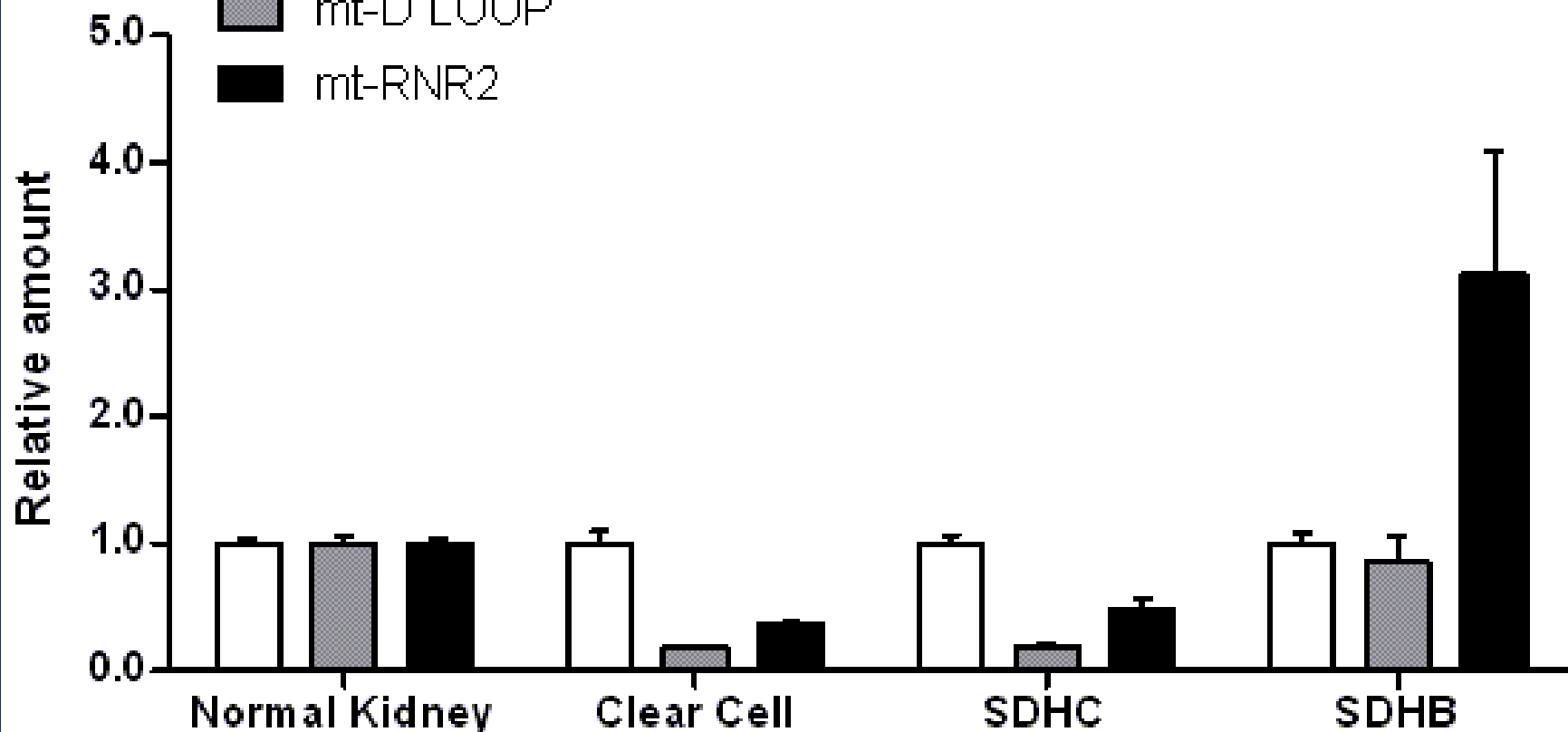
**HPA002867**



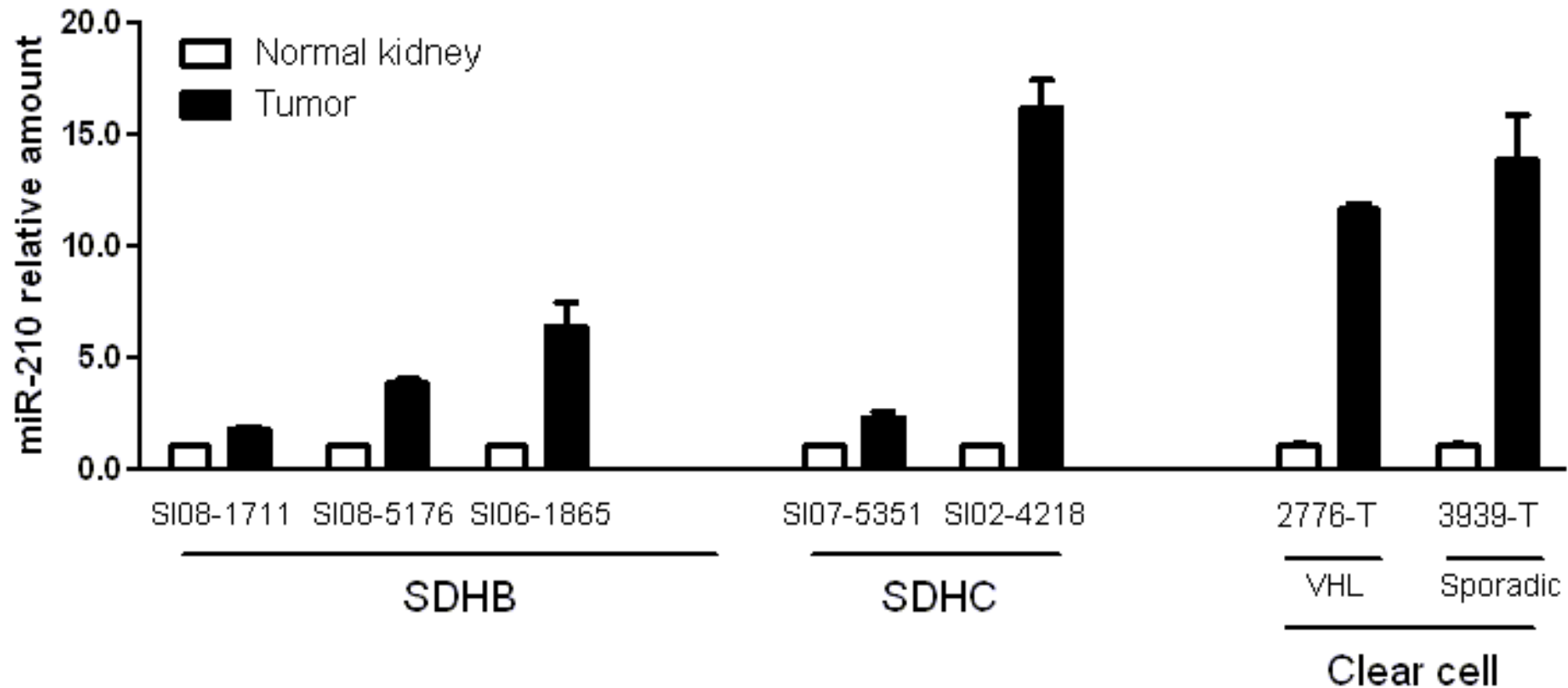
**HPA002868**

## Clear cell RCC and SDHC showed similar mt-DNA content

- PPIA
- ▨ mt-D LOOP
- mt-RNR2



## miR-210 expression in SDHB and SDHC kidney tumors



- miR-210 is part of the hypoxic phenotype in clear cell RCC. .
- High levels of miR-210 are correlated with adverse prognostic factors such as high FNG and the presence of LN metastasis.
- miR-210 could be used as a biomarker for the evaluation of tumor hypoxia in renal cell carcinomas.



# Conclusions

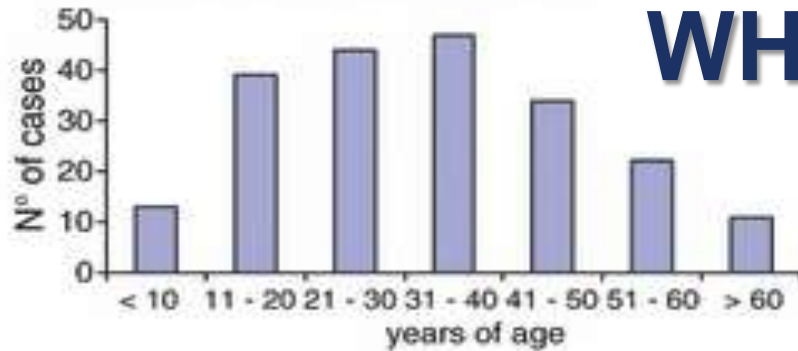
- Renal cancer is part of the SDH syndrome
- Characteristic morphologic features
- Molecular profile different from other tumors with Oncocytic features
- SDHB and SDHC tumors are morphologically different
- Patients may not have other lesions or give family history
- Pathologists need to be aware of this tumor so proper screening and follow up of families is established.

***PHENOTYPE PRECEDES GENOTYPE***

**(a)**  
**SDHB**

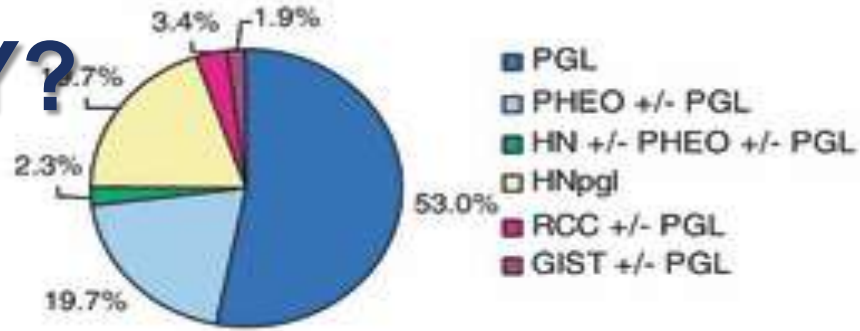
Age at diagnosis of the first tumour  
in 210 *SDHB* affected carriers

Range: 7-76  
Median: 32  
Mean: 33.3  
years of age



WHY?

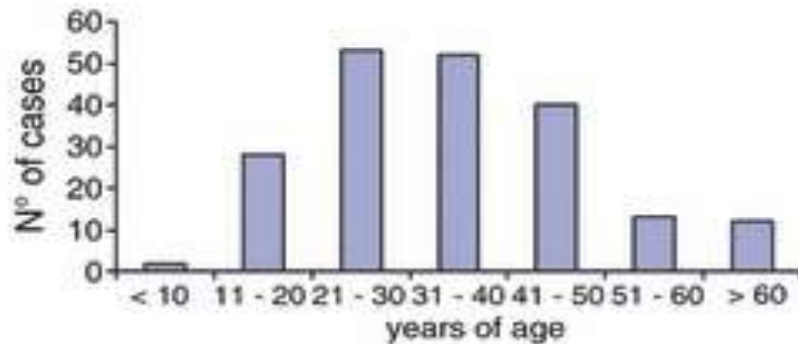
Phenotype of 264 *SDHB* affected carriers



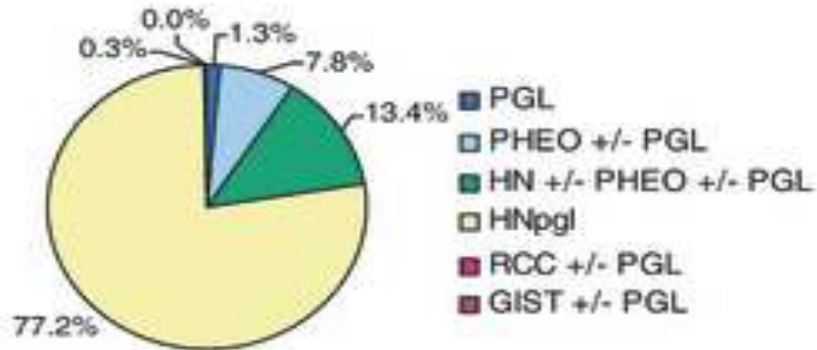
**(b)**  
**SDHD**

Age at diagnosis of the first tumour  
in 200 *SDHD* affected carriers

Range: 5-73  
Median: 33  
Mean: 34.9  
years of age



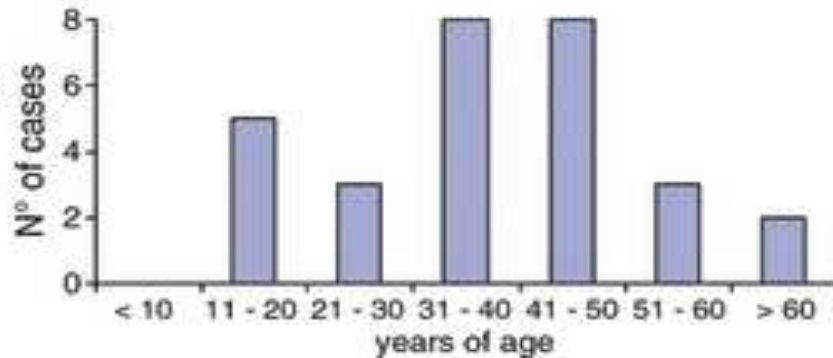
Phenotype of 395 *SDHD* affected carriers



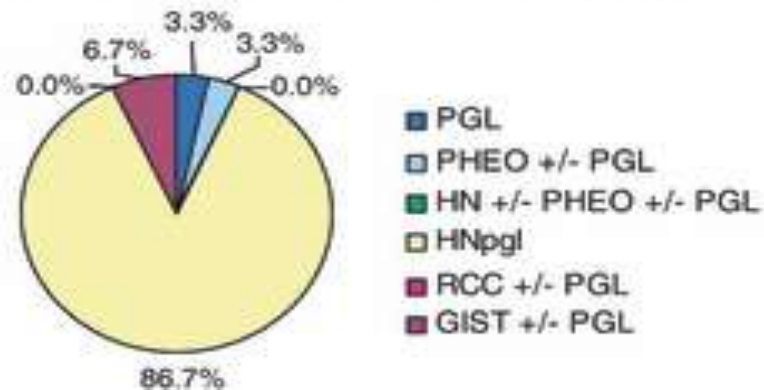
**(c)**  
**SDHC**

Age at diagnosis of the first tumour  
in 29 *SDHC* affected carriers

Range: 13-73  
Median: 38  
Mean: 38.8  
years of age



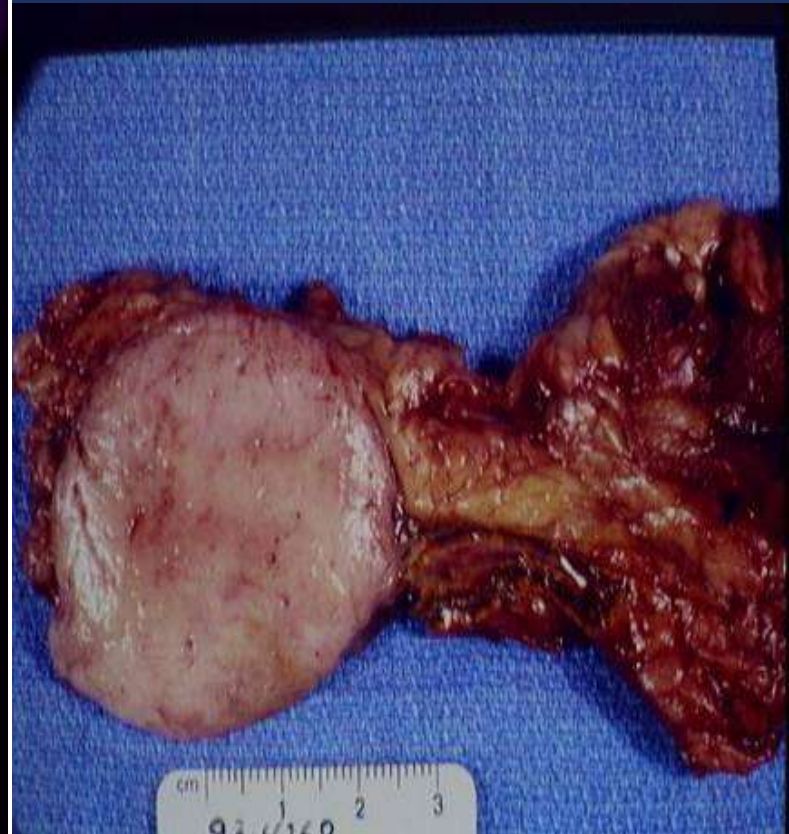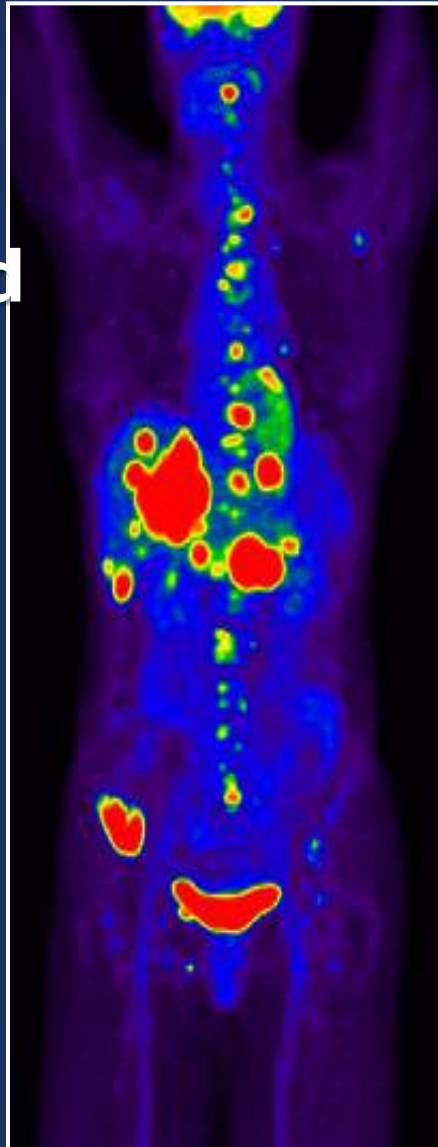
Phenotype of 30 *SDHC* affected carriers



# Follow up

Patient is alive and well

Son was screened



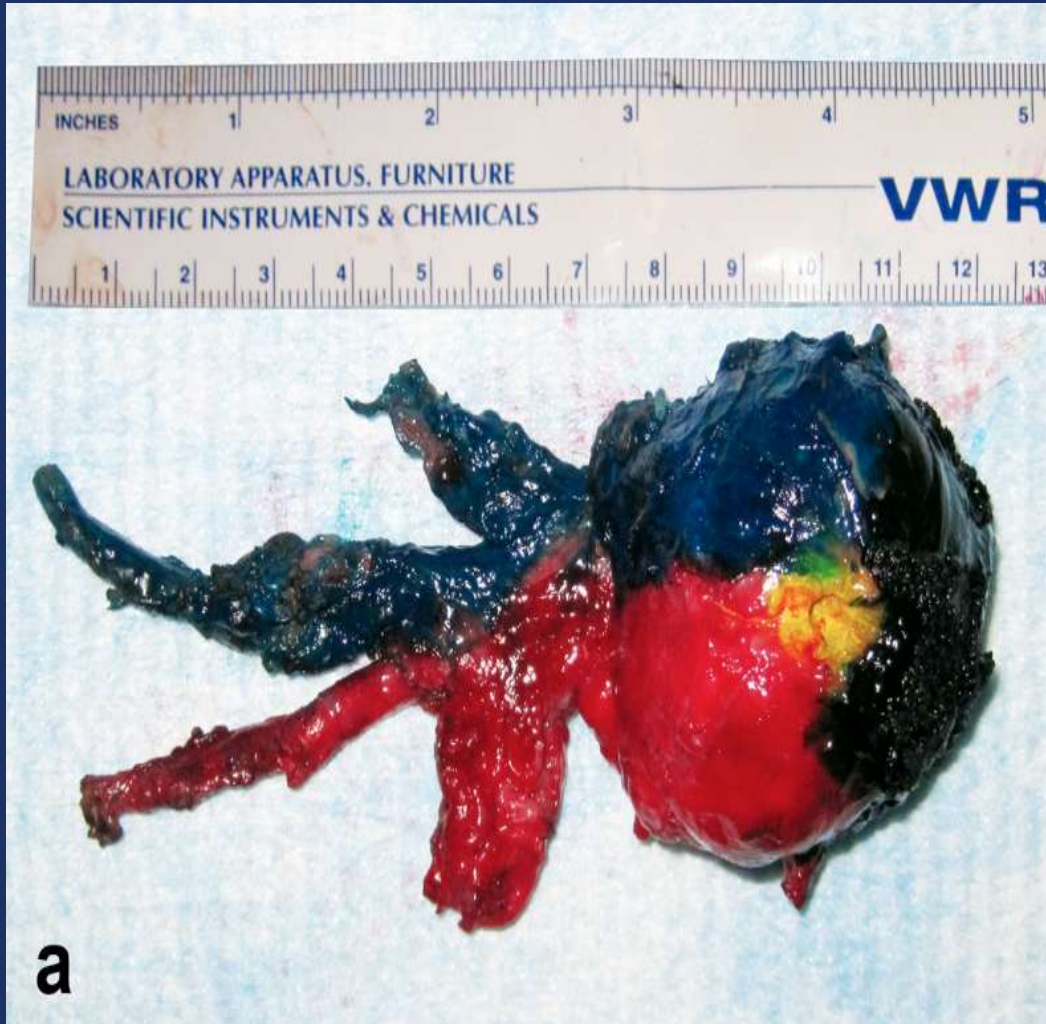# A Step towards Personalized Pathology:

## Use of a Patient-Specific MRI-based Prostate Mold for Validation of Multi-parametric MRI in Localization of Prostate Ca

- Prostate cancer is the second most common cancer in men as well as the second most common cause of cancer death (after lung cancer).
- In 2010, it is estimated that there will be 217,730 new cases and 33,000 deaths.
- ↑ PSA leads to prostate biopsy in the same stereotypical fashion in all patients.
- Biopsy may yield negative results even in the presence of cancer

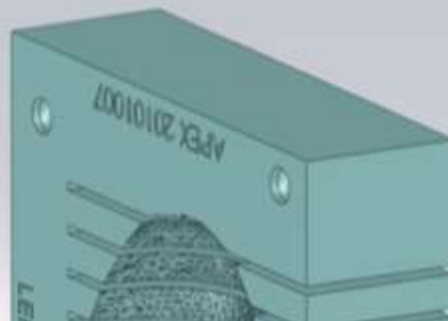
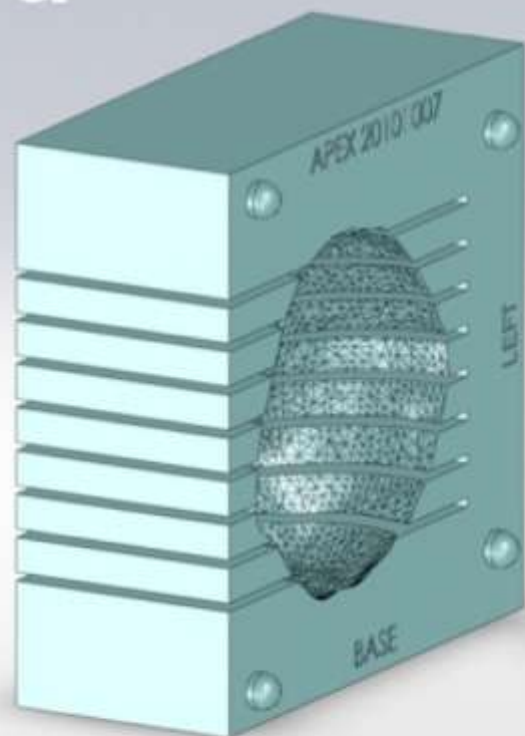
- Advanced imaging techniques, primarily magnetic resonance imaging (MRI) have the potential to allow more accurate tumor localization, enabling image-guided targeted biopsies and improve diagnosis
- Improve techniques in processing of prostate will enables reliable reporting of the accuracy of multiparametric MRI for localization of prostate cancer

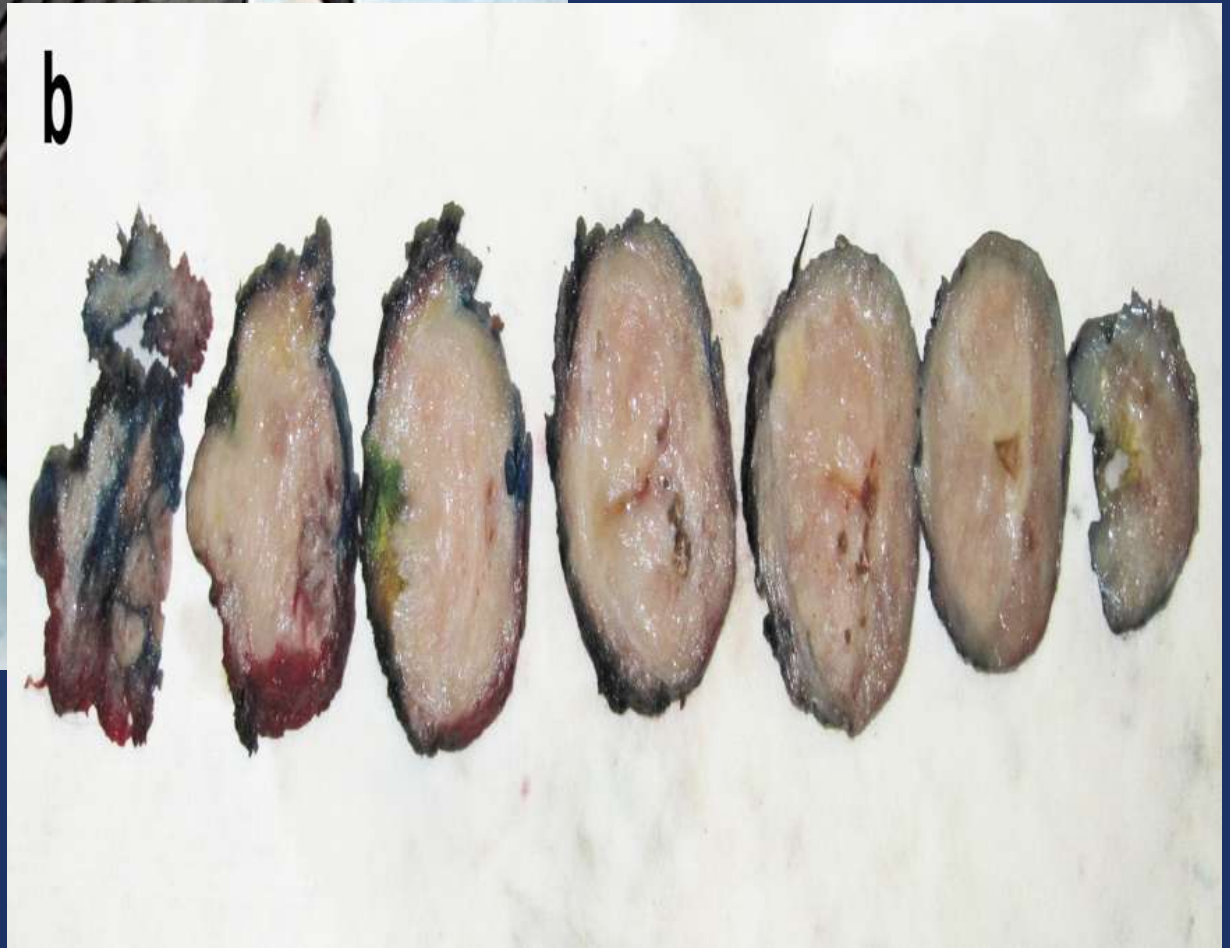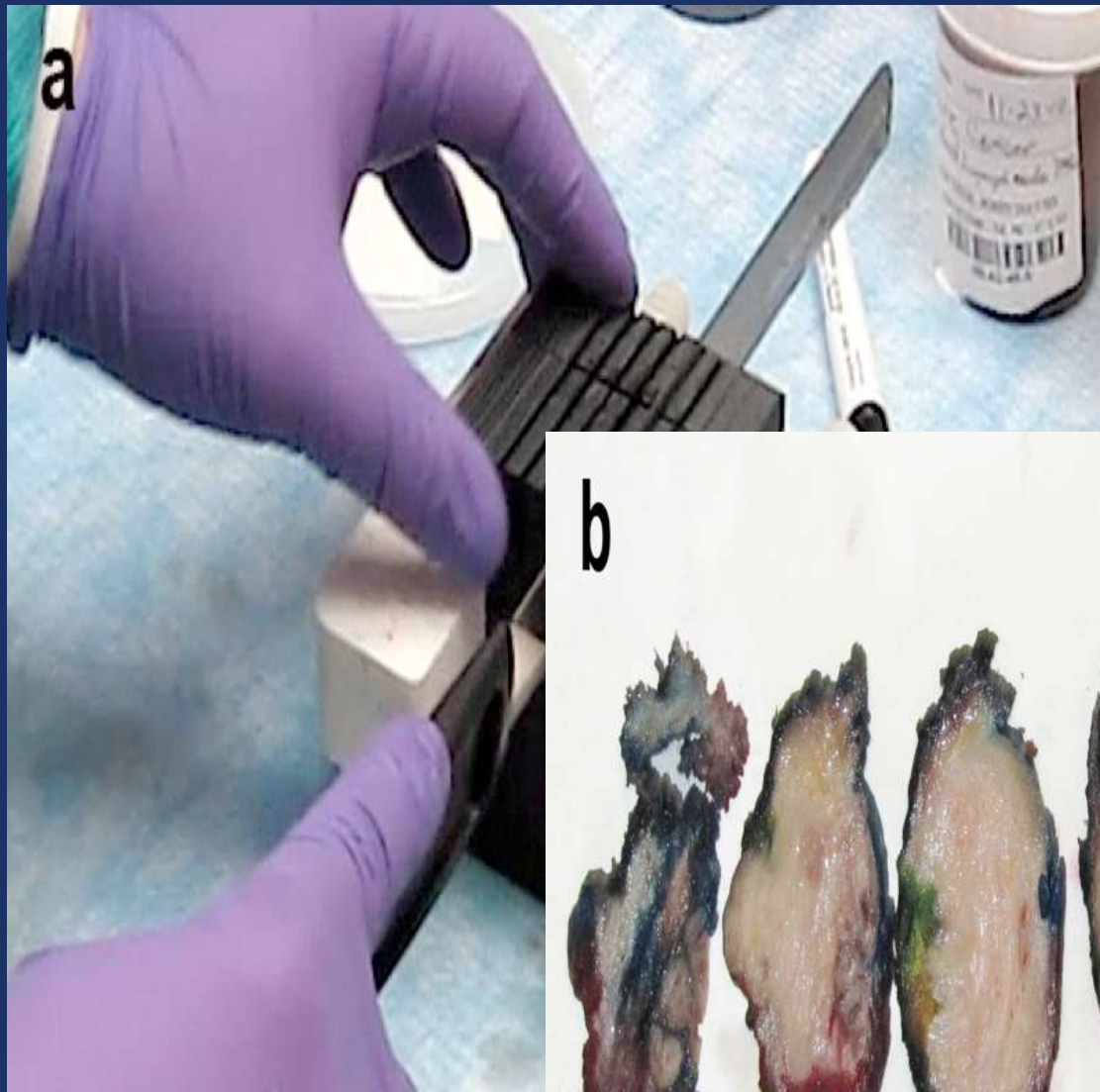
# Prostate Cancer



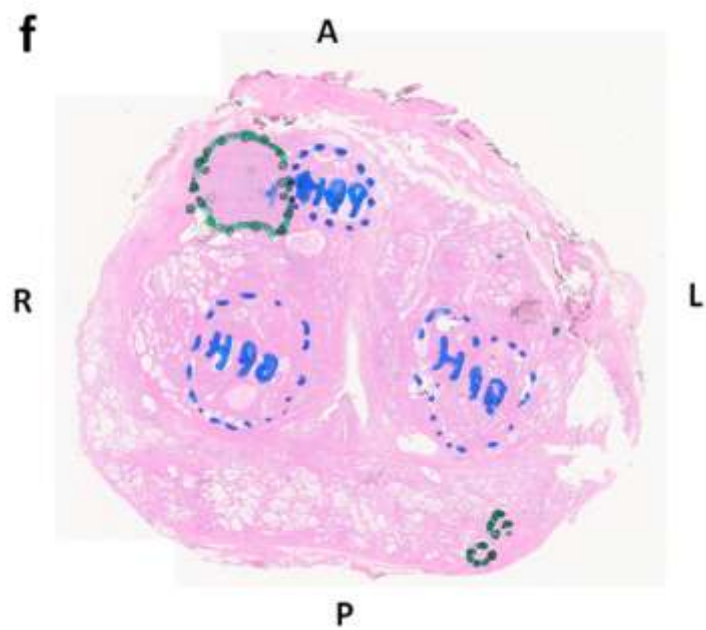
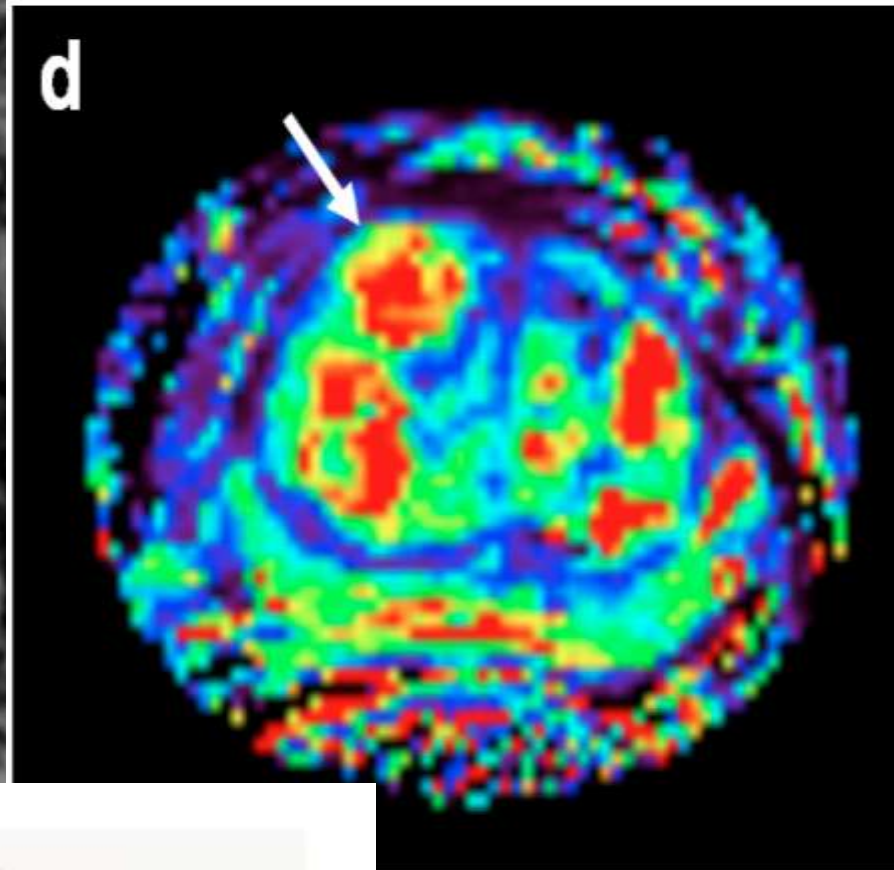
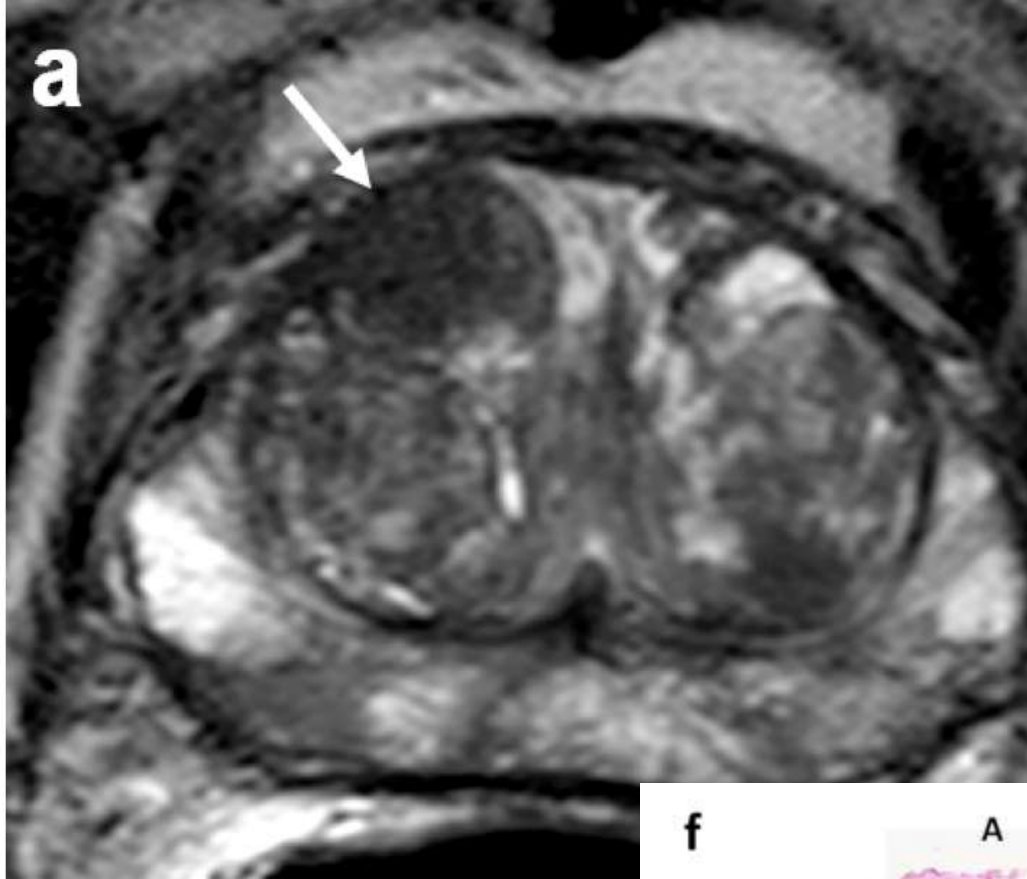
- Problems:
- Processing
- Sampling

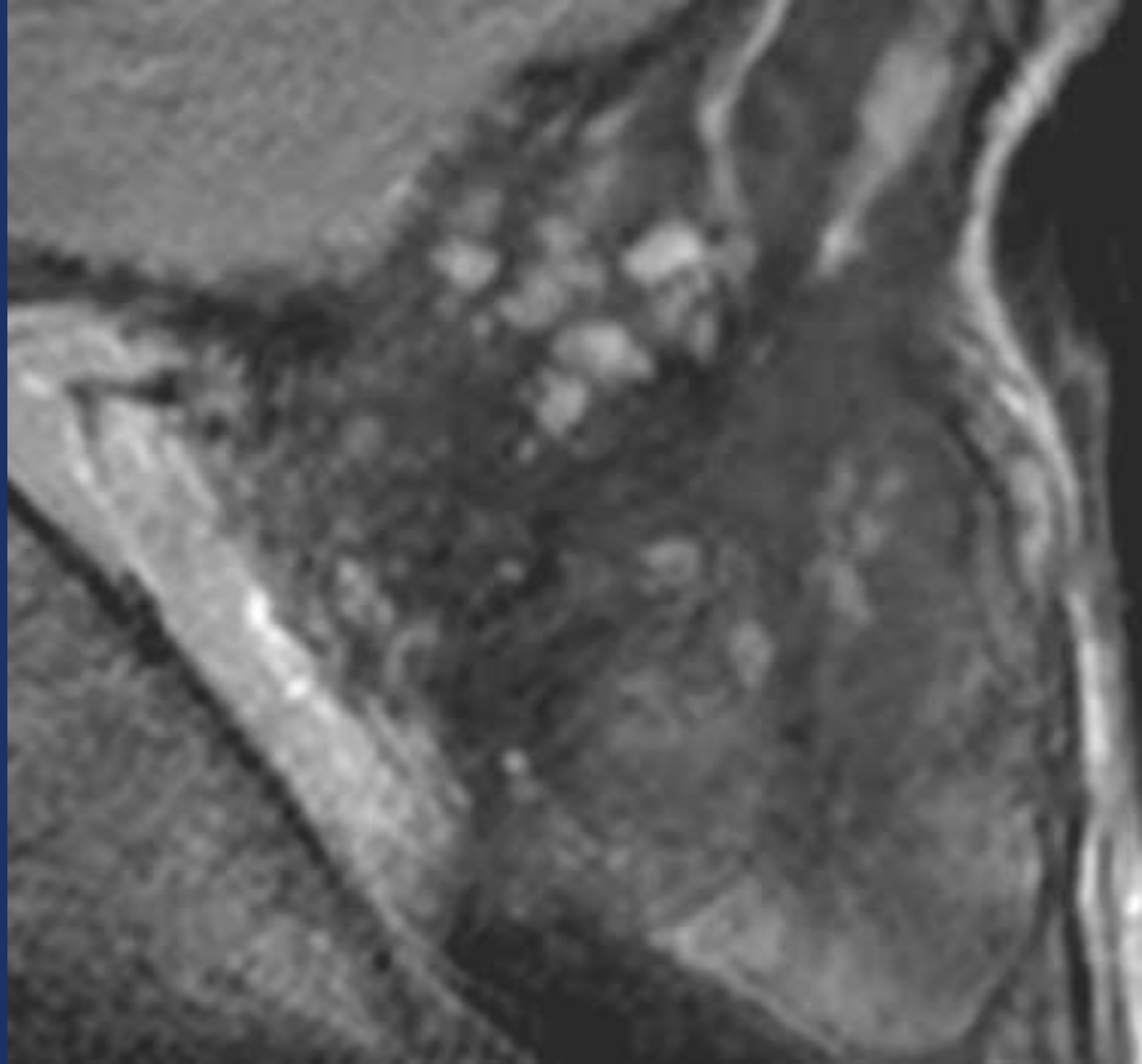
a

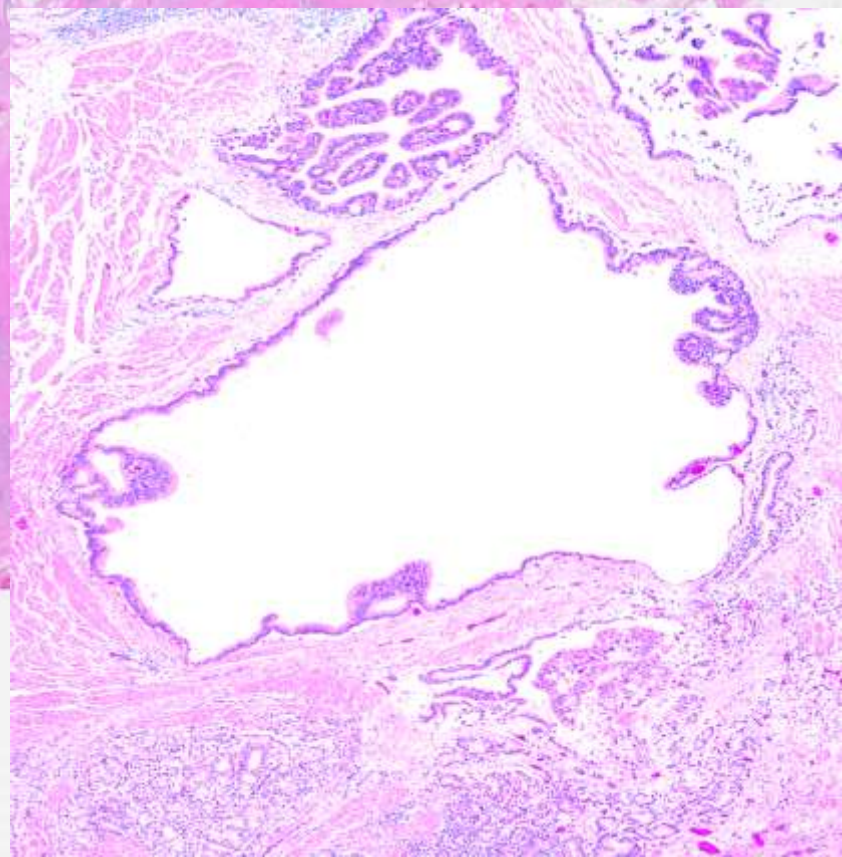
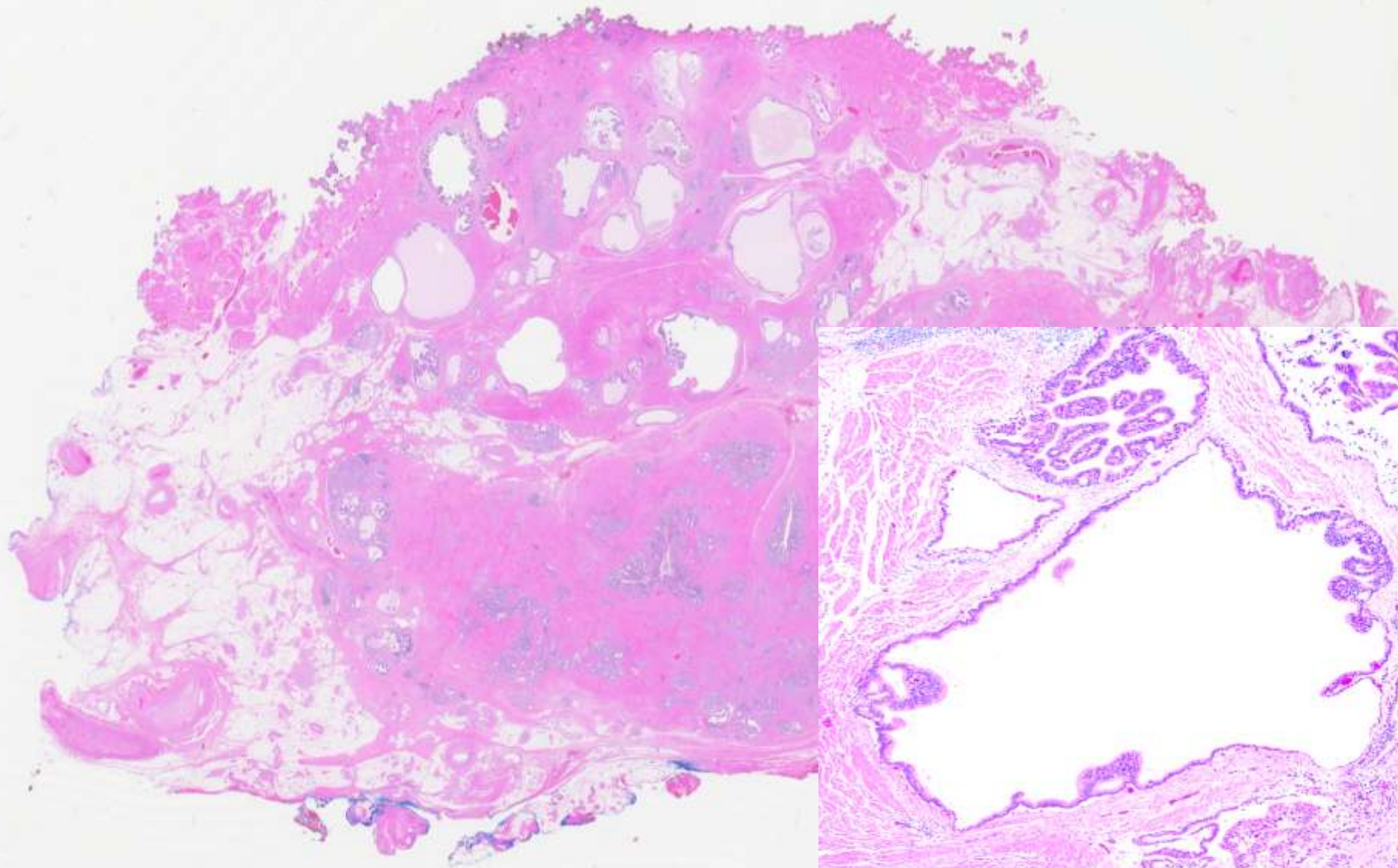


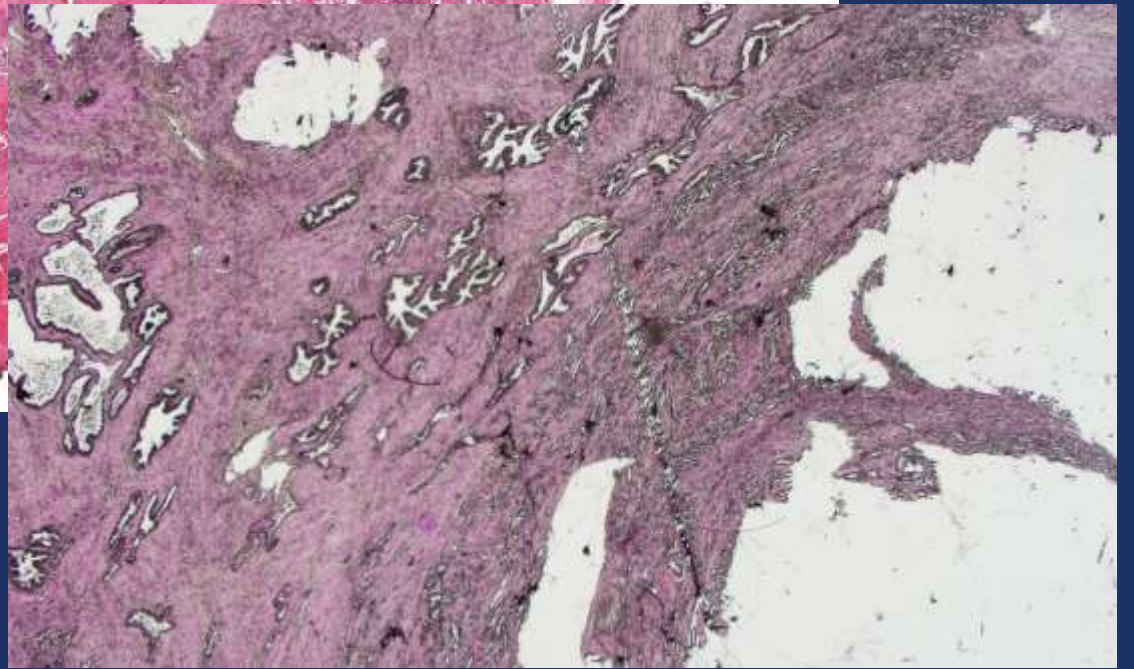
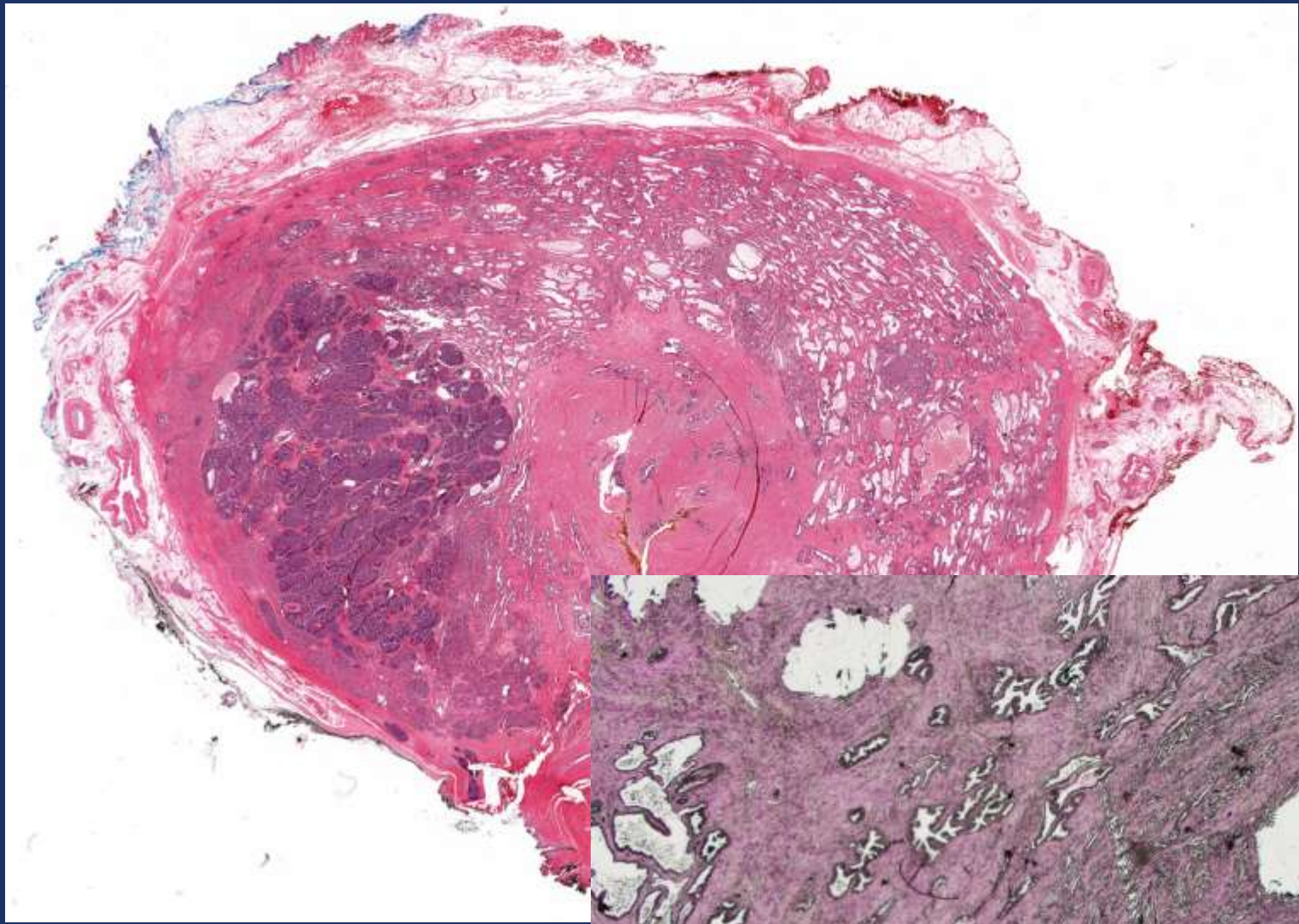


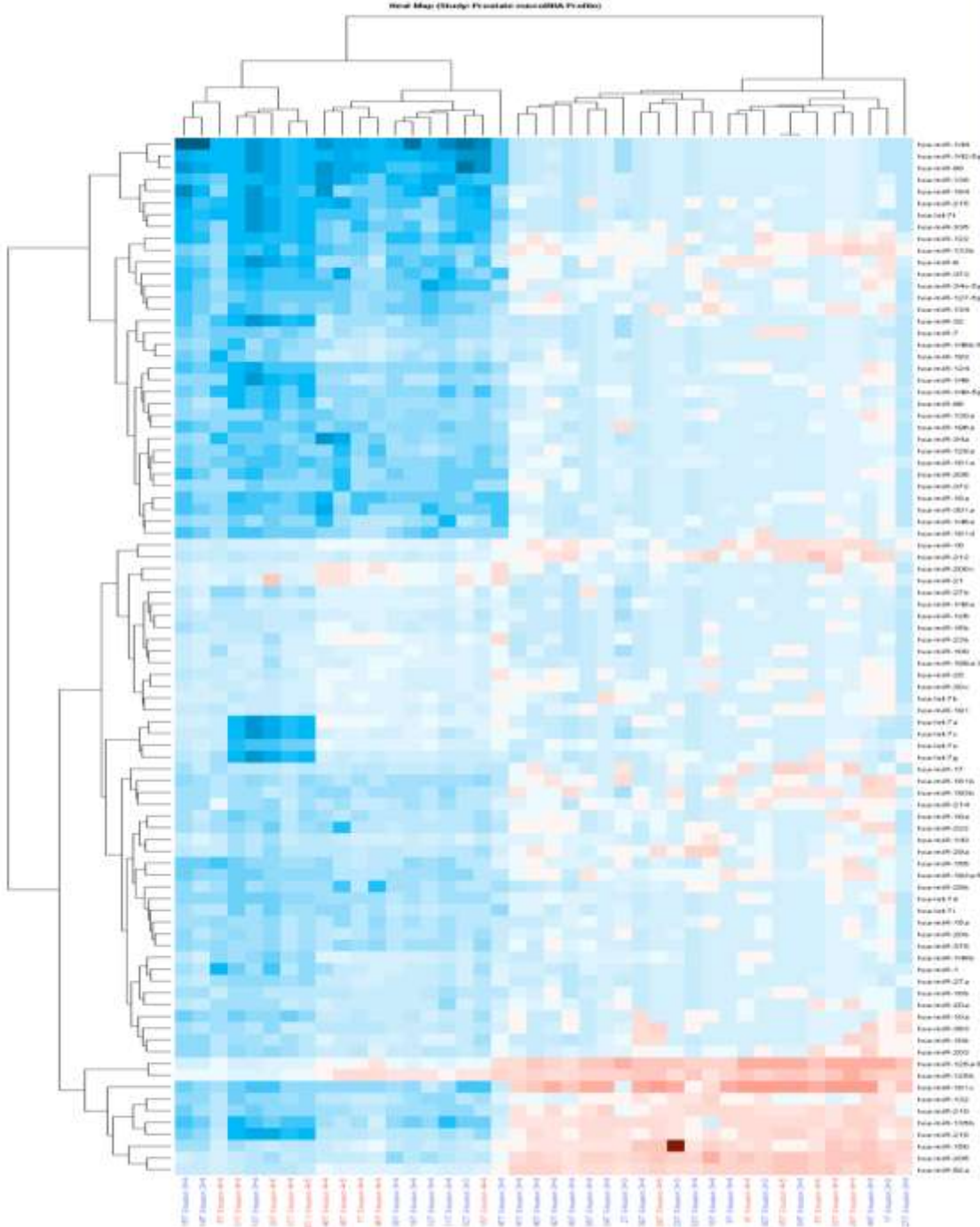








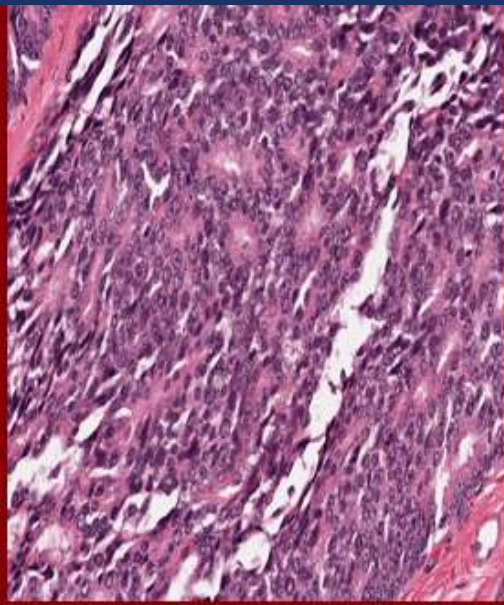
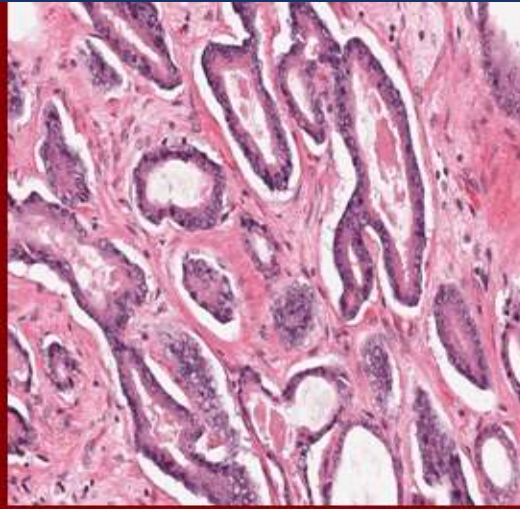




**Table 2.** Highly expressed microRNAs (all tumors vs. normal) and target genes.

miRNA	Target gene
17	E2F1,TSP1/THBS1,PTEN,BIM/BCL211,RB2/RBL2,p21/CDKN1A
150	NOTCH3
205	SIP1/ZEB2,ZEB1,Cepsilon
210	ISCU1/2,HIF
218	LASP1
125a	ERBB2
125b	HER2,HER3,EIF4EBP1,BAK1
135b	MSH2
181c	NOTCH4,KRAS
193b	ER $\alpha$ ,AKR1C2
92a	ISCU1/2,HIF

# microRNAs highly expressed in:



---

Low grade tumors (Gleason score  $\leq 7$ )  
vs. normal

---


125a  
125b  
205  
181c  
150  
92a

---

High grade tumors (Gleason score  $\geq 8$ )  
vs. normal

---

135b  
17  
193b  
181c  
218  
210



**Gracias**

