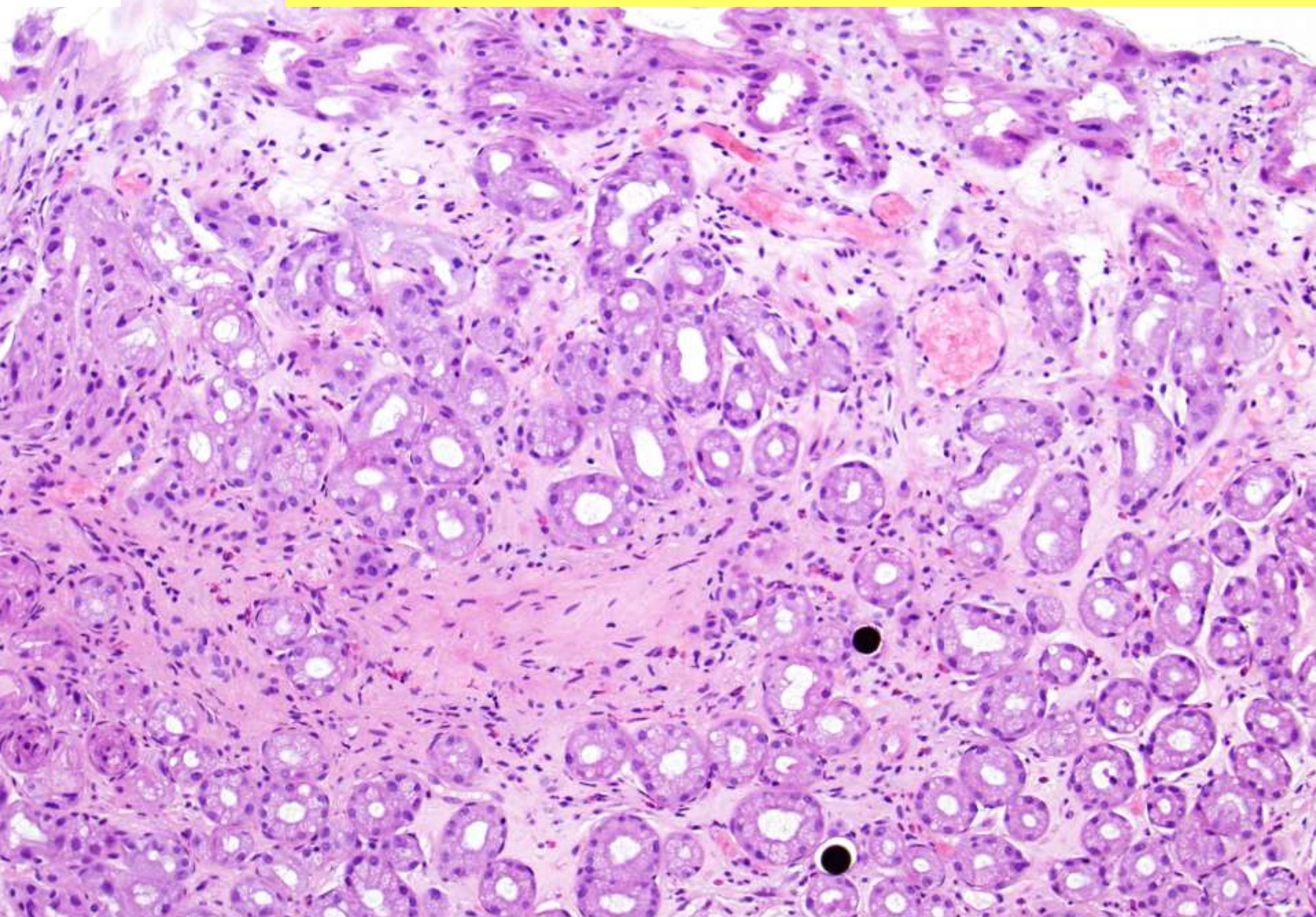


SLIDE SEMINAR – INSTANT DIAGNOSIS

John K.C. Chan

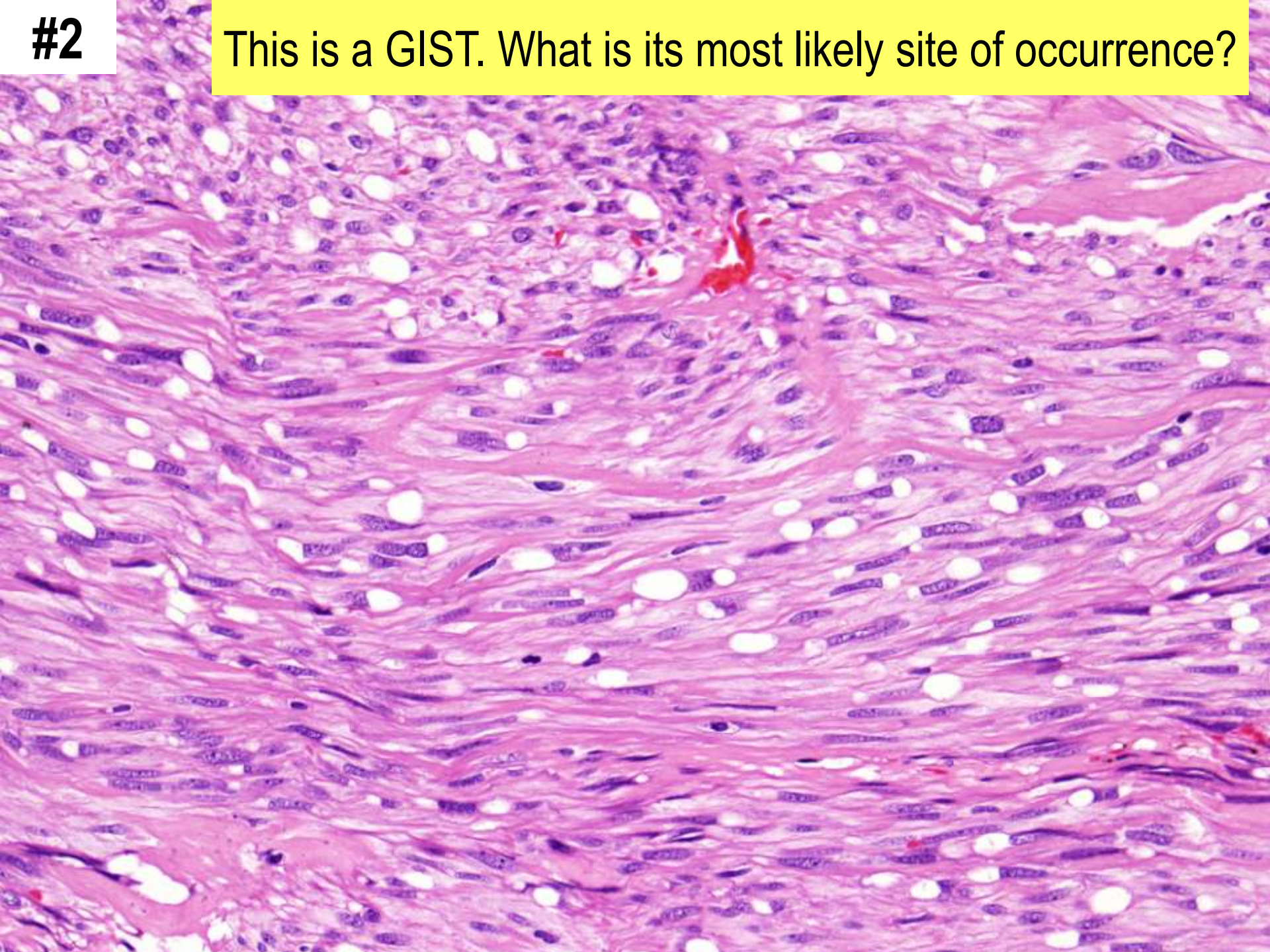#1

Gastric biopsy. What are these blue round structures?



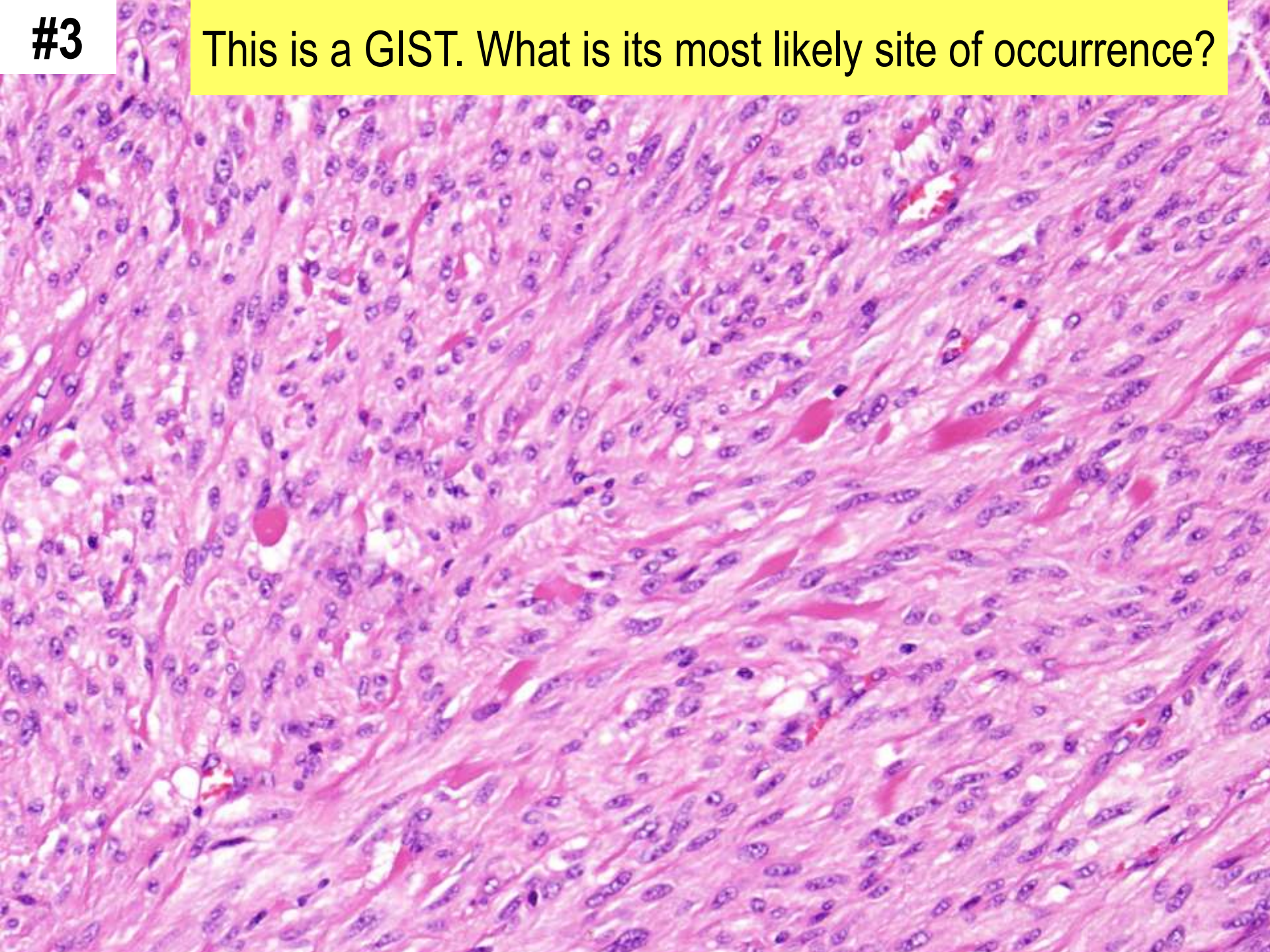
#2

This is a GIST. What is its most likely site of occurrence?



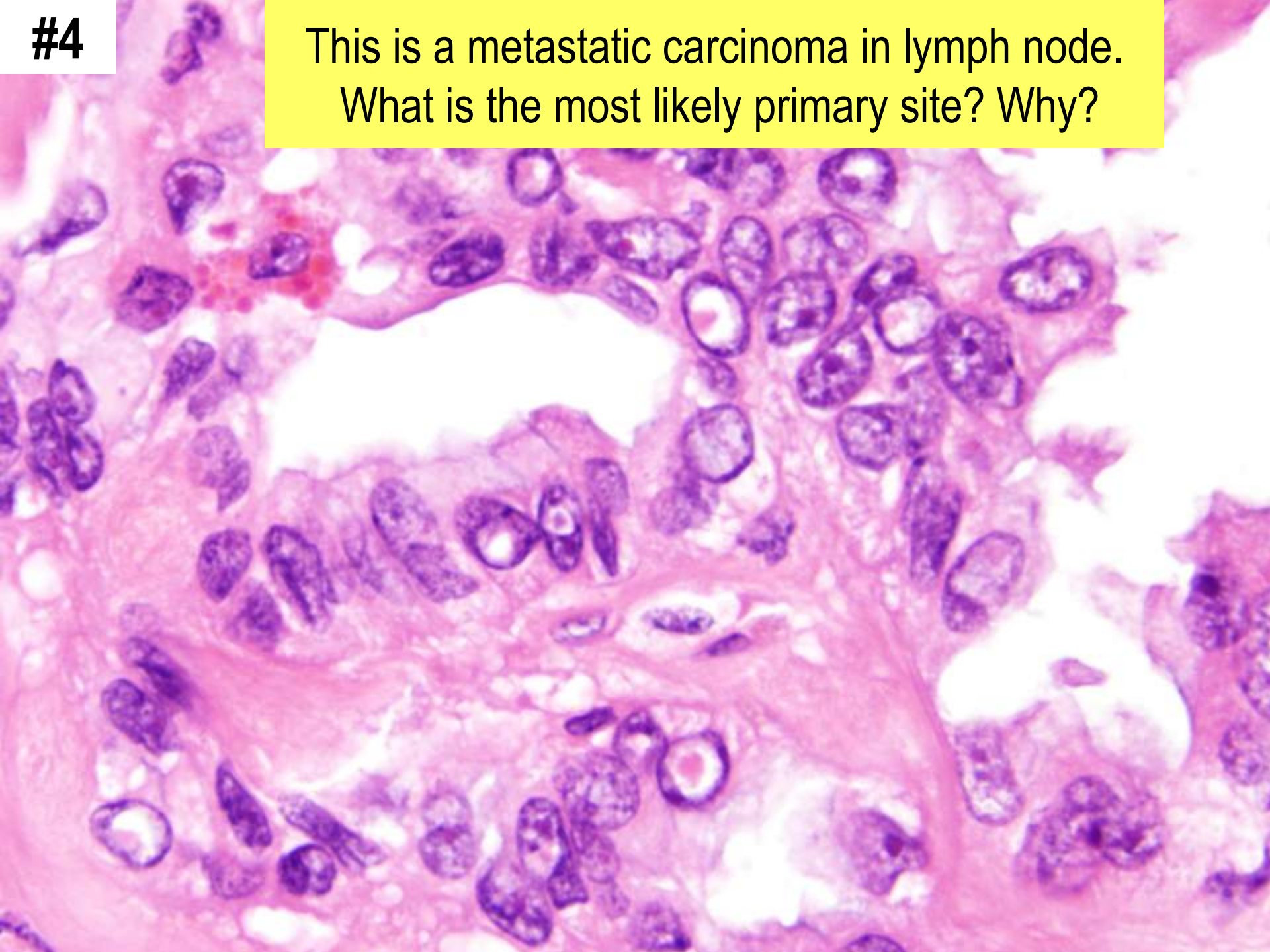
#3

This is a GIST. What is its most likely site of occurrence?



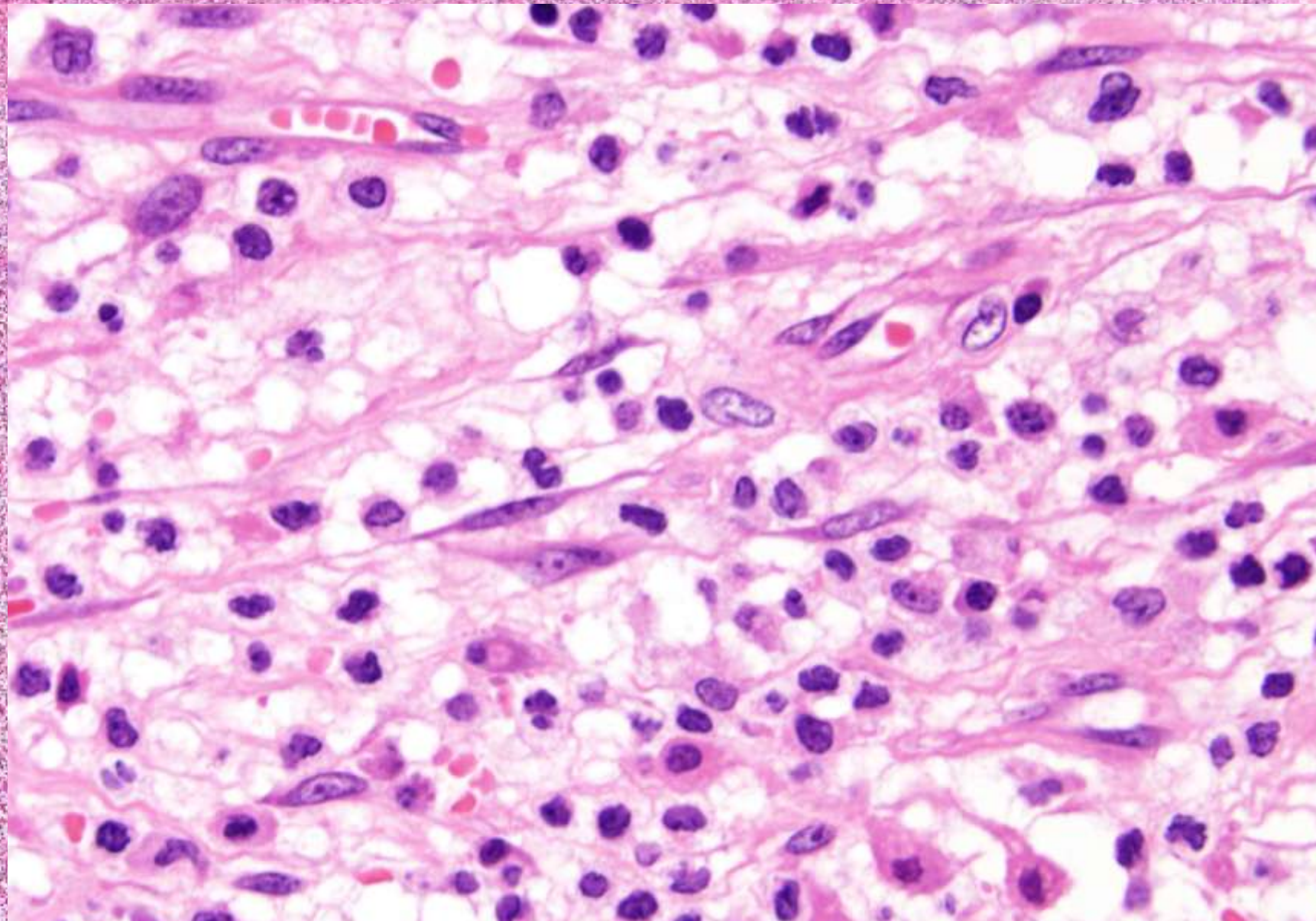
#4

This is a metastatic carcinoma in lymph node.
What is the most likely primary site? Why?



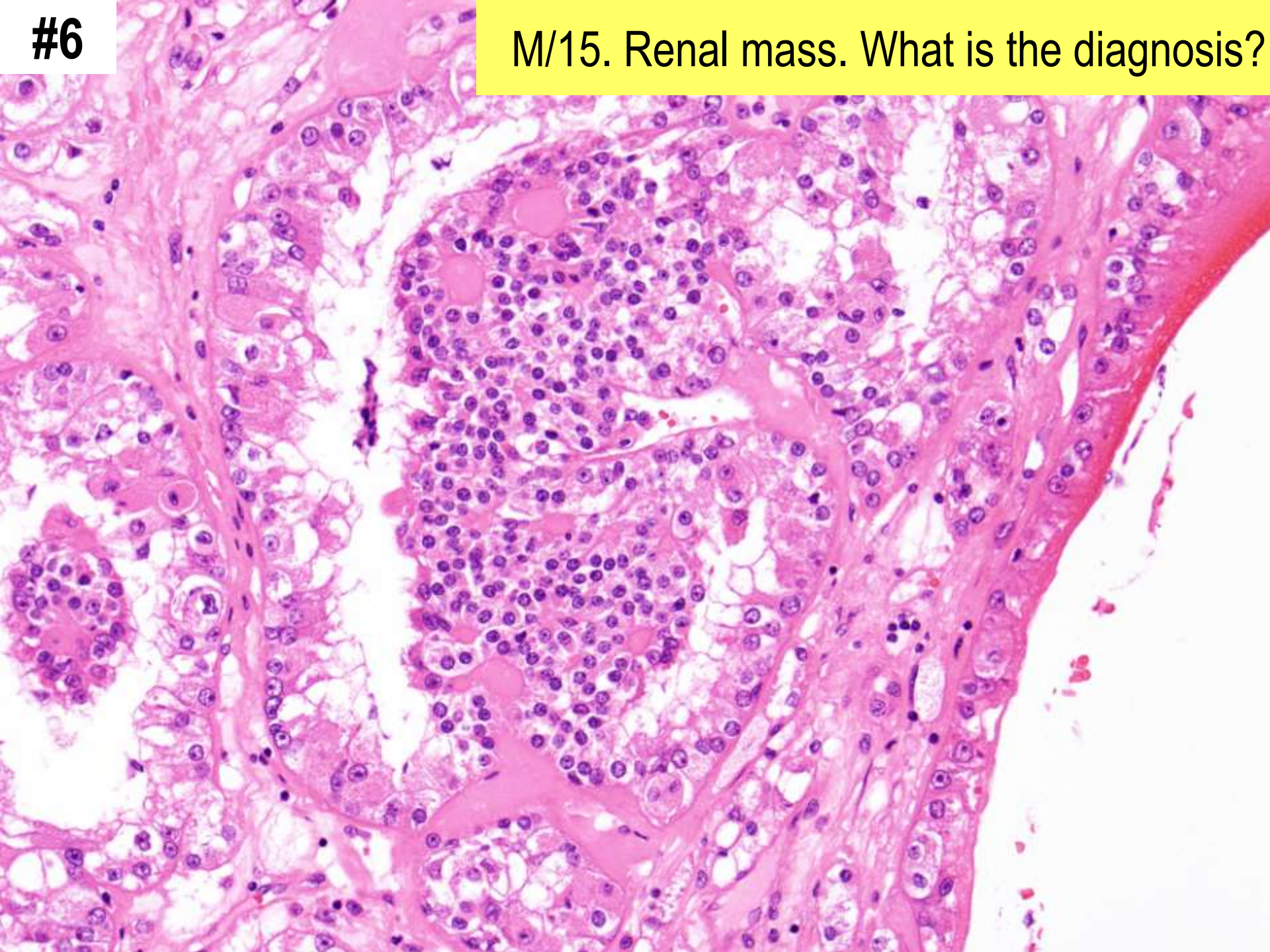
#5

F/8. Multiple cervical lymph nodes. Most likely diagnosis?



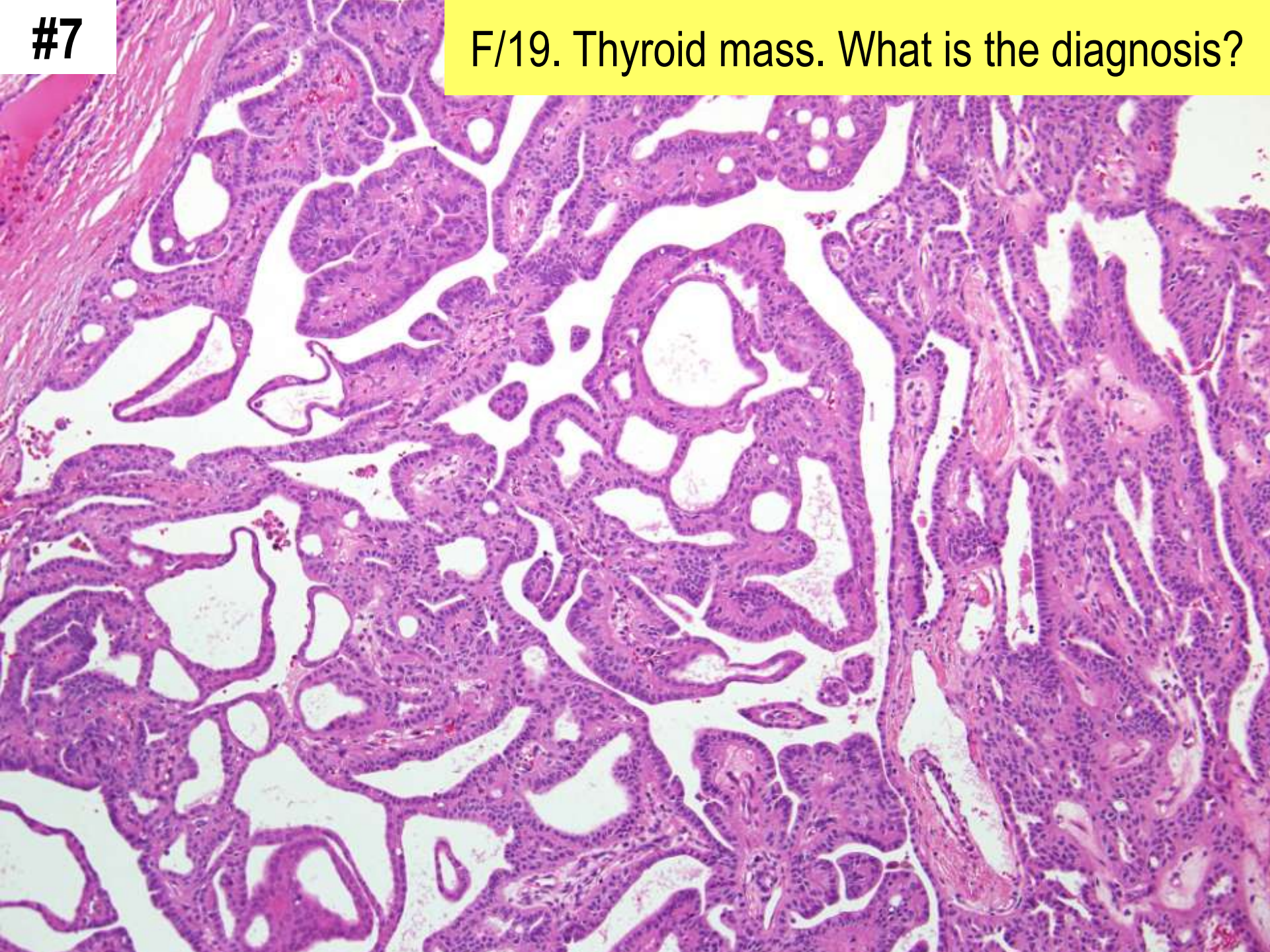
#6

M/15. Renal mass. What is the diagnosis?



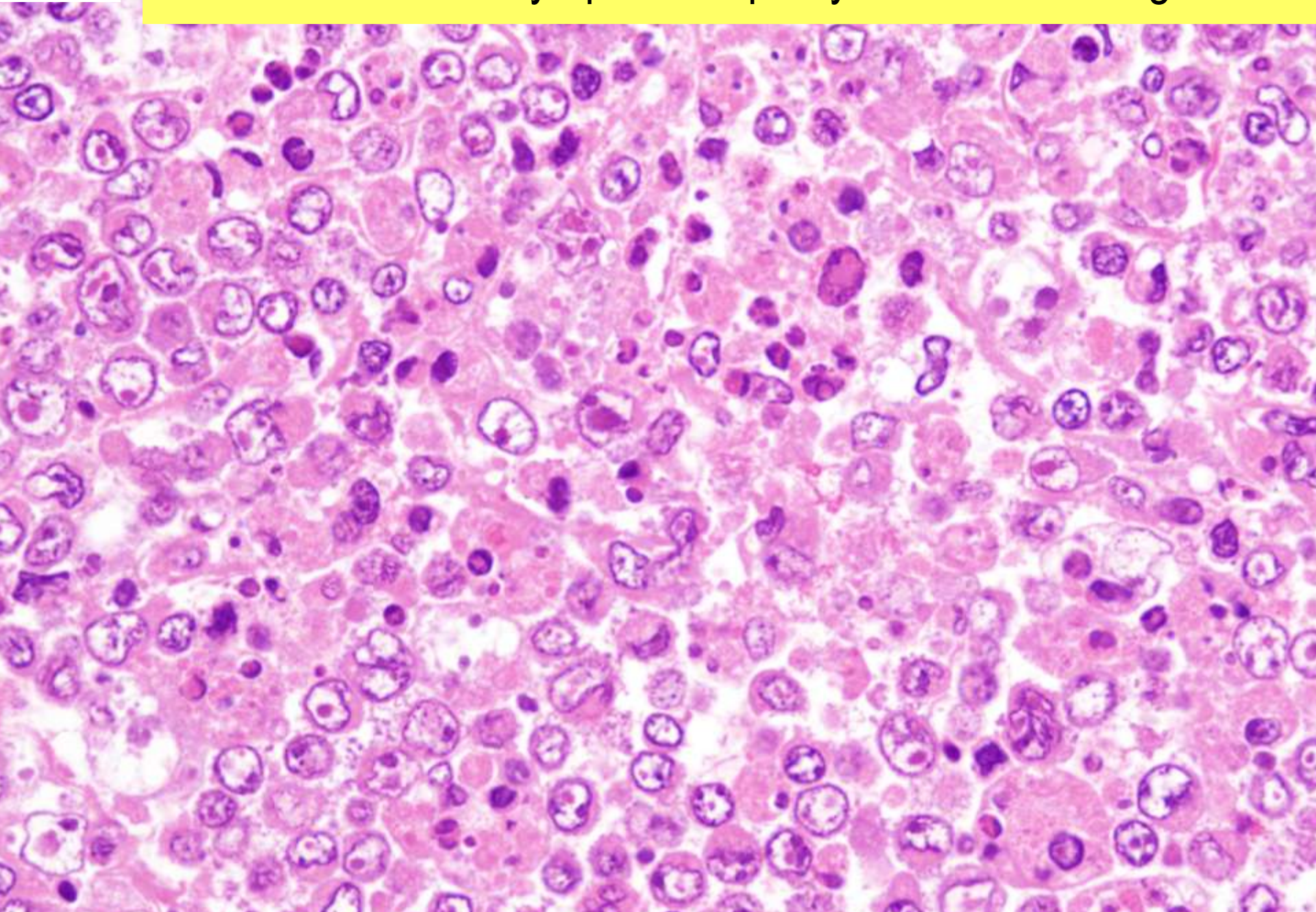
#7

F/19. Thyroid mass. What is the diagnosis?



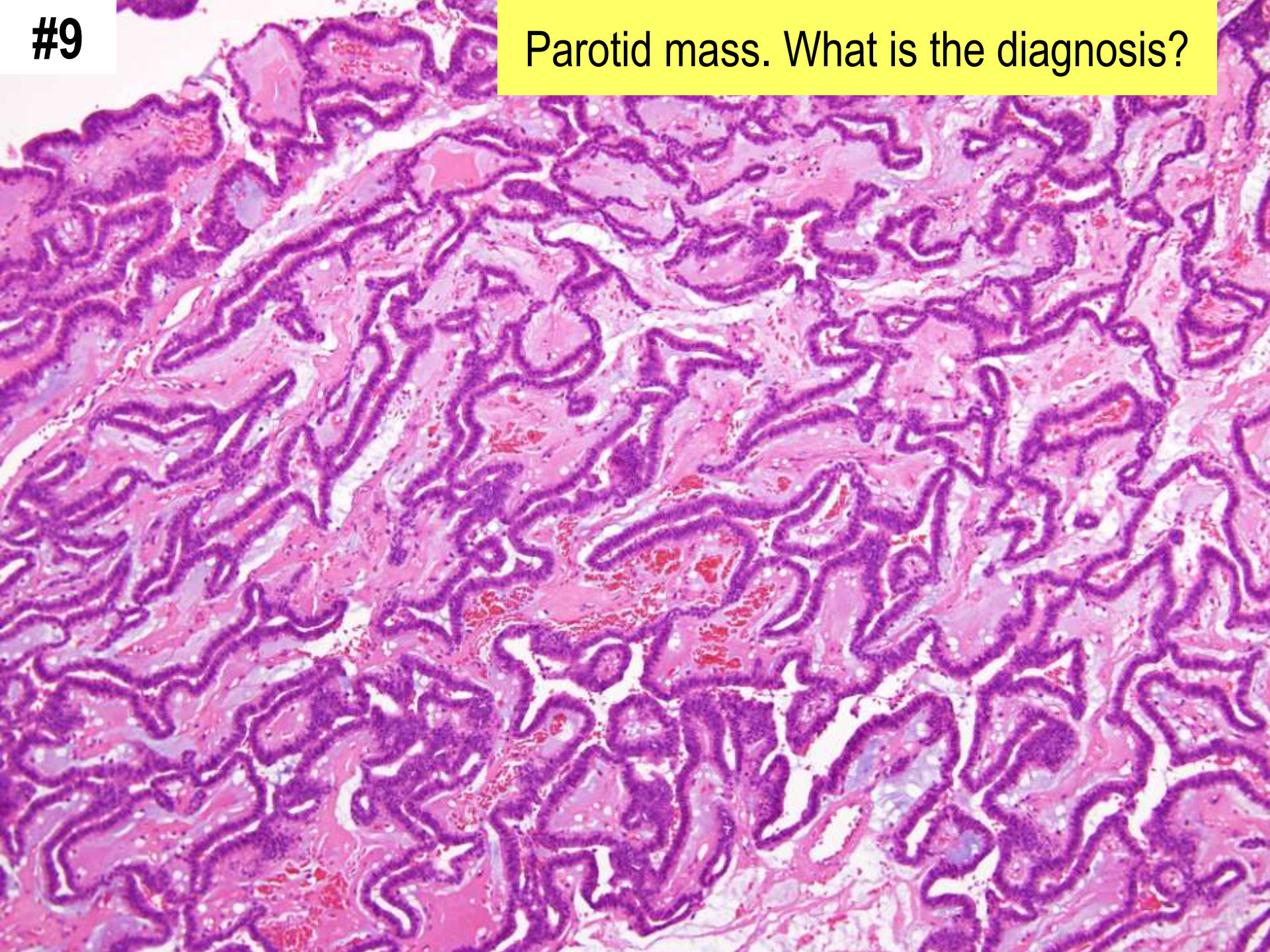
#8

M/57. Generalized lymphadenopathy. What is the diagnosis?



#9

Parotid mass. What is the diagnosis?



#10

M/27. Mediastinal mass. What is the diagnosis?

